

Approach to Right Side Central Vein Stenosis: Stent Choice 2

Division of Peripheral Vascular Intervention
China Medical University Hospital
Chung-Ho Hsu

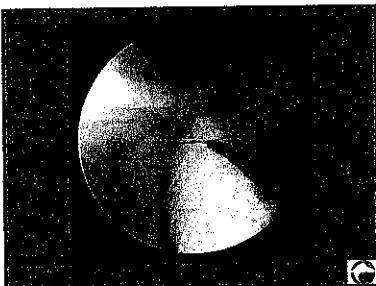
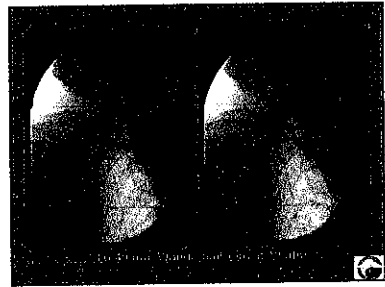
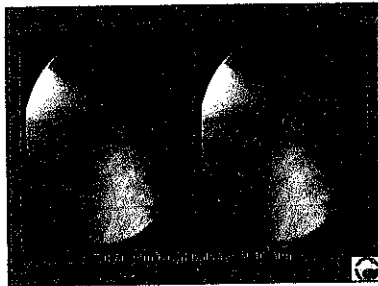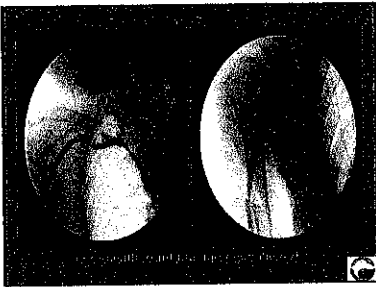
Chung-Ho Hsu

History

- 74 y/o female
- ESRD on HD tw
- Right brachio-cephalic AVF
- Repeated right arm swelling s/p several PTA (every 1-2 month) to right subclavian vein and innominate vein

Chung-Ho Hsu






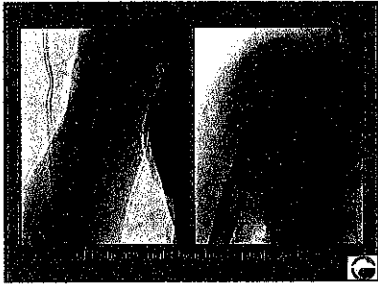
1~n PTA



But One Month Later

Chung-Ho Hsu

Final PTA



Angio 1 Y Later

