

# Computed Tomography As A Diagnostic Tool For Uterine Necrosis

中國醫藥大學附設醫院 婦產部 陳怡燕 邱燦宏 張穎宜 何銘

## Introduction

Uterine necrosis is rare because the blood supply to the uterine increased significantly during pregnancy and there are many collateral vessels such as utero-ovarian arteries. However, there are more and more cases reported with uterine necrosis after B-Lynch or arterial embolization. B-Lynch or other uterine compression suture are used for uterine atony. Arterial embolization is one of the conservative treatments for refractory postpartum hemorrhage and uterine fibroid. We reported one case with uterine necrosis presented with persistent puerperal fever and foul-odor vaginal discharge diagnosed by computed tomographic(CT) imaging.

## Case Report

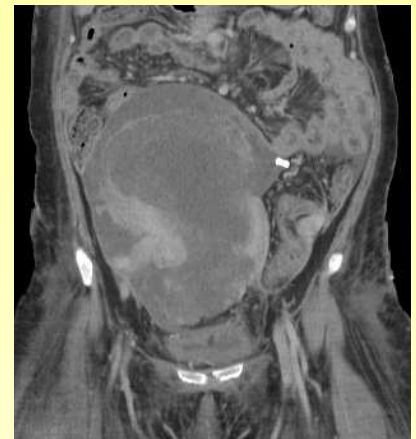A 37-year-old female, gravida 1, para 0, without known special history, pregnant with twin at the gestational age of 34 weeks, presented to our delivery room with acute fatty liver and intrauterine fetal death of both fetuses. She had hysterotomy complicated by postpartum hemorrhage due to uterine atony and coagulopathy, therefore, uterotonic agents, and modified B-Lynch were applied. Hypovolemic shock and acute renal failure also developed. After massive blood transfusion, hemodialysis, inotropic agents, and other supportive treatments, her condition got stable gradually.

She had wound dehiscence with infection and persistent foul discharge from wound and vagina. There was no postpartum uterine involution and it's around umbilicus level. Though antibiotic was administrated, she still had intermittent fever up to 38 degree. Sonography demonstrated that normal uterine contour and there was blood flow to the uterine. Abdominal CT demonstrated one huge uterus, hypodense internal content, ill-defined myometrium, and peripheral enhancement rim, suggestive of uterine necrosis. We did uterine biopsy under sonography guidance, which disclosed necrosis in three specimens and inflammatory change in one specimen. Patient and families asked for conservative treatment due to fertility desires.

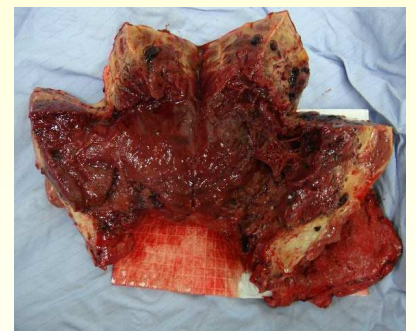
Due to failure of medical treatment with intermittent fever, she received subtotal hysterectomy 26 days after last operation. Uterine incisional wound was dehiscent and the uterine cavity was full of necrotic debris and pus with foul odor. The myometrium was ischemic and necrotic grossly. The pathology of the uterine showed diffuse necrosis and infarction of uterine tissue with patchy abscess formation, and there was little viable uterine tissue remained. After the operation and antibiotic treatment, she recovered and was discharged.

## Conclusions

Uterine necrosis is rare, mostly happened after B-Lynch or arterial embolization. In this case, uterine necrosis may result from surgical suturing techniques, hypovolemic shock, and infection. Common presentations of uterine necrosis include fever, lower abdominal pain, and leukorrhea. Hysterectomy is the treatment of choice for uterine necrosis. Sonography could be as first diagnostic tool, but it is not as sensitive as CT or MRI in our opinion. We would like to present this case with CT imaging of absence of enhancement in the myometrium and peripheral enhancement rim, and finally proved to be uterine necrosis pathologically. Patients who receive B-Lynch or arterial embolization develop fever, abdominal pain, and abnormal vaginal discharge, CT could be a useful diagnostic tool for uterine necrosis.



*Figure. 1*  
Ill-defined myometrium with peripheral enhancement rim on computed tomographic imaging



*Figure. 2*  
Necrotic uterine