

腦血管疾病學

1

個案研究:以急性全身刺痛與無力表現的雙內側延髓中風

朱海瑞 湯頌君 鄭建興

國立臺灣大學醫學院附設醫院 神經部

Bilateral medial medullary infarction presenting as acute fluctuating tingling sensation and weakness over all limbs and trunk: a case report

Hai-Jui Chu, Sung-Chun Tang, Jiann-Shing Jeng

Department of Neurology, National Taiwan University Hospital

Background Bilateral medial medullary infarction (MMI) is extremely rare among patients with acute ischemic stroke. Here we reported a case of bilateral MMI presenting as an unusual course of acute fluctuating tingling sensation and weakness in all limbs and trunk for 2 days.

Case Report A 41-year-old female had newly diagnosed hypertension but did not take regular medication for several months. The day before the symptom onset, she went to bed as usual. Around midnight, she was awakened by generalized tingling and burning sensation. It first started from tips of all fingers and soon ascended to both arms, head, neck and whole body. She also complained four limbs weakness although she could elevate her four limbs symmetrically. Head CT which was

performed one hour later was negative. Her symptoms recovered gradually after 8 hours of staying in hospital. Nevertheless, five hours after discharge, the tingling sensation and limbs weakness recurred and she was referred to our hospital for further survey. Neurological examination revealed the muscle power was 3/5 in all four limbs with bilateral extensor type of plantar response. The gag reflex was trace and tongue could not be protruded. Ten hours after arriving in our emergency room, the muscle strength deteriorated to 2/5 in upper limbs and 1/5 in lower ones. Magnetic resonance imaging revealed bilateral MMI infarction with heart shape sign. Digital subtraction angiography showed normal appearance of bilateral vertebral arteries but suspected an azygos anterior spinal artery mainly derived from the left vertebral artery. For the consequently respiratory distress, she was intubated. Heparinization was given for 2 days and was shifted to Clopidogrel 1 tablet per day. Three months later, her muscle strength improved significantly and she could walk with a quadricane well.

Conclusion Although rare, bilateral MMI needs to be considered in the differential diagnosis for patients with acute motor and sensory symptoms of all limbs and trunk plus bulbar symptoms.

腦出血病人頸動脈內膜厚度與再中風的關聯性

江宜蓁 陳怡君

林口長庚紀念醫院 神經內科

Carotid intima-media thickness and incidence of recurrent stroke in patients with first-ever spontaneous intracerebral hemorrhage (ICH)

Yi-Chen Chiang, Yi-Chun Chen

Department of Neurology, Chang Gung Memorial Hospital, Lin-Kou Medical Center

Objectives Increase in carotid intima-media thickness (IMT) and stenosis are shown to be independent predictors of primary ICH, but their association with recurrent stroke after primary ICH is less clear. This study examined the correlation of carotid ultrasonographic findings with first-ever ICH and its role in recurrence of ICH and infarction.

Methods This retrospective study included 508 patients with first-ever spontaneous ICH. Among them, 166 patients had examination of carotid color-coded duplex sonography (CCD).

Results CCD was performed more frequently in those with hypertension, higher Glasgow Coma Scale and smaller ICH size due to better prognosis. Ultrasonographic findings were further divided into 3 subtypes: carotid thickness, carotid stenosis, and significant stenosis (>50%). Carotid thickness was correlated positively with old age, hypertension, and DM, and inversely with hemorrhage

size. Carotid stenosis was associated positively with old age, hypertension, and inversely with hemorrhage size. Total cholesterol was the only independent predictor (OR 1.03 and 95% CI 1.00-1.06, P = 0.04) of significant stenosis. The follow-up time was 4.30 ± 2.61 years for first-ever ICH patients with CCD, with time to recurrent stroke 2.41 ± 2.02 years. Recurrent stroke was 15.1 %, with 12.6 % for infarction and 2.5% for ICH. Multivariable Cox proportional hazards models did not find any association of carotid thickness or stenosis with recurrent stroke. Increasing carotid IMT was associated with a hazard ratio of recurrent ICH of 0.49 (95% CI, 0.08-3.0) and a hazard ratio of recurrent infarct of 1.01 (95% CI, 0.63-1.64). Increasing carotid stenosis was associated with a hazard ratio of recurrent ICH of 0.99 (95% CI, 0.90-1.08) and a hazard ratio of recurrent infarct of 1.00 (95% CI, 0.97-1.03).

Conclusion The clinical impact of carotid IMT and stenosis on recurrent stroke in primary ICH cases remains insignificant. This conclusion can be applied for the population of patient with higher Glasgow Coma Scale and smaller ICH size.

3

探討花蓮地區緊急救護技術員之急性腦中風到院前救護行為意圖

江俊宜¹ 胡益進² 李明憲³ 陳俊安⁴ 李俊泰⁴
¹國軍花蓮總醫院內科部 ²國立台灣師範大學健康促進與衛生教育學系 ³國立東華大學課程設計與潛能開發學系 ⁴三軍總醫院神經科部

Prehospital care intention of acute stroke related factors among emergency medical technicians in the Hualien area

Chun-I Chiang¹, Yih-Jin Hu², Ming-Shinn Lee³, Chun-An Chen⁴, Jiunn-Tay Lee⁴

¹Department of Internal Medicine, Hualien Armed Force General Hospital

²Department of Health Education, National Taiwan Normal University

³Department of Curriculum Design and Human Potentials Development Graduate Institute of Compulsory Education, National Dong Hwa University, Hualien,

⁴Department of Neurology, Tri-Service General Hospital

Background Emergency medical services (EMS) transport and hospital prenotification are not been strengthened in Taiwan. The main purpose of this study is to understand the status of the knowledge, cues to action, attitudes, self-efficacy and intention and related factors of prehospital care of acute stroke among emergency medical technicians in the Hualien area.

Methods The target group for this study focused on first line technicians working in the Hualien area.

Results The research tool was based on a structured questionnaire among a total of 109 valid questionnaires.

1. The results of knowledge on acute stroke showed an upper middle level.

The results of attitudes showed tending to "agree". The results of prehospital care intention of acute stroke showed "possible to do it".

2. The relationship between knowledge, attitudes, self-efficacy, cues to action and health behavior showed positive correlations.

3. Among the background variables "experience of acute stroke care", "cues to action", "self-efficacy" on "prehospital care of acute stroke" could effectively predict health behavior. The most effective variable was "self-efficacy". However, "having advanced cardiovascular life support training" became a negative effect.

Conclusion Case-based learning for EMS stroke education may be an effective method under the positive variables "experience of acute stroke care", "cues to action", and "self-efficacy".

4

經動脈血管栓塞術改善顱內動靜脈瘻管引起之癲癇重積症

江星遠¹ 劉濟弘¹ 廖沼鋒¹ 林秀娜¹ 黃浩輝²
林口長庚紀念醫院¹神經內科²放射診斷科

Transarterial Embolization Improves Refractory Status Epilepticus in a Patient with Intracranial Dural Arteriovenous Fistula

Hsing-I Chiang¹, Chi-Hung Liu¹, Ming-Feng Liao¹, Siew-Na Lim¹, Ho-Fai Wong²

¹Department of Neurology and ²Department of Medical Imaging and Intervention, Chang Gung Memorial Hospital, Linkou Medical Center

Background Status epilepticus (SE)

is an infrequent manifestation of intracranial dural arteriovenous fistula (DAVF). Endovascular treatment is an option when aggressive symptoms develop. We report our experience using endovascular embolization in the treatment of DAVF with SE refractory to medications.

Case Report An 82-year-old woman was admitted due to SE with seizure focus at left temporal area. Brain magnetic resonance imaging (MRI) showed venous hypertension and vasogenic edema at left occipital and temporal lobes. Digital subtraction angiography confirmed Cognard type II a + b DAVF at left lateral sinus supplied by middle meningeal artery with reflux into left posterior cortical veins and left transverse sinus stenosis. Midazolam continuous infusion (0.21mg/kg/hr) and oral antiepileptic drugs (AED) including levetiracetam (3000 mg/day), oxcarbazepine (1200 mg/day), topiramate (400 mg/day), and valproic acid (1600 mg/day) failed to control the SE but led to unstable vital signs. We arranged transarterial embolization (TAE) with Onyx through middle meningeal artery and the feeding artery was obliterated. The SE subsided and the electroencephalogram showed burst suppression after TAE. Follow-up MRI showed improvement of vasogenic edema. Meanwhile, we successfully discontinued midazolam infusion and tapered the total doses of AED.

Conclusion The treatments of this patient suggest the TAE with Onyx may effectively alleviate the refractory SE by means of improvement of vasogenic edema and venous hypertension.

5

平板電腦與智慧型手機於急性缺血性腦中風處置之臨床運用

何旭華

虎尾天主教若瑟醫院 神經內科

The Applications of Tablet Computer and Smart Phone in Acute Ischemic Stroke

Hsu-Hua Ho

Department of Neurology, Saint Joseph's Hospital

背景 以往，我們對於急性缺血性中風期的處置治療，大多是書面記錄於紙本上，再輸入於電腦，進行後置的人工作業。這種處置與記錄的過程，不僅延長了急性處置的時效，並且增加了後續統計與分析工作的複雜性。隨著智慧型手機與平板電腦的普及化和軟體程式的革新和進步。我們藉此發展急性缺血性中風處置流程的關鍵軟體程式，自動將所得檢驗數據進行符合條件比對、透過數位化記錄各項臨床神經學檢查量表、計算所需施打藥物劑量、同時也追蹤和立即反映出處置進行的時間與流程準確性。

方法 我們使用 Android 手機作業系統，它是一個以 Linux 為基礎的半開放原始碼作業系統，由於它支援多工與多重語言，並且內置 SQLite 小型關聯式資料庫管理系統來負責存儲數據；同時也支援所有的雲端和無線

網路服務器訊息；因此非常適合用來開發小型的醫療影像與數據的儲傳資料庫。所使用開發應用程式的編程語言為 JAVA 和 XML。藉由無線網路系統，將病人基本資料與各項檢驗數據由系統帶入，並進行是否符合條件之判斷。各項臨床評估量表(NIHSS、巴氏量表、和雷氏量表)都予以數位和資料庫化。量表施測的同時，系統也啟動計時功能，計算出檢查所花費的時間。施測的結束，電腦根據預先設定的流程公式，快速的計算出總分數，多次評估後作縱橫向的參考和比對。並根據病人體重與單位注射劑量，顯示 r-tPA 治療的總量與分次施打的劑量。每一筆記錄皆顯明記錄時間，所耗時間，是否符合步驟程序，以及運算結果，藉由無線網路系統，自動輸入關聯性資料庫中。

結果 由於檢查醫師，可將神經學評估各項分數，經由點選智慧型手機、存入和演算在資料庫中。並藉由電腦與網路資料庫系統的輔助，大大的節省了各項報告收集與數據填寫所需花費的時間。電腦自動進行符合條件比對、監控篩選步驟、計算藥物使用劑量、和避免人為疏乎，讓醫師能夠進行準確的判讀。根據臨床的實際操作，這一電腦的輔助應用，較傳統的紙筆記錄約略節省五到八分鐘的時間。

結論 總而言之，訓練有素的專業團隊，良好的部門默契與合作協調，醫病關係的互信溝通，再加上新的電腦科技與網路資料庫應用，將提供給病患更好的醫療品質，把握住急性腦中風黃金治療的時機。同時對於日後資料的查詢、統計和分析也提供詳實記錄的參考。

6

鑑別診斷洗腎病人之人工血管造成之鎖骨下動脈竊血症候群

吳令治

財團法人台灣基督教門諾會醫院 神經內科

Can we use carotid duplex to differentiate subclavian steal caused by vascular access for hemodialysis from by subclavian stenosis?

Ling Chih Wu

Neurologic department Mennonite Christian hospital

Purpose Subclavian steal phenomenon can be caused by stenosis of subclavian artery or by the high and low-resistant flow of vascular access for patients under hemodialysis. We described a simple method to differentiate the different causes by duplex. We want to see if there is any difference between these two conditions in carotid duplex.

Method We performed a prospective study and collected patients from December 2010 to July 2011 with informed consent for all patients with vascular access. We have 5 patients with subclavian steal without vascular access in this period of time and, according to patient's will to participate in this study, 11 patients with vascular access in the forearm. 9 patients with vascular access were excluded from our study for there is no subclavian steal in the ipsilateral side of vascular access. For every patient, we compressed the arm to stop the flow by cuff (we only studied patients whose vascular access was located in

the forearm to avoid direct compression of the vascular access) during duplex examination and studied the flow pattern of subclavian and vertebral artery before and during the cuff test

Result No significant changes of flow pattern for either vertebral or subclavian artery during the cuff test for all 5 patients without vascular access. On the contrary, flow for both subclavian and vertebral artery change to nearly normal pattern when the blood flow is blocked in the arm of these 2 patients with subclavian steal and with vascular access.

Discussion From this study, it seemed that duplex findings of subclavian steal are different between patients without and with vascular access. We can use this simple method to differentiate the different causes of subclavian steal especially for patients with end-stage renal disease who often have atherosclerosis and are vulnerable to contrast used in angiography

7

血栓溶解治療避免前脈絡叢動脈梗塞之中風惡化並增進長期預後

吳孟真¹ 蔡力凱^{1,2} 葉馨喬^{1,2} 湯頌君¹ 鄭建興¹
¹台大醫院神經部暨腦中風中心
²台大醫院雲林分院神經部

Thrombolytic Therapy Prevents Stroke Evolution and Improves Long-term Outcome in Large Anterior Choroidal Artery Infarct

Meng-Chen Wu, MD,¹ Li-Kai Tsai, MD, PhD,^{1,2} Sing-Joe Yeh, MD,^{1,2} Sung-Chun Tang, MD,¹ Jiann-Shing Jeng¹

¹ Department of Neurology and Stroke Center, NTUH; ² Department of Neurology, NTUH, Yun-Lin branch

Objective To investigate the determinants of stroke evolution and roles of thrombolytic therapy in large anterior choroidal artery (AChA) infarct.

Background Large AChA infarct is highly associated with stroke evolution; however, the risk and preventing factors for stroke evolution are still unclear. In addition, although the benefits of thrombolytic therapy are well known in acute ischemic stroke, the effects of thrombolytic therapy in AChA infarct are rarely reported.

Methods From January 2009 through July 2012, we studied 118 consecutive adult patients with acute large AChA infarct in National Taiwan University Hospital (NTUH) and NTUH, Yun-Lin branch. The diagnosis of large AChA infarct was confirmed as abnormal hyperintensity in at least three MRI slices (thickness, 5 mm) at DWI within typical AChA vascular regions. The definition of stroke evolution was neurological deterioration with increase of NIHSS by or more than two in 7 days after onset of stroke.

Results In 118 patients with large AChA infarct, 50 cases (42.4%) developed stroke evolution with an increase of NIHSS by 3.7 ± 2.1 . Among

various demographical, clinical, and neuroimaging factors, only thrombolytic therapy was reversely associated with stroke evolution ($P = 0.02$). Using multivariate analysis, thrombolytic therapy was still a protective determinant for stroke evolution (odds ratio, 0.19; 95% confident interval, 0.04 to 0.99). Additionally, thrombolytic therapy was significantly associated with lower mRS at 3 months after onset of stroke ($P = 0.04$), despite of higher initial NIHSS (<0.001). Earlier treatment ($P = 0.009$) and higher dosage ($P = 0.02$) of thrombolytic therapy were related to greater improvement. The independent determinants for functional outcome included age (odds ratio, 1.08; 95% confident interval, 1.04 to 1.13), initial NIHSS (1.79; 1.37 to 2.34), occurrence of stroke evolution (4.32; 1.59 to 11.69), and thrombolytic therapy (0.15; 0.03 to 0.94).

Conclusion Two-fifth of patients with large AChA infarct got stroke evolution. Thrombolytic therapy not only prevented stroke evolution, but independently improved long-term outcome in large AChA infarct

8

下視丘缺血性中風引起嚴重記憶缺失及食慾不振

吳雅純 徐榮隆
新光吳火獅紀念醫院 神經內科

Hypothalamus ischemic infarction responsible for the severe memory impairment and poor appetite

Ya-Chun Wu, Jung Lung Hsu
Department of neurology, Shin Kong Wu
Ho-Su Memorial Hospital

Background Stroke of the hypothalamus are vanishingly rare, as the hypothalamus has the most luxuriant blood supply in the brain, befitting a site that is absolutely critical to maintain life.

Case report A 64-year-old man with underlying hypertension, Type 2 DM and coronary artery disease had received CABG (coronary artery bypass graft) surgery on 2012/9/28. An acute ischemic stroke was noted right after the operation. Brain MRI on 10/2 showed acute infarction on the left basal ganglion, left mesial temporal lobe and left hypothalamus. Brain MRI also incidentally found a pituitary macroadenoma. While the patient's muscle power got totally recovered afterwards, cognitive problem remained. The patient had got very poor memory, and he failed on the registration of the 3 objects test. Besides, he also had verbal communication problem. The language symptom included agraphia, alexia and anomia. He is also noted with significant poor appetite after the stroke, and he persistently has very little intake. The patient received pituitary tumor excision on 11/9.

Conclusion The patient's significant poor appetite should be due to the

lateral hypothalamic area infarction, and his severe memory impairment could be explained by the involvement of the columns of fornix.

9

超過三小時之靜脈栓溶治療

宋昇峯¹ 陳志弘² 林慧娟³ 陳右緯⁴ 曾美君⁵
¹戴德森醫療財團法人嘉義基督教醫院 內科部
神經內科

²國立成功大學附設醫院 神經部

³奇美醫院 神經內科

⁴壠新醫院 ⁵院長室特聘研究員

Intravenous Thrombolysis Beyond the 3-Hour Time Window

¹Sheng-Feng Sung, ²Chih-Hung Chen, ³Huey-Juan Lin,
⁴Yu-Wei Chen, ⁵Mei-Chiun Tseng

¹Division of Neurology, Department of Internal
Medicine, Ditmanson Medical Foundation Chia-Yi
Christian Hospital

²Department of Neurology, National Cheng Kung
University Hospital

³Department of Neurology, Chi-Mei Medical Center

⁴Department of Neurology, Landseed Hospital

⁵Senior Researcher, Landseed Hospital

Background The recommended treatment time window of intravenous tissue plasminogen activator (tPA) has been expanded to 4.5 hours according to various guidelines. Because of off-label use, there is limited experience in thrombolysing stroke patients between 3-4.5 hours in Taiwan. We retrospectively assessed the safety and short-term efficacy of intravenous thrombolysis in this time window.

Methods We analyzed the prospectively collected data in the stroke registries of 4 stroke centers (National Cheng Kung University Hospital, Chi-Mei Medical Center, Chia-Yi Christian Hospital, and Landseed

Hospital). All consecutive stroke patients treated with intravenous tPA within 4.5 hours of symptom onset were classified into two groups - treated before 3 h of onset (group A) and treated between 3 and 4.5 h of onset (group B).

Results Between January 2007 and June 2012, a total of 624 patients (group A: 548, group B: 76) were included in this study. The demographic and stroke risk factors were similar between the two groups. The baseline National Institutes of Health Stroke Scale (NIHSS) scores were comparable (group A: median 13, interquartile range 8-20, group B: median 13 interquartile range 7-17, $P=0.359$). The median onset-to-treatment time was 125 minutes for group A and 197 minutes for group B. There were no differences between the two groups regarding the rates of any intracerebral hemorrhage (group A: 23%, group B: 20%, $P=0.503$) and symptomatic hemorrhage (group A: 7%, group B: 4%, $P=0.280$). The chances of marked improvement at discharge (defined as a reduction of ≥ 10 in the total NIHSS score or a total NIHSS score of 0 or 1) were 35% in group A and 34% in group B.

Conclusion Our study implicates that patients with acute ischemic stroke may be successfully treated with

intravenous thrombolysis shortly after the 3-hour treatment window. Patients who arrive near the end of the 3-hour window but bear a chance to be treated before 4.5 hours of onset probably should not be excluded from treatment.

10

以顱內支架置放治療進行性顱內血管剝離 - 亞東醫院之經驗

李少白¹ 賴彥君² 邱奕華¹ 唐志威¹ 鄭又禎¹
黃俐文¹ 郭冠宏² 朱耀棠¹
亞東紀念醫院¹ 神經科² 影像醫學科

Stenting in Symptomatic and Progressive Intracranial Dissections: Experience at Far Eastern Memorial Hospital

Siu-Pak Lee¹, Yen-Jun Lai², Yih-Hwa Chiou¹,
Chih-Wei Tang¹, Yu-Chen Cheng¹, Lin-Wen Huang¹,
Kuei-Hong Kuo², Yiu-Tong Chu¹
¹Division of Neurology, ²Division of Medical Imaging, Far Eastern Memorial Hospital

Objective To evaluate endovascular treatment with stent deployment in patients with intracranial arterial dissections

Method Retrospective review of data at Far Eastern Memorial Hospital between 2009 and 2011 of four patients (two men, two women; mean age: 45 years) with intracranial arterial dissections treated with stent placement were identified

Result All patients were symptomatic and had clinical deterioration shortly after admission and that prompted aggressive angiographic examinations. Diagnosis was made based on cerebral angiographic findings including intimal flap (n=3) and “string and bead sign”

(n=1). Spontaneous intracranial dissections involved the right paraclinoid internal carotid artery (n=1), left middle cerebral artery (n=2) and right middle cerebral artery (n=1). Dissections were treated with balloon-expandable stent in one patient and self-expandable Neuroform stents in three patients. Mean dissection stenosis was 82% before the intervention and 18% after stent placement. There were no procedure-related complications. The range of follow-up time was from 3 months to 29 months. All patients reported clinically improvement without recurrent stroke.

Conclusion Stent placement seems to be safe and technically effective in the endovascular management of intracranial dissections, with favorable clinical outcomes.

11

顱內硬腦膜動靜脈瘻管併發可逆性非血栓性上矢狀竇阻塞及重積性癲癇

李君右 湯頌君 鄭建興
國立台灣大學醫學院附設醫院 神經內科

Intracranial Dural Arteriovenous Fistula Complicating Reversible Non-thrombotic Occlusion of the Superior Sagittal sinus and status epilepticus

Chun-Yu Lee, Sung-Chun Tang, Jiann-Shing Jeng
Department of Neurology, National Taiwan University Hospital

Background Seizure is an uncommon

presentation of dural arteriovenous fistula (dAVF) and usually associated with the existence of cerebral venous sinus thrombosis.

Here we reported a rare case of intracranial dAVF who had status epilepticus resulting from acute reversible non-thrombotic occlusion of the superior sagittal sinus (SSS).

Case Report A 49-year-old man with past history of diabetes mellitus was found lying at home with generalized tonic clonic seizure (GTCS) by family. He was sent to a local community hospital while the convulsion sustained.

Intravenous phenytoin was given but in vain. Under the impression of status epilepticus, continuous infusion of midazolam was started for seizure control. CT angiography showed SSS occlusion with venous hypertension, causing multiple small intracerebral hemorrhage and brain edema. He was transferred to our hospital for further management. Digital subtraction angiography was performed, which revealed dAVF draining into SSS and non-visualization of the posterior part of SSS. However, no thrombus was detected in the sinus during the examination.

External compression of the dural sinus lumen by abnormal vessels within the sinus walls was suspected. Balloon dilatation and angioplasty to SSS were performed and then patency of SSS was restored. Midazolam was tapered gradually after the procedure and the

patient regained clear consciousness. Trans-arterial embolization (TAE) of dAVF was performed smoothly five days after angioplasty. GTCS recurred once shortly after TAE but it resolved soon after titrating up midazolam dosage. Continuous right shoulder twitching with preserved consciousness was noted while tapering midazolam again. Status partialis continua was impressed and midazolam was titrated up again. After adjusting anti-epileptic drugs, no more seizures developed thereafter and the patient recovered well.

Conclusion Our study demonstrated that intracranial dAVF may cause non-thrombotic occlusion of the affected sinus and induce status epilepticus. The diagnosis of dAVF needs to be considered in patients with status epilepticus, even without cerebral venous sinus thrombosis.

12

硬膜外移植人類誘導性多能幹細胞分化的神經先驅細胞促進中風成鼠的功能恢復

李怡慧^{1,2}, 黃相碩³, 莊靜玉⁴, 蘇育世², 廖可薰¹, 莊嘉琪¹, 林宏叡⁵, 謝睿瑜⁵, 蘇琺涵⁵, 李光申^{6,7}, 郭紘志⁴, 王學偉^{5,6,8}

¹台北榮民總醫院神經內科, ²陽明大學腦科學研究所, ³中山醫學大學藥理研究所, ⁴中央研究院基因體研究中心, ⁵陽明大學微生物研究所, ⁶陽明大學臨床醫學研究所, ⁷台北榮民總醫院骨科部, ⁸榮陽基因體研究中心

Epidural grafts of human iPS cell-derived neural progenitors improve post-stroke recovery via a unique secretome

I-Hui Lee^{1,2}, Shiang-Suo Huang³, Ching-Yu Chuang⁴, Yu-Shih Su², Ko-Hsun Liao¹, Chai-Chi Chuang¹, Hung-Jui Lin⁵, Jui-Yu Hsieh⁵, Shu-Han Su⁵, Oscar Kuang-Sheng Lee^{6,7}, Hung-Chih Kuo⁴, Hsei-Wei Wang^{5,6,8}

¹Department of Neurology, Neurological Institute, Taipei Veterans General Hospital, Taiwan

²Institute of Brain Science, National Yang-Ming University, Taipei, Taiwan

³Department of Pharmacology and Institute of Medicine, Chung-Shan Medical University, Taichung, Taiwan

⁴Stem Cell Program, Institute of Cellular and Organismic Biology and Genomics Research Center, Academia Sinica, Taipei, Taiwan;

⁵Institute of Microbiology and Immunology, National Yang-Ming University, Taipei, Taiwan

⁶Institute of Clinical Medicine, National Yang-Ming University, Taipei, Taiwan

⁷Department of Orthopedics and Traumatology, Taipei Veterans General Hospital, Taiwan

⁸VGH-YM Genome and Cancer Research Centers, National Yang-Ming University, Taipei, Taiwan.

Objective and background Neural progenitor cells derived from induced pluripotent stem cells (iPSC-NPCs) show promise for tailor-made cell therapy in experimental stroke; however, their translational implantation is hampered by propensity of tumorigenesis. Little is known about their secretory mechanisms following transplantation. We investigated the secretome of human iPSC-NPCs and their extraparenchymal implantation via an epidural fibrin matrix in adult stroke rats.

Methods A transmembranous co-culture system with rat cortical cells subjected to oxygen-glucose deprivation (OGD) was used to characterize the iPSC-NPC secretome in comparison with human mesenchymal stem cells utilizing a systems biology approach including cytokine arrays and whole-genome

microarrays. Moreover, iPSC-NPCs or vehicle were delivered via epidural fibrin matrix over the infarct cortex 1 week following permanent middle cerebral artery occlusion (MCAO) to compare behavioral and histological changes.

Results Over 80% Pax6+/Sox1+ iPSC-NPCs were obtained after differentiation and mechanical enrichment. In the transmembranous co-cultures, the iPSC-NPCs, in contrast to mesenchymal stem cells from bone marrow and umbilical cord Wharton's jelly, enhanced neuronal growth and mitigated astrogliosis via a unique secretome. The iPSC-NPC-transplanted rats showed significant improvement in their paretic forelimb usage and grip strength from 10 days post-transplantation (dpt) onwards compared with the vehicle-transplanted rats. iPSC-NPCs homed into the peri-infarct cortex through the leaky blood brain barrier within 1 dpt, but poorly survived without formation of a teratoma at 21 dpt. The cell-treated rats had significantly reduced infarct/atrophy volumes, ameliorated inflammatory infiltration, astrogliosis, and apoptosis, as well as augmented angiogenesis, oligodendrocyte progenitors, and white matter tract integrity.

Conclusions These results suggest that the epidural biopolymer-delivered

iPSC-NPCs may not only reduce tumorigenic risk but also promote peri-infarct cellular survival and functional regeneration primarily through bystander effects.

13

缺鐵性貧血相關之年輕男性缺血性中風

李俊賢^{1,2,3} 李君右¹, 鄭文誠⁴

¹台大醫院 神經部, ²國家衛生研究院 環境衛生與職業醫學組, ³台大醫院 環境暨職業醫學部, ⁴台大醫學院檢驗醫學科, 台大醫院檢驗醫學部

Iron deficiency anemia as a rare cause of ischemic stroke in a young man: a case report

Lukas Jyuhn-Hsiarn Lee^{1,2,3}, Chung-Yo Lee¹, Wern-Cherng Cheng⁴

¹Department of Neurology, National Taiwan University Hospital

²Division of Environmental Health and Occupational Medicine, National Health Research Institutes

³Department of Environmental and Occupational Medicine, National Taiwan University Hospital

⁴Laboratory Medicine, College of Medicine, National Taiwan University and Department of Laboratory Medicine, National Taiwan University Hospital

Background The cause of young stroke remains underdetermined in about 30% of cases. Iron deficiency is a rare cause of pediatric stroke, mainly due to central venous thrombosis, and some associated with thrombocytosis. Prevention of acute stroke among young people needs identification of such modifiable risk factors.

Case Report A 37-year-old man, a driver of tourist bus, who overworked for more than 16 hours per day, presented to the emergency department with

complaints of acute onset of weakness and numbness in his right limbs during his work. Right central type facial palsy, mild dysarthria, and right hemiparesis were observed. Head CT showed no evidence of hemorrhage.

Under the impression of acute ischemic stroke with an NIH stroke scale of 9 scored by a neurologist, he received treatment with tissue plasminogen activator (tPA) 0.8 mg/Kg, and was admitted to the stroke unit. Brain MRI revealed a small area of diffusion restriction at left periventricular white matter, which indicates acute infarct. He had significant neurological improvement, with NIHSS of 2 as he was discharged at day 6 after the stroke.

His past medical history was remarkable for anemia without any treatment. The hemogram revealed microcytic anemia (RBC 5.57 M/ μ L, Hb 11.3 g/dL, hematocrit 37.2%, MCV 66.8 fL, MCH 20.3 pg/cell), and iron profile showed iron of 20 μ g/dL, TIBC of 373 μ g/dL, and serum ferritin level was 3.76 μ g/L, which was compatible with iron deficiency anemia and thalassemia trait. The coagulation profiles and autoimmune surveys were within normal limits. Neurosonography of carotid arteries were normal; the transcranial cerebral duplex revealed high flow resistance index at the left middle cerebral artery, which suggested left MCA distal M1 stenosis. Tracing his occupational history, he has

been a driver for 10 years, with habits of tobacco smoking 1 pack per day for 15 years, and betel nut chewing 3 packs per day for 10 years.

Conclusion Iron deficiency is a rare cause of young stroke. Chronic exposure to betel nuts and tobacco are traditional risk factors that increase the risk of cerebral arterial atherosclerosis through oxidative stress. High calcium oral intake from a great amount of betel nuts consumption may interfere iron absorption in the gastrointestinal tract. Low oxygen delivery and possibly reactive thrombosis secondary to iron deficiency anemia may trigger the premature onset of acute ischemic stroke. Iron supplement therapy with adequate nutrition, and quitting tobacco and betel nuts are helpful for secondary stroke prevention.

14

銜接靜脈與動脈血栓溶解治療：社區醫院與醫學中心的合作經驗

李政翰¹ 胡孟綺² 謝鎮陽^{2,3} 陳志弘⁴

¹成大醫院心臟內科 ²台南新樓醫院腦中風中心暨神經內科 ³國立成功大學臨床藥學與藥物科技研究所 ⁴成大醫院腦中風中心暨神經部

Bridging Intravenous-intra-arterial Thrombolytic Therapy: Experience of Cooperation between Community Hospital and Medical Center

Cheng-Han Lee¹, Monica Hu², Cheng-Yang Hsieh^{2,3}, Chih-Hung Chen⁴

¹ Division of Cardiology, Department of Internal Medicine, National Cheng Kung University Hospital, Tainan, Taiwan

² Stroke Center and Department of Neurology, Tainan Sin Lau Hospital

³ Institute of Clinical Pharmacy and Pharmaceutical Sciences, National Cheng Kung University

⁴ Stroke Center and Department of Neurology, National Cheng Kung University Hospital

Objective To report two cases who received bridging

intravenous-intra-arterial thrombolytic therapy.

Background Although intravenous (IV) recombinant tissue plasminogen activator (rtPA) had proven efficacy for patients with acute ischemic stroke (AIS), treatment failure may be observed in patients with large vessels occlusions. Additional aggressive therapeutic approaches like bridging intravenous-intra-arterial thrombolytic therapy after IV tPA may be suitable for such patients.

Results Case 1 was a 45-year-old hypertensive man who presented with left hemiplegia for 80 minutes. The initial National Institute of Health Stroke Scale (NIHSS) was 15 and the patient received IV rtPA at 177 minutes after onset. Due to deterioration of NIHSS to 18, he was transferred to a medical center 2.2 km near-by and received intra-arterial thrombolytic therapy for an occlusion of proximal right middle cerebral artery. The NIHSS was 1 at discharge 8 days later and the modified Rankin scale at 3 months was 0. Case 2 was a 63-year-old man with hypertension, diabetes, and old stroke, though his baseline activity was independent. He presented to our ER due to right hemiplegia for 90 minutes. The initial NIHSS was 14 and the clinical diagnosis was basilar artery occlusion. He received IV tPA at 173 minutes

after onset but still deteriorated and was intubated due to poor respiratory pattern. We had recanalized his occluded basilar artery successfully at 420 minutes after onset, but he remained comatous after that and expired 4 days later.

Conclusion Our experience of bridging intravenous-intra-arterial therapy was limited and the outcome of treatment was diverse. However, such multimodal therapeutic approaches should still give benefit for carefully selected AIS patients.

15

腦血管事件於一新診斷之胰臟癌患者

周志和¹ 陳瑋芬²

¹ 奇美醫院神經內科 ² 台南新樓醫院神經內科

Fatal cerebrovascular events in a patient with newly-diagnosed pancreatic tail tumor: A case report

¹ Department of Neurology, Chi Mei Medical Center

² Department of neurology, Sin-Lau Hospital

Background Among young stroke cases, the proportion of uncommon and undetermined etiologies is significantly higher. We reported a case with fatal cerebrovascular events associated with her concealed pancreatic tumor

Case report The 44 year-old widowed female was brought to ER due to acute right hemiplegia, linguistic dysfunction, and dysarthria. Other physical examinations findings were unremarkable. Acute intravenous thrombolysis was performed under the

impression of acute ischemic stroke. Her muscle power, linguistic function, and muscle powers improved on the second day. Her blood pressure, glucose, lipid profiles were normal. She also had normal RPR, antinuclear Ab, homocysteine, and anti-cardiolipin Ab results. Her first brain MRI scan showed acute embolic infarct involving left MCA posterior parietal territory and bilateral PCA territory occipital and bilateral cerebellum regions. The MRA study showed no obvious stenosis lesion. The echocardiogram showed no intracardiac thrombus or vegetation. She was placed on antiplatelet therapy after thrombolysis since the second day.

On the 12th day, she had mild fever and her consciousness level and right hemiplegia worsened. Brain CT shows new lesions at left temporal, left corona radiata, and right parietal regions, and grade 2 hemorrhagic transformation in the previous infarction. Her chest X ray shows bilateral pneumonia. On the 14th day, abdominal untrasounography shows a pancreatic tail tumor, and abdominal CT further indicated that malignancy invaded into left adrenal gland, and splenic artery and vein, and multiple metastatic lesion in the liver and stomach. Regional lymphadenopathy was also noted. Her tumor markers, including CEA, CA-125, and CA 19-9 were high. She received broad-spectrum antibiotic treatments

but the response was poor. Biopsy was not done due to unstable vital signs and thrombocytopenia. Her consciousness level, as well as her respiratory pattern, deteriorated in the following days, she was transferred to palliative team, and she died on the 21th day.

Discussion After Armand Trousseau's description in 1865, the association between cancer and hypercoagulation is well recognized. The incidence of thromboembolism in patients with malignancy ranges from 1% to 11%. The underlying mechanisms include tissue factor, tumor-associated cysteine proteinase, oncogene activation, carcinomas mucins, and others. It is still uncertain whether anticoagulant or antiplatelet is the most optimal treatment for those cerebral infarction caused by Trousseau's syndrome.

16

嚴重性腦靜脈竇栓塞使用靜脈竇內血栓溶解治療之案例報告

林文守 高鴻文 薛俊仁 陳俊安
國軍高雄總醫院神經內科 三軍總醫院神經放射科 三軍總醫院神經內科 國防醫學院

Intracranial Thrombolysis for Severe Cerebral Venous Sinus Thrombosis - A Case Report

Wen-Sou Lin, MD¹, Hung-Wen Kao, MD², Chun-Jen Hsueh, MD², Chung-An Chen, MD³

¹ Department of Neurology, Kaohsiung Armed Forces General Hospital, ² Department of Radiology, ³ Department of Neurology, ^{2,3} Tri-Service General Hospital, National Defense Medical Center, Taipei, Taiwan.

Background Cerebral venous and sinus thrombosis (CVST) is a rare stroke

disorder, which requires prompt recognition and appropriate intervention to prevent a devastating outcome. Intracranial thrombolysis is an alternative and effective method to anticoagulant therapy for the treatment of CVST, but is rarely used in Taiwan.

Case Report A 46-year-old man presented with a one-week history of intractable headache and progressive weakness of his right lower limb. The characteristic of increased of intracranial pressure were obviously and magnetic resonance venography of the brain confirmed a diagnosis of extensive venous sinus thrombosis. The patient was successfully treated by direct intracranial thrombolysis with urokinase with a dramatic relief of the headache and the neurologic deficits resolved gradually. No hemorrhagic transformation or other complication occurred in this treatment strategy. The patient was further received anticoagulants therapy and no neurologic deficit occurred anymore, though the brain magnetic resonance venography showed transverse-sigmoid sinuses remained occluded, but restoration of the superior sagittal and straight sinuses.

Conclusion This case highlights that early IST can provide rapid symptomatic relief because the associated symptoms, such as headache, seizure, and intracranial hypertension, are primarily caused by sinus occlusion.

17

急性缺血性中風病患靜脈注射過多 t-PA 並未增加症狀性腦出血：一醫學中 心經驗

林典佑^{1,3} 謝函潔^{2,3}

¹ 國立成功大學醫學院附設醫院神經部

² 國立成功大學附設醫院斗六分院 內科部
神經內科

³ 國立成功大學附設醫院中風中心

Above Standard t-PA Dose Did Not Increase Symptomatic Intracerebral Hemorrhage after Stroke Thrombolysis: Experience from a Medical Center

Tien-Yu Lin¹, Han-Chieh Hsieh²

¹ Department of Neurology, National Cheng Kung
University Hospital

² Division of Neurology, Department of Internal
Medicine, Dou-Liou Branch, National Cheng
Kung University Hospital

³ Stroke Center, National Cheng Kung University
Hospital

Background and purpose According to the results of NINDS trial, thrombolytic therapy with intravenous recombinant t-PA improves the outcome of acute ischemic stroke onset within 3 hours. The recommended dose of rt-PA infusion is 0.9mg/Kg. However, body weight may be over-reported by patient or family and the dose of rt-PA might be higher than 0.9mg/Kg. We aimed to know whether overdosage of intravenous rt-PA may increase symptomatic intracerebral hemorrhage (SICH) rate or not.

Methods We retrospectively reviewed the medical records of all patients received IV rt-PA from NCKUH with a diagnosis of acute ischemic stroke onset within 3 hours, from September 2006 to December 2012. According to rt-PA dose,

patients were divided into two subgroups: patients with rt-PA dose of less than 0.9mg/Kg and those greater than 0.9mg/Kg. SICH was defined as any deterioration of NIHSS by NINDS criteria.

Results During the study period, 275 patients received rt-PA within 3 hours. 80 patients (29.1%) received rt-PA dose greater than 0.9mg/Kg and 3 patients had SICH. 195 patients (70.9%) received tPA dose less than 0.9mg/Kg, 9 patients had SICH. The SICH rate was not significantly different between the two groups (3.8% versus 4.6%).

Conclusion The results of our study showed similar SICH rate whether the patients received rt-PA dose greater than 0.9mg/Kg or not. To expedite the rt-PA administration, using body weight reported by patient or family is a safe alternate if bed scale is not available.

18

血栓溶解劑治療用於住院中急性腦 栓塞病人之成效

林楸勳 陳志弘

國立成功大學附設醫院神經內科

Thrombolytic therapy for in-hospital patients with acute ischemic stroke

Mao-Hsun Lin, Chih-Hung Chen

Department of Neurology, National Cheng
Kung University Hospital

Background Intravenous tissue plasminogen activator (IV-tPA) has

been used broadly in the treatment of acute ischemic strokes. Sometimes in-hospital patients are candidates for IV-tPA. We analyzed the efficiency of procedures before IV-tPA treatment and outcomes between in-hospital and out-of hospital stroke patients.

Methods Chart review for patients treated with IV-tPA during the period from September, 2006 to August, 2012 in National Cheng Kung University Hospital was done. The length of time before receiving brain computed tomography (CT) scan, the time to start IV-tPA, and stroke outcomes were compared between in-hospital and out-of-hospital patients.

Results There were 220 patients enrolled in this study, including 10 in-hospital (IH) and 210 out-of hospital (OH) patients. The characteristics of patients between the two groups were similar. Time delay to receive brain CT (IH 73.3±46.7, OH 21.2±12.2 minutes, $p<0.01$) and to start IV-tPA (IH 158.2±53.5, OH 69.3±23.3 minutes, $p<0.01$) of in-hospital patients were significant. Outcomes after strokes were defined by modified Rankin scale (mRS) in both one month (mRS1) and three months (mRS3) after treatment of IV-tPA. There were no statistical differences in outcomes between in-hospital and out-of hospital patients in either one month (mRS1: IH 3.6±2.2, OH 2.7±2.0, $p=0.978$) or three month (mRS3: IH 3.5±2.5, OH 2.4±2.1,

$p=0.441$) after treatment with IV-tPA.

Conclusion Compared to out-of hospital patients, in-hospital stroke patients treated with IV-tPA were associated with less time delay before receiving brain CT and starting IV-tPA, but there were no significant difference in outcomes.

19

乙狀靜脈竇狹窄併搏動性耳鳴:個案報告

邱奕華¹ 賴彥君²

亞東紀念醫院¹ 內科部神經科² 影像醫學部

Pulsatile tinnitus associated with Sigmoid sinus stenosis : A Case Report

Yih-Hwa Chiou¹, Yen-Jun Lai²

¹Section of Neurology, Department of Internal Medicine; Far Eastern Memorial Hospital

²Department of Radiology; Far Eastern Memorial Hospital

Introduction Pulsatile tinnitus is usually due to a vascular anomaly around the skull base. Clinical and radiological work-up may reveal treatable causes, which can affect cerebral arterial or venous compartment. Understanding the physiopathologic mechanism underlying the vascular anomaly is crucial for orienting management and treatment of this condition. Our observations were made on a patient complaining of a high-pitched unilateral pulsatile tinnitus associated with unilateral stenosis of sigmoid sinus. A single-stage endovascular procedure (sigmoid sinus stenting) was carried out for treating the venous

anomaly, which relieved the pulsatile tinnitus successfully.

Case Report A 35-year-old woman, denied previous major systemic diseases, presented with a 2-year history of worsening right pulsatile tinnitus that had arisen gradually. Tinnitus was perceived louder in a quiet place and disappeared after compression of ipsilateral internal jugular vein. Physical examination and neurological examination revealed negative findings. She had normal otoscopic, tympanometric and audiometric evaluations. Auscultation didn't revealed any bruit or venous hum over head and neck. Brain magnetic resonance imaging with angiography and venography (MRI with MRA and MRV) revealed right sigmoid sinus stenosis. A diagnostic digital subtraction angiography (DSA) confirmed the stenosis over the right sigmoid sinus and excluded dural arterio-venous fistula or other vascular anomaly. Endovascular procedure with stenting for right sigmoid sinus stenosis was performed smoothly, and the pulsatile tinnitus was relieved immediately after this stenting.

Conclusion We report this case here and suggest that pulsatile tinnitus may be caused by sigmoid sinus stenosis, and endovascular procedure may relieve this symptom successfully.

20

顱內血管瘤是否仍然是急性梗塞性中風病患接受r-TPA治療的絕對禁忌?

邱瑋婷 陳龍
台北醫學大學 署立雙和醫院神經科

Is intracranial aneurysm an absolute contraindication for r-TPA treatment in acute ischemic stroke?

Wei-Ting Chiu, Lung Chan
Department of Neurology, Taipei Medical University-Shuang Ho Hospital

Background According to the current treatment guidelines for recombinant tissue-plasminogen activator (rt-pa), the presence of an intracranial aneurysm is a contraindication to thrombolysis. Non-enhanced computed tomography of the brain is the only diagnostic test required before administration of rt-pa, but it is difficult to detect cerebral aneurysms before receiving thrombolytic treatment. The safety of rt-pa in the setting of intracranial aneurysms is unknown still.

Case Report 2 cases who had incidental finding during followed up brain image or angiography after iv rt-pa treatment. Both of them had good outcome without aneurysm rupture. A 53 years old man, suffered from sudden onset of slurred speech with left side weakness and his condition improved after intravenous (iv) rt-pa (NIHSS from 9 to 2). A 3mm un-rupture saccular aneurysm over left A-com noted in his follow-up MRI. Another 58 years old female, admitted with sudden onset of consciousness change admitted to ER with NIHSS 16. 腦V. r-tPA was prescribed but no

improvement. MRI showed right internal carotid artery total occlusion, then intra-arterial recanalization was performed successfully and a 3mm saccular aneurysm was found over left ICA.

Conclusion In the general population, the prevalence of intracranial aneurysms is 3 to 6 %. One report showed that 4 % patients with intracranial aneurysms had symptomatic intracranial hemorrhage. The concern that these patients are at increased risk of hemorrhage after thrombolysis is still unwarranted. Should CT or MR angiography is needed before thrombolysis? Or rt-pa is safe in these patients? We will need more evidence to guide the treatment.

21

符合靜脈血栓溶解劑病患未即時啟動急性腦中風流程的原因分析

柯麗鈺¹ 湯頌君² 鄭建興²

¹亞東醫院神經內科 ²台大醫院神經部

Causes of Failed Identification for possible candidate of IV-tPA in acute ischemic stroke patients at the initiation of stroke code

Li-Chin Ko¹, Sung-Chun Tang², Jiann-Shing Jeng²

¹ Division of Neurology, Department of Internal Medicine, Far Eastern Memorial Hospital, New Taipei, Taiwan

² Department of Neurology, National Taiwan University Hospital, Taipei, Taiwan

Background “Code stroke” is a protocol to achieve rapid stroke assessment and treatment. However, certain percentage of acute ischemic stroke patients may not be identified as a

candidate for thrombolytic therapy at the triage and thus the stroke code can not be initiated properly. The aim of this study is to evaluate the sensitivity of “code stroke” protocol in National Taiwan University Hospital. We especially focus on the patients who were misclassified as non-stroke or stroke more than 3 hours but actually fulfilled the criteria for the thrombolytic therapy.

Methods A “code stroke” rapid access protocol was implemented at the National Taiwan University since July 2010. We analyzed patients who were discharged from August 2010 to August 2012 with the diagnosis of ischemic stroke and arrived at our emergency department within 3 hrs after symptoms onset. Data including demographics, initial presenting symptoms, initial NIHSS, neuroimage findings and clinical outcomes (modified Rankin Scale) at 3 months follow up was collected.

Results During the study period, a total of 203 ischemic stroke patients had the final diagnoses as within 3 hours symptom onset and 161 (79.3 %) subjects were initiated as “stroke code”. Of the 42 subjects not initiated as stroke code at the triage, 4 still received tPA treatment with the average of door to needle time of 93±24 minutes. Of the other 38 subjects, 8 subjects fulfilled the

guideline and recommended criteria of IV-tPA therapy. 3 of them who had middle cerebral artery territory infarcts with the presentation of conscious disturbance or confusion, another 3 with posterior circulation (brainstem, cerebellum) infarcts initially presenting as dizziness, and vertigo, and the last 2 subjects were partial middle cerebral artery territory infarct.

Conclusion Although the code stroke system may shorten in hospital therapeutic delays, certain percentage of stroke patients suitable for thrombolytic therapy may not be identified in triage based on our screening strategy, especially for patients presenting with atypical stroke symptoms, such as consciousness disturbance, dizziness, or vertigo

22

左側內頸靜脈逆流病患所表現的反覆且長時間全腦性失憶發作

紀心怡¹ 徐敏獻¹ 黃華思²
彰化秀傳醫院 神經科

Case report : repeated prolonged global amnesia in a patient with left internal jugular venous reflux

Hsin-I Chi, Min-Hsien Hsu, Hua-tzu Huang

¹Department of Neurology, Show Chwan Memorial Hospital

²Department of Radiology, Show Chwan Memorial Hospital

Background Transient global amnesia(TGA) is characterized by a sudden onset of an anterograde and retrograde amnesia that lasts up to 24 hours. The rate of annual recurrence of a second or a third episode is between 6%

and 10%.The pathophysiology of transient global amnesia is still un-determined and venous flow abnormalities have been suggested to be associated with the pathophysiology of TGA.

Case Report A 73-year-old woman was admitted due to acute onset of quadriparesis, severe dysarthria and respiratory failure after arguing with her family. Rapidly improvement of the neurological deficits evolved within 48 hours. Her daily activities became independent, but obvious anterograde amnesia was noted. This amnesia persisted but got slowly improved in 2 weeks. During this attack, her brain magnetic resonance images, biochemical, electroencephalography and drugs examinations were all within normal range except left internal jugular venous reflux after valsalva maneuver. One year later, the similar prolonged amnesia developed again and there was no any clinical laboratory abnormality.

Conclusion

Venous outflow resistance has been documented with several neurological diseases such as transient monocular blindness, normal pressure hydrocephalus, and chronic cerebral spinal venous insufficiency. In this case report, we offered a possible connection between venous reflux disorders and transient global amnesia with focal neurological deficits.

23

如何減少急性缺血性腦中風病患接受 血栓溶解劑的等待時間：一個適合在 社區醫院執行的處置流程

胡孟綺¹ 謝鎮陽^{1,2} 陳滄山¹

¹ 台南新樓醫院腦中風中心暨神經內科

² 國立成功大學臨床藥學與藥物科技研究所

How to Reduce the Door-to-Needle Time for Acute Ischemic Stroke Patients: a New Treatment Algorithm Suitable for Community Hospital

Monica Hu¹, Cheng-Yang Hsieh^{1,2}, Tsang-San
Chen¹

¹Stroke Center and Department of Neurology,
Tainan Sin Lau Hospital

²Institute of Clinical Pharmacy and
Pharmaceutical Sciences, National Cheng Kung
University, Tainan, Taiwan

Objective To present our new treatment algorithm for acute ischemic stroke (AIS) patients who arrived within 3 hours of onset and want to share our experience with our neurologic colleagues in other community hospitals suffering from the same difficult situation.

Background Compared with medical centers with in-house neurologist stand-by, it's a difficult job for community hospitals with 2-3 neurologists to perform thrombolytic therapy for patients with AIS. It's even harder to reduce the door-to-needle time below 60 minutes as the guideline suggested.

Methods We separate the preparation of thrombolytic therapy as two parts: the part 1 is what emergency room (ER) physician can do and the part 2 is what the neurologist can do. In the part 1, for

AIS patients potentially eligible for thrombolytic therapy, the ER physician should complete the brain computed tomography as well as other laboratory tests at the soonest, check the contraindications of thrombolytic therapy according to the patients' past history, find the key person of the patient who could sign the informed consent, and let the patients and families watch a video (either mandarin or Taiwanese version) dictating the risk and benefit of thrombolytic therapy for AIS. Those jobs should be done before the arrival of neurologists from home. In the part 2, neurologist should confirm the diagnosis of AIS, make the final decision, and get the informed consent.

Results There were four and three AIS patients received thrombolytic therapy before and after the implementation of the new treatment algorithm, respectively. The door-to-needle time was 84.3±19.8 vs. 63.3±5.0 minutes (Mann-Whitney U test, p=0.229). Of note is that 2 of the 3 thrombolyzed AIS patients after implementation of the new algorithms came to our ER at night or holiday, i.e. neurologists should took about 10-20 minutes to arrive ER from their home.

Conclusion Our new treatment algorithms reduced the door-to-needle time to nearly 60 minutes, though there's no statistical significance due to

small sample size. Our experience may be shared with other neurologists who were asked to do thrombolytic therapy and reduce door-to-needle time in community hospitals.

24

經頸動脈支架置入術後產生持續性低血壓和心律過緩

¹胡智銘 ¹洪國華 ²楊明祥

馬偕紀念醫院台東分院 ¹神經內科 ²放射科

Prolonged hypotension and bradycardia after carotid artery stenting

Chih-ming Hu, Kuo-Hua Hung, Ming-Chiang Yang

Department of Neurology, Radiologist, Mackay Memorial Hospital Taitung Branch

Background Hypotension and bradycardia are well-recognized complication after carotid artery stenting (CAS) and took the median time of 12 hours (1-96 hours). We presented a case who suffered from prolonged hypotension and bradycardia after CAS that subsided in 9 days.

Case report A 72-year-old male who is a heavy smoker with untreated hypertension for years was admitted to this hospital on 2012/03/15. He had right hemiplegia and mixed transcortical aphasia (NIHSS score:21). Magnetic resonance imaging disclosed infarction of the left superficial middle cerebral artery territory. Severe stenosis with calcified plaque in his left proximal internal carotid artery was showed by computed tomography angiography. His neurologic deficits improved gradually

(NIHSS score: 6) 30 days after the stroke. On 2012/04/17, we implemented a large tapered nitinol stent in his left proximal internal carotid artery. Hours after the procedure, hypotension (85/50 mmHg) and sinus bradycardia (38/min) were found. Treatment with isotonic solution and atropine injection were provided initially. For persistent hypotension and bradycardia, dopamine infusion (5~12 ug/kg/min) and temporary pacemaker were administered in subsequent 9 days. His hemodynamic status was stabilized after that.

Conclusion Reviewing the literatures, several studies indicated that there are several features which predicted the occurrence of hypotension or bradycardia after CAS. In this case, we postulated that the calcified plaque and a large stent may be the major factors which caused the prolonged hypotension and bradycardia after CAS.

25

退化性關節炎為中風之風險因子

徐敏獻 葉宗勳

彰化秀傳紀念醫院 神經內科

Whether Osteoarthritis Is A Stroke Risk Factor ? A Population Based Cohort Study

Min-Hsien Hsu MD, Chung-Hsin Yeh MD PhD

Department of Neurology, Show-Chwan

Memorial Hospital, Chang-Hua City

Background Osteoarthritis (OA) features a chronic inflammatory state

that may have systemic impact on atherosclerosis. In a population based retrospective cohort study, we aimed to examine whether osteoarthritis is a stroke risk factor.

Methods From a randomly sampled cohort of one million health insurance subscribers claimed from the Taiwan National Health Insurance, which identified 18,453 patients with osteoarthritis (ICD-9-CM code 715) between 1999 and 2007. The control group was a randomly selected population of 36,906 matched with age, sex. Subsequent occurrence of stroke was measured from their index ambulatory visit at least 5 years, and the association between OA and the hazard of developing stroke was estimated using Cox proportional hazard models.

Results Of the osteoarthritis cohort, 1,331 (13.7/1,000 person-years) experienced stroke during the follow-up period as compared to 2,219 (10.2/1,000 person-years) in the control cohort. The adjusted hazard ratios for all stroke was 1.18 (95% CI, 1.10 - 1.28), ischemic stroke 1.24 (95% CI, 1.15 - 1.34) and hemorrhagic stroke 1.29 (95% CI, 1.08 - 1.55) respectively by the Cox proportional hazard model with adjustment for age, gender and comorbidities including hypertension, diabetes, coronary arterial diseases, atrial fibrillation and dyslipidemia.

Conclusions Approximately 40% of stroke patients may have poorly defined stroke risk factors. Results from the present study suggest that osteoarthritis (OA) is one of the modest but significant stroke risk factors.

26

缺血性中風病患住院期間死亡之相關因素

翁竣德 宋昇峰 吳啟順 許永居 蘇裕翔
洪菱謙 李建欣
嘉義基督教醫院神經科

Factors related to in-hospital mortality in ischemic stroke patients

Cheung-Ter Ong, Sheng-Feng Sung, Chi-Shun Wu, Yung-Chu Hsu, Yu-Hsiang Su, Chen-Hsien Li, Ling-Chien Hung
Department of Neurology, Ditmanson Medical Foundation, Chia-Yi Christian Hospital, Chia-Yi Taiwan

Object To evaluate the prevalence of in-hospital mortality and to investigate the causes and risk factors of in-hospital mortality.

Background At present, in-hospital mortality in stroke patients still occurred in clinical practice. We need to investigate the risk factors of in-hospital mortality and to reduce in-hospital mortality rate.

Methods The stroke included all of the patients who were admitted to Chia-Yi Christian hospital between 2007-1-1 and 2011-12-31 and them was diagnosed as ischemic stroke. We excluded the patients whom were

diagnosed as transient ischemic attack or vertebrobasilar artery insufficiency.

Results Between 2007-1-1 and 2011-12-31 there were 2557 patients admitted to Chia-Yi Christian hospital and were diagnosed as ischemic stroke. There were 78 patients die in hospital. The in-hospital mortality rate is 3.07% (78/2557). After logistic regression analysis, heart disease and stroke severity was significant related to the risk of in-hospital mortality. In comparison to the patients without heart disease, the odds ratio of in-hospital mortality is 6. The causes of in-hospital mortality were stroke in 48 patients (40 anterior circulations, 8 posterior circulations), hemorrhagic transformation in 4 patients, respiratory failure in 8 patients, infection with septic shock in 7 patients, acute myocardial infarction in 3 patients, multiple organ failure in 3 patients, other causes in 4 patients.

Discussion The in-hospital mortality rate (3.07%) is lower than previous report in Taiwan, which the fatality rate of acute ischemic stroke is 6.7% (1984-1986). Heart disease is a risk factor of in-hospital mortality in ischemic stroke patients. The main cause of mortality is stroke itself. Whether the reduction in in-hospital mortality is related to thrombolytic therapy, need further investigation.

27

急性脊髓梗塞無法由核磁共振擴散影像顯示病灶：個案報告

高伊慧 湯頌君 鄭建興
台大醫院神經部

Acute Spinal Cord Infarction Without Visible MR Diffusion Imaging Lesion: A Case Report

Yi-Hui Kao, Sung-Chun Tang, Jiann-Shing Jeng
Department of Neurology, National Taiwan University Hospital, Taipei, Taiwan.

Background Spinal cord infarction (SCI) is an uncommon disease characterized by acute motor and sensory deficits below the affected cord level. Diagnosis of acute SCI is often difficult and heavily relied on the spine MRI study. Here, we presented a case of SCI with initial negative spine MRI, including diffusion-weighted imaging (DWI), at hyperacute stage.

Case report A case of 60-year-old man with history of hypertension visited our emergency room for acute onset of chest pain and weakness of bilateral hands. Initially, aortic dissection was suspected, but chest CT showed diffuse atherosclerosis of the aorta without evidence of dissection. Neurological examination showed weakness of bilateral wrists and hands, and thus acute cervical radiculopathies were impressed. However, spine MRI performed at 4 hours after symptom onset showed no abnormality on both T2 weighted image and DWI. He had bilateral leg weakness and numbness over the legs and trunk below the T2

dermatome a few hours later. Lumbar puncture showed normal cell count, glucose and total protein. Autoimmune and tumor marker screenings were all negative. Follow-up cervical cord MRI 4 days later showed intramedullary hyperintensity on T2WI with slight contrast enhancement at the C6-T1 level. Increased DWI with matched decreased ADC was noted in the aforementioned regions, suggestive of SCI. He was treated with aspirin since the 2nd day, and his neurological recovery was well with only mild four limbs weakness and numbness. He could ambulate without assistance 2 months after discharge.

Conclusion Spine MRI, including DWI, could be negative in SCI patients at the hyperacute stage. Careful clinical evaluation especially repeated MRI exam should be performed in patients with acute myelopathy and initially negative image results.

28

靜脈注射血栓溶解劑治療急性心肌梗塞伴隨急性缺血性腦中風：一病歷報告

張偉倫 洪翠虹 葉宗勳
彰化秀傳紀念醫院神經內科

Acute Ischemic Stroke Following Acute Myocardial Infarction Treated With Intravenous Tissue Plasminogen Activator – A Case Report

Wei-Lun Chang, Tsui-Hung Hung, Chung-Hsin Yeh
Department of Neurology, Show-Chwan Memorial Hospital, Changhua, Taiwan

Background Stroke is a severe

complication of myocardial infarction (MI). We presented a case of acute ischemic stroke (AIS) following acute myocardial infarction (AMI) treated with intravenous tissue plasminogen activator (tPA).

Case report A 68-year-old single man was admitted due to AMI and AIS (left sided weakness and slurred speech) treated with intravenous tPA injection in a local hospital. Tracing his history, he was sent to the emergency department (ED) of a local hospital due to dyspnea, chest tightness and near-syncope. Left sided weakness and slurred speech attacked at the ED. No intracranial hemorrhage (ICH) was found by computed tomography (CT) of the brain and his *National Institutes of Health Stroke Scale* (NIHSS) was 9. Then he received intravenous tPA therapy (dosage for AIS, total 50mg, body weight 64 kg) under the impression of AIS. Left sided weakness and chest tightness improved partially after tPA injection. However, high troponin-I was found and AMI was confirmed then. Under the request of the patient, he was transferred to our ICU (intensive care unit).

Left sided weakness progressed on the next day and brain CT showed right pontine infarction. Then we started dual antiplatelet and enoxaparin therapy. Magnetic resonance imaging (MRI) of the brain revealed right pontine infarction without significant

註解 [CM1]: NIHSS?, lesion vessel?
(Right pontine infarction noted by MRI later, MRA: no significant stenosis of VA / BA).

註解 [CM2]: ? 50 mg

stenosis of basilar or vertebral artery on the third day after admission. Dyspnea and pulmonary edema persisted under medical treatment so he received percutaneous coronary intervention (PCI) 10 days after admission. Stenting for right coronary artery (RCA) and plain old balloon angioplasty (POBA) for left circumflex artery (LCX) was done. His symptoms improved after PCI; hence he discharged under a stable condition later.

Discussion MI in recent three months is a contraindication for tPA administration in AIS. Similarly, history of ischemic stroke within the preceding three months is a contraindication for tPA administration in AMI but an important exception is AIS seen within three hours which may be treated with thrombolytic therapy. The dosage of tPA is different between AMI and AIS. Further guideline is needed for the usage of tPA in the setting of two diseases attack concurrently.

29 老年中風病人以吸入性肺炎或噎入為死因的報告(美國)

張嘉祐¹ 鄭天浚¹ 呂宗學²

¹ 奇美醫學中心 神經內科

² 國立成功大學醫學院公衛所

Reporting of Aspiration Pneumonia or Choking as a Cause of Death in

Elderly Patients Who Died with Stroke

Chia-Yu Chang, MD, MS; Tain-Junn Cheng, MD, PhD; Tsung-Hsueh Lu, MD, MPH

Background and purpose Little is known regarding how many patients who have had a stroke die from fatal

pulmonary complications such as aspiration pneumonia (AP) and choking each year in the United States. This study aimed to determine the frequency of reporting of AP or choking as a cause-of-death (COD) on death certificates with mention of stroke in the US.

Methods We used the multiple COD database of CDC WONDER for the years 2001–2009 to identify death certificates with mention of stroke (ICD-10 code I60-I69), AP (ICD-10 code J69) and choking (ICD-10 code W78-W80) for those aged 65 years or above for analysis.

Results Of 1 916 882 death certificates for those aged 65 years or above with mention of stroke in the US between 2001 and 2009, 5.7 % (n=109 038) reported AP as a COD and 1.7 % (n=31 605) reported choking as a COD. The frequency of reporting of AP as a COD was highest in Hawaii (9.6%) and lowest in New York (3.5%). The frequency of reporting of choking as a COD was highest in Vermont (3.5%) and lowest in Maryland (0.6%). The odds ratio of reporting AP or choking as a COD decreased from 2001 to 2009, was higher among male deceased, and increased with age of the deceased.

Conclusions On average, around 12000 elderly patients with stroke died from AP and 3500 elderly patients with stroke died from choking per year in

註解 [CM3]: How long after AIS? Which vessels was occluded (RCA and LCX)? Heparin use after PCI (No)? Brain CT after AIS (right pontine infarction) and before PCI (no)?

the US during the past decade. Efforts are needed to reduce the number of deaths from these two preventable COD.

30

頸動脈支架置放術前後之腦血流動力學及感壓反射的變化

許立奇^{1,3} 張豐基^{2,3} 郭博昭⁴ 翁文章^{1,3}
胡漢華^{1,3}

¹ 台北榮民總醫院神經醫學中心

² 放射線科

³ 國立陽明大學醫學系

⁴ 國立陽明大學腦科所

Cerebral Hemodynamic and Baroreflex Sensitivity after Carotid Artery Stenting

Li-Chi Hsu^{1,3}, Feng-Chi Chang^{2,3}, Terry BJ Kuo⁴,
Wen-Jang Wong^{1,3}, Han-Hwa Hu^{1,3},

¹ Department of Neurology

² Department of Radiology, Taipei Veterans General Hospital

³ National Yang-Ming University School of Medicine

⁴ Institute of Brain Science, National Yang-Ming University, Taipei, Taiwan

Objectives The long-term hemodynamic effects of carotid angioplasty and stenting (CAS) remain unclear. Therefore, we sought to investigate longitudinally the alterations in cerebral hemodynamics in patients undergoing CAS.

Materials and Methods A total of sixty-three symptomatic patients (all male, 19 had transient ischemic attack and 44, minor stroke; mean age: 77.3±6.3 years, range: 51-86) were studied prospectively. The mean blood flow velocities (MBFV) and pulsatility index (PI) of bilateral middle cerebral arteries (MCA) were evaluated by transcranial color-coded Doppler (TCCD)

ultrasonography. Cardiac autonomic activities were represented by the measurement of baroreflex sensitivity (BRS). All parameters were followed at baseline, 1, 3, 6 and 12 months after CAS.

Results The MBFV and PI of ipsilateral MCA were significantly lower than those of the contralateral side preoperatively. Postoperatively, there was a significant increase of MBFV in the ipsilateral MCA till 2 weeks after stenting and then gradually decreased but remained stable 1 year after CAS. A non-significant increase of MBFV in the contralateral MCA was also noted after CAS. In contrast, the values of BRS decreased significantly 1 month after stenting and returned to baseline levels six months after CAS.

Conclusions CAS resulted in improved global cerebral hemodynamic status. In contrast, BRS did not normalize but only returned to its baseline value 6 months after stenting.

31

同時存在於顱內硬膜之多發性動靜脈瘻管及脊髓之動靜脈血管瘤：病例報導

連家儀，許哲維，陳尚德
高雄長庚紀念醫院神經內科

Concomitant intracranial dural arteriovenous fistulas and spinal arteriovenous malformation: report

of one case

*Chia-Yi Lien, Wei-Che Hsu, Shang-Te Chen
Department of Neurology, Chang Gung Memorial
Hospital, Kaohsiung Medical Center*

Background Arteriovenous fistulas (AVFs) are characterized by abnormal shunting of blood between the arterial system and the venous system, without the presence of a normal intervening capillary bed. However, concomitant intracranial dural arteriovenous fistulas (DAVF) and spinal arteriovenous malformation (AVM) is rarely reported in the literature.

Case Report A 57-year-old man was admitted due to progressive cognitive deterioration for one month. He has past history of intracerebral hemorrhage and seizure, diagnosed in 2004. After admission, initial brain MRI revealed multiple small hemorrhage over bilateral thalami and basal ganglia. However, during hospitalization, he was found to be disoriented, and had urine incontinence. Because brain MRV revealed left carotico-cavernous sinus fistula, and deep vein thrombosis over distal straight sinus, heparin was given. Conventional angiography showed (1) dural arterio-venous fistula over midline suboccipital area (2) left carotico-cavernous sinus fistula and (3) high cervical arterio-venous malformation; thus, Onyx embolization to feeding artery was performed. Three days after embolization, acute deterioration of consciousness was noted (E1-2VeM2), and emergent brain CT

revealed diffuse interventricular hemorrhage. Heparin was discontinued and emergent surgery with bilateral external ventricular drain placement for hydrocephalus was done at the same day. Comatose status persisted and patient died 5 days after surgery.

Conclusion Concomitant existence of cranial dural arteriovenous fistulas (DAVFs) and spinal AVM is uncommon, and DAVF may masquerade as cerebral venous thrombosis. Thus, the angiography should be performed for the precise diagnosis for the vascular abnormalities and for the early multidisciplinary management of the DAVF.

32**慢性腎疾對中風病患接受血栓溶解治療預後的影響**

*陳志昊 湯頌君 鄭建興
國立台灣大學醫學院附設醫院 神經部*

Impact of Chronic Kidney Disease on Outcome of Ischemic Stroke Patients Receiving Intravenous Thrombolysis

*Chih-Hao Chen, Sung-Chun Tang, Jiann-Shing
Jeng
Department of Neurology, National Taiwan
University Hospital, Taipei, Taiwan*

Background and Purpose Patients with chronic kidney disease (CKD) are known to have abnormalities in coagulation and platelet function. It remains uncertain whether impaired renal function may refer to poor outcome in acute ischemic stroke

patients receiving thrombolytic therapy. Previous study showed that estimated glomerular filtration rate (eGFR) <60 ml/min/1.73m² was not a poor outcome indicator in recombinant tissue plasminogen activator (rt-PA) treated stroke patients. As demonstrated by a large population-based study, the graded risk of cardiovascular events and mortality rose sharply for subjects with an eGFR <45 ml/min/m². This study aimed to evaluate if moderate renal function impairment (eGFR <45) is a significant outcome predictor in rt-PA treated patients.

Methods We reviewed consecutive patients who received intravenous rt-PA for acute ischemic stroke during the period of January, 2006 and September, 2012 from the National Taiwan University Hospital Stroke Registry data. An unfavorable outcome was defined as modified Rankin scale >1 at 3 months after stroke onset. The association between renal function and outcome at 3 months after stroke was evaluated, as well as any difference of hemorrhagic transformation after rt-PA administration between CKD and non-CKD patients.

Results Of 265 included patients, 159 (60%) were male, the mean age was 68.4 ± 12.4 years, and 47 (17.4%) patients had eGFR <45 . Patients with eGFR <45 were older, higher frequencies of hypertension, diabetes mellitus, hyperlipidemia, coronary artery disease, and old stroke

than those with eGFR ≥ 45 . The proportion of unfavorable outcome was significantly higher in patients with eGFR <45 (78.3% vs. 60.8%, $P = 0.015$). After adjustment of age and sex, eGFR <45 showed a trend toward unfavorable functional outcome (odds ratio 2.13, 95% confidence intervals 0.95–4.74, $P = 0.065$).

Conclusion Although not statistically significant, acute stroke patients with moderately impaired renal function may tend to have unfavorable outcome after intravenous thrombolysis. Further study with larger sample size is potentially indicated to verify our preliminary result.

33

頸脊髓合併雙側小腦梗塞：病例報告

陳泓儒 黃志善

臺北醫學大學 市立萬芳醫院 神經內科

Combined cervical cord and bilateral cerebellar infarction: A

Case Report

Hung-Ju Chen, Chih-Shan Huang
Department of Neurology, Wan Fang Hospital,
Taipei Medical University

Background Spinal cord infarction (SCI) is uncommon, accounting for 1.2% of all strokes, but the outcome may be more disabling. Combined cerebellar and spinal ischemic stroke is even rarer. Diffusion-weighted magnetic resonance imaging (DW-MRI) is potentially a useful and

feasible technique for the early detection of spinal cord infarction. We report a patient with combined cervical spinal cord and bilateral cerebellar infarction.

Case Report A 49-year-old man presented with sudden onset of quadriparesis and urinary retention with preceding back pain after he lifted heavy objects. Hypoesthesia below the C8 level, impaired proprioception and hyporeflexia were also found. Cervical spine MRI showed longitudinal high signal intensity at C3-C7 and 'owl's eyes' sign on T2-weighted image, suggesting spinal cord infarction. DWI showed hyperintense signals at C3-C7 and bilateral cerebellar hemisphere which were compatible with recent infarction. Extracranial carotid duplex sonography revealed no abnormal findings and the 24-hour Holter electrocardiogram (ECG) reported no significant arrhythmia such as atrial fibrillation. Echocardiography showed no evidence of intramural thrombus. He had normal level of protein C, protein S, anti-thrombin III, homocysteine and erythrocyte sedimentation rate. He had negative results for rheumatoid factor, anti-nuclear antibody, anti-cardiolipin antibody, anti-phospholipid antibody, and venereal disease research laboratory test. The patient received aspirin for secondary stroke prevention. During hospitalization, hypotension with excessive sweating had been noted. Computed tomography angiography (CTA) showed no vascular

abnormalities including aortic dissection. Autonomic dysfunction associated with spinal cord infarction was impressed.

Conclusion The lesions of spinal cord in our case could be confirmed as acute infarction based on the simultaneous involvement of bilateral cerebellum on DW-MRI. In spinal cord infarctions, brain involvement might be considered especially the territory of posterior circulation. The relationship and etiology need further investigations.

34

以單側週邊型顏面神經麻痺為表徵之橋腦梗塞—個案報告

陳建志 劉崇祥 蔡崇豪
中國醫藥大學附設醫院神經科部

A Case Report of Pontine Infarction Presenting with Unilateral Peripheral-type Facial Palsy

Jiann-Jy Chen, Chung-Hsiang Liu, Chon-Haw Tsai
Department of Neurology, China Medical University Hospital, Taichung,

Background 造成週邊型顏面神經麻痺最常見的原因為貝氏麻痺(54%)，其次為耳性帶狀疱疹(Ramsay-Hunt 症候群)(20%)、外傷性麻痺(12%)或其他(4%)。以腦幹中風為表徵者實屬罕見，特提出報告。

Case Report 71歲老年男性，因突發左側顏面神經麻痺至本院急診，合併左側突發性耳聾、眩暈及寬大步伐。理學檢查顯示左側額頭抬頭紋消

失，眼皮無法閉攏，鼻唇溝淺化，嘴角無法上揚，臉頰更無法呈現笑紋，應為左側週邊型顏面神經麻痺(House-Brackmann 分級第 4 級)。腦部磁振造影顯示左側下橋腦及小腦下半月葉之急性梗塞。美國國家衛生研究院中風評量表(NIHSS)評為 4 分，由於本院「症狀輕微」之定義為 NIHSS < 6，本個案暫不須接受靜脈注射組織胞漿素原活化劑，僅須接受點滴輸液及抗血小板劑 aspirin 治療，並同時保護眼睛，給予局部復健及針灸治療。爾後 1 週，左側聽力障礙及顏面神經麻痺並無恢復，但眩暈緩解，遂於狀況穩定下出院。往後追蹤 4 個月，左側聽力障礙及顏面神經麻痺依舊。

Conclusion 橋腦梗塞僅以週邊型顏面神經麻痺為表徵者很罕見，目前僅有個案報告而已。本個案之單側週邊型顏面神經麻痺同時合併了同側突發性耳聾、眩暈及小腦徵兆，不應視為常見之貝氏麻痺，應考慮腦幹病變。

35

延遲外傷性內頸動脈剝離導致中左大腦動脈中風臨床失語症恢復之特殊變化：病例報告

陳桂銓 葉旭霖 吳亞榮 葉建宏 邱浩彰
新光吳火獅紀念醫院 神經科

Delayed traumatic internal carotid artery dissection leads to middle cerebral artery infarct with special pattern of language recovery: A case report

Guei-Chiuan Chen, Hsu-Ling Yeh, Ya-Ying Wu, Jiann-Horng Yeh, Hou-Chang Chiu
Departments of Neurology, Shin Kong Wu Ho-Su Memorial Hospital, Taipei

Background The most possible etiology of carotid artery dissection was

spontaneous. We present a case of delayed trauma-related internal carotid dissection with special pattern of language recovery.

Case Report A healthy 38-year-old right handed single man, has 18 years of education, was brought to ED after a traffic accident. He majored in English in college and has been worked as a manager in standard foods company. No loss of consciousness or focal neurological signs were noted. He was discharged four hours later. He was admitted to our hospital the next day for management of left facial bone fracture. He developed acute global aphasia and weakness of right side limbs 17 hours after trauma. NIHSS score was eighteen and left MCA infarct was impressed. Brain CT showed left dense middle cerebral artery (MCA) sign and loss of lentiform nucleus sign 3.5 hours after stroke. Brain CTA revealed left internal carotid artery (ICA) total occlusion at proximal portion 8 hrs after stroke. Absent flow of left ICA, decreased mean velocity with low pulsatility index of left MCA and focal stenotic flow of left MCA were found on carotid duplexes twenty-two hours after stroke. B-mode of extracranial duplex revealed intimal flap and hypoechogenic vessel wall in left ICA. ICA dissection was highly suspected. Brain MRA revealed dissection of left proximal ICA two days after stroke. He could pronounce single sounds three days after stroke. Gradual

improvement of muscle power in right side limbs was also found. He started to say single Chinese words five days after stroke. He was able to walk independently around ten to fourteen days after stroke. Three weeks after stroke, he could repeat a whole sentence and comprehend partially, but still poor in using English. Two months after stroke, he still have some difficulty in simple communication, though he was able to give longer sentences. Follow-up brain MRA revealed mild recanalization twenty days after stroke. Brain duplexes revealed no intimal flap and recovery of left ICA dissection forty-seven days after stroke.

Conclusion We present this relatively delayed onset of traumatic ICA dissection with special pattern of language recovery. The ICA dissection was conformed by brain MRI and carotid duplex. Discrepancies existed in mother language and second language.

36

成功地以手術治療巨大的顱外內頸動脈動脈瘤併發大範圍的缺血性腦中風

陳崇文¹ 吳清文² 陳淑儀¹ 楊自強¹ 許弘毅¹

¹ 童綜合醫院神經內科

² 童綜合醫院心臟血管外科

Giant aneurysm of the extracranial internal carotid artery presenting with ischemic hemispheric stroke successfully treated by surgery

Chung-Wen Chen¹, Wu Cing-wen², Shu-Yi Chen¹, Chi-Chiang Yang¹, Hung-Yi Hsu¹

¹Section of Neurology, Department of Internal Medicine, Tung's Taichung MetroHarbor Hospital

²Department of cardiac surgery, Tung's Taichung MetroHarbor Hospital

Background Aneurysm of the extracranial internal artery is rare, with incidence of 0.8-1% of all aneurysms. Embolic stroke is one of the complications. We present a case with severe ischemic stroke combined with a giant aneurysm of extracranial internal carotid artery. There was good recovery after angioplastic surgery.

Case Report A 73 year-old married man was admitted due to sudden onset of left hemiplegia. In the morning, he didn't get up as usual. His wife found him on the bed. He was then sent to hospital. There were flaccid weakness of left upper and lower limbs and forced right deviation of both eyes. Initial brain computed tomography (CT) showed normal findings. One day later, magnetic resonance imaging (MRI) of brain showed acute brain infarction over right middle cerebral artery territory (MCA). Echocardiography and electrocardiography showed normal results. He had hypertension without regular medication. He didn't have diabetes mellitus, hyperlipidemia, or smoke habit. Carotid color duplex (CCD) showed a large thrombotic plaque-like lesion of right internal carotid artery (ICA), causing severe stenosis. 256-sliced CT angiography (CTA) revealed a giant aneurysm of right ICA and multiple hemorrhagic infarcts of right MCA with mass effect. On the day of CTA, he became drowsier. One week later, after high

intracranial pressure was under control, excision of aneurysm and endarterectomy were performed. After surgery, his condition got better. He could sit in the wheelchair, with left hemiplegia, and talk as before, continuing physical therapy 2 months later. Repeated CCD showed patent and smooth lumen of right ICA.

Conclusion Aneurysm of internal carotid artery related embolic stroke is a rare condition. This case received surgery in the subacute stage of stroke. The prognosis was good. CTA is important in patient with stroke to make correct diagnosis and early treatment. To get rid of cause of stroke, such as surgery for aneurysm, is mandatory.

37

重覆性高壓氧治療對急性腦中風的前驅研究

陳紹原 王文奇 王國慶 陳昭境 陳志豪
劉謙謙 葉炳強
財團法人天主教耕莘醫院 神經內科 高壓氧科;
天主教輔仁大學 醫學系

Effects of Repetitive Hyperbaric Oxygen Treatment in Patients with Acute Cerebral Infarction: A Pilot Study

Shao-Yuan Chen^{1,2,3}, Vinchi Wang^{1,3},
Kaw-Chen Wang¹, Chao-Ching Chen^{1,3},
Chih-Hao Chen¹, Yi-Chien Liu¹,
Ping-Keung Yip^{1,3}

¹ Department of Neurology, Cardinal Tein Hospital, New Taipei City, Taiwan

² Department of Hyperbaric Medicine, Cardinal Tein Hospital, New Taipei City, Taiwan

³ School of Medicine, Fu Jen Catholic University, New Taipei City, Taiwan

Objective The role of hyperbaric oxygen therapy (HBOT) in the treatment of acute ischemic stroke is controversial.

This study prospectively assessed the efficacy and feasibility of applying 10 repetitions of HBOT at 2.0 ATA for one hour in patients with mild acute ischemic stroke within 3-5 days after stroke onset to reinvestigate the role of HBOT in treating acute ischemic stroke.

Methods The HBOT group (n = 16) received conventional medical treatment with 10 sessions of adjunctive HBOT within 3–5 days after stroke onset, while the control group (n = 30) received the same treatment but without HBOT. Early (around two weeks after onset) and late (one month after onset) outcomes (National Institutes of Health Stroke Scale, NIHSS scores) and efficacy (changes of NIHSS scores) of HBOT were evaluated.

Results The baseline clinical characteristics were similar in both groups. Both early and late outcomes of the HBOT group showed significant difference ($P \leq 0.001$). In the control group, there was only significant difference in early outcome ($P = 0.004$). For early efficacy, there was no difference when comparing changes of NIHSS scores between the two groups ($P = 0.140$) but there was statistically significant difference when comparing changes of NIHSS scores at one month ($P \leq 0.001$).

Conclusion The HBO therapy used in this study may be effective for patients with acute ischemic stroke and is a safe and harmless adjunctive treatment.

38

案例報導:蛋白 S 缺乏症與中風之懷孕婦女

陳惠萱¹ 蔡銘駿¹

中國醫藥大學附設醫院 神經部¹

Case Report : Protein S deficiency and pregnant woman with ischemic stroke

Hui Hsuan Chen¹, Ming-Jun Tsai¹

¹ Department of Neurology, China Medical University Hospital, Taichung, Taiwan

Background Pregnancy women are at increased risk of thromboembolic disease. We reported a case of pregnant woman with ischemic stroke that is associated with protein S deficiency.

Case Report This 33-year-old previous healthy pregnant (G3 P1 AA1) woman suffered from sudden onset of disturbed consciousness and right side weakness at the gestational age of 9 weeks. Severe hyperemesis was noted during first trimester of this pregnancy. On the day of admission, she suffered from sudden onset of consciousness disturbance in the afternoon which persisted for minutes. Mild right side weakness and little spontaneous speech were found. On examination, neurologic examination showed decreased muscle power on right extremities (4 point) and motor aphasia. Brain MRI (DWI) showed lesions with increased intensity in left insular cortex and small area of

cortex of left parietal lobe. On admission, we checked laboratory data including lipid profile, thyroid function, HbA1c, homocysteine, autoimmune profile, function of coagulation and antiphospholipid antibody. All above finding are normal. 24hrs Holtor's scan showed sinus rhythm with isolated atrial ectopy. Transcranial Doppler showed increased flow velocity of left middle cerebral artery. Although low protein S (52.2%) was detected, anticoagulation was not used because of first trimester of pregnancy. We prescribed clopidogrel 75mg once daily for stroke prevention. Two weeks after discharge, the patient received artificial abortion due to severe hyperemesis. Two weeks after abortion, protein S was back to normal range (92.2 %). No recurrent stroke or other complication was detected three months after stroke.

Discussion Stroke occurring during pregnancy is a rare condition. Pregnant women have increased risk of stroke. Previous case series studies showed protein S deficiency resulted in hypercoagulability which primarily affects veins and rarely causes arterial thrombosis. Whereas, many meta-analysis still showed protein S deficiency appears to be associated with arterial thrombosis in the brain. We suggested clopidogrel may be safe in the first trimester of pregnancy and protein S deficiency during pregnancy

can be corrected by abortion, whereas the role of abortion in protein S deficiency during pregnancy is still undetermined and further investigation may be needed.

39

顱內血管超音波系列追蹤在可逆性腦血管收縮症候群的應用

陳貴津 吳毓嘉 劉雅婷 林秀芬
高雄醫學大學附設中和紀念醫院 神經內科

Serial Transcranial Color Doppler Evaluation in Reversible Cerebral Vasoconstriction Syndrome

Kuei-Chin Chen, Yu-Chia Wu, Ya-Ting Liou, Hsiu-Fen Lin
Department of Neurology, Kaohsiung Medical University Chung-Ho Memorial Hospital

Background Reversible cerebral vasoconstriction syndrome (RCVS) is a rare disorder characterized by thunderclap headaches with reversible vasoconstriction of cerebral arteries. Follow up of reversible segmental cerebral vasoconstriction is usually performed by cerebral angiography, but using non-invasive transcranial Doppler (TCD) to monitor vasoconstriction could be a better tool.

Case Report A 58-year-old female was admitted due to acute onset episodic thunderclap headaches without other accompanying clinical features. Computed tomography (CT) revealed subarachnoid blood along bilateral cerebral sulci. Computed tomography angiography (CTA) work-up for aneurysm was negative but cerebral angiography had evidence of multiple segmental stenosis which matched with

her TCD findings. The TCD showed increasing mean velocity with turbulent flow over multiple segmental vessels including bilateral ACAs, MCAs, Left PCA and basilar artery. After Nimodipine treatment, her headache was gradually subsided. We followed her TCD 4 weeks and 8 weeks after disease attack. The serial TCD revealed gradually normalized flow in all cerebral arteries.

Conclusion TCD serial changes of the present patient highlighted the non-invasive follow up method would enable us to monitor the degree of vasoconstriction in RCVS.

40

可逆性腦血管收縮症候群合併頭痛及聽力損失-病例報告

陳嘉偉¹ 莊俊義² 沈昭諭³ 蔡世傑¹ 呂聰明¹ 周希誠¹ 陳秋媚¹ 孔勝琳¹
中山醫學大學附設醫院 神經科¹ 耳鼻喉科² 醫學影像科³

Reversible cerebral vasoconstriction syndrome presents with thunderclap headache and sudden hearing loss: A Case Report

Chia-Wei Chen¹, Chun-Yi Chuang², Chao-Yu Shen³, Shih-Jei Tsai¹, Tsong-ming Leu¹, Hsi-hsien Chou¹, Chiu-mei Chen¹, Sheng-Ling Kung¹
Department of Neurology¹, Otolaryngology², Diagnostic Radiology³, Chung Shan Medical University Hospital

Introduction Reversible cerebral vasoconstriction syndrome is characterized by recurrent episodes of thunderclap headache and by reversible vasoconstriction which typically affects young women leaving minimal

or no neurologic deficits. It is characterized by multifocal narrowing of the cerebral arteries that resolves over days to weeks. Diagnosis can be hampered by the dynamic nature of clinico-radiological features. Stroke can occur a few days after initial normal imaging, and cerebral vasoconstriction is at a maximum on angiograms 2-3 weeks after clinical onset.

Case presentation This is a healthy 45-year-old female without the history of systemic disease or headache. She presented with the complaint about abrupt onset of severe headache in the right frontal region associated with tinnitus in the right ear for 5 days. Pure tone audiometry disclosed right ear low tone sensorio-neural hearing loss. Except hearing loss, patient presented no other neurologic deficits on examination. Serial image studies included brain CT and MRI with contrast enhancement indicated suspect focal stenosis at the M1-M2 junction of left MCA and the V4 segment of the left vertebral artery. Laboratory workups including blood cell count, chemistry, and CSF studies yielded no evidence of CNS infection, hemorrhage or inflammatory course. Six days after the onset of symptoms, intracranial angiography was performed and it disclosed multiple segmental stenosis of the intracranial arteries involving bilateral anterior and posterior circulation. The hearing impairment dramatically improved after intravenous

nimodipine (a calcium channel blocker, used as a vasodilator) administration and she was discharged with oral nimodipine 60mg 4 times per day. The following contrast-enhanced brain MRI scan in 1 month and 5 months later demonstrated remission of the vascular lesions.

Conclusion Acute hearing impairment is seldom reported in RCV cases. In our case, the clinical presentation of dramatic remission of both hearing impairment and thunderclap headache resulting from RCVS after nimodipine therapy may suggest these two diseases shared common pathogenesis mechanism.

41

2012 年台灣世界中風日活動後民眾的腦中風知能探討報告

陳龍¹ 施淑芳²

¹台北醫學大學署立雙和醫院神經內科

²國立台灣師範大學 健康促進與衛生教育學系

Stroke literacy after the World Stroke Day 2012

Lung Chan¹, Shu-Fang Shih²

¹Department of Neurology, Taipei Medical University-Shuang Ho Hospital

²Department of Health Promotion and Health Education, National Taiwan Normal University.

Background Stroke is a preventable and treatable disease, by controlling the risk factors we can reduce the incidence of stroke. The World Stroke Day (WSD) proclamation was first initiated in the 4th World Stroke Congress in Vancouver by the World

Stroke Organization (WSO), and was announced in 2006 in the 5th World Stroke Congress in Cape Town in 29 October. The objective of the WSD is to motivate people, health workers, policy makers, governments and aid agencies to take action against stroke. Health literacy is the degree to which individuals have the capacity to obtain, process, and understand basic health information and services needed to make appropriate health decisions. A good stroke literacy including awareness of stroke risk factors, symptoms and treatment, can correctly identified that brain is the organ damaged in stroke, and would have a promptly response (call for emergency service) during stroke attack. With adequate stroke literacy, pre-hospital delayed may be reduced, and increased the opportunity to receive thrombolytic therapy.

Aim

We would like to analysis the basic knowledge of stroke in people attended the WSD Taiwan carnival, to evaluate their level of stroke literacy, and their expectation of the carnival.

Method A short questionnaire was conduction during the WSD Taiwan carnival in October 27, 2012 in the New Taipei County Citizen Plaza by our trained interviewers. Both stroke specialists and public health professions were invited to review the questionnaire.

Results

Total 350 attendances were invited to

have the questionnaire. Only 57.89% attendances could successfully told that the brain was the target-damaged organ in stroke and better (64%) in the post-test. Ischemic stroke (85.94%) was the most common stroke type and hypertension was the most common risk factor recognized by the attendances, followed by hyperlipidemia, over-weight, diabetes, and smoking. Three most common recognized stroke symptoms are limb weakness, slurred speech, facial weakness, and followed by unsteady gait and numbness. Most of the attendances knew that they should seek medical help and call 119 if stroke happened. For the main themes, "Golden hours 123" and "FAST", only 56.16% and 19.76% respectively had heard the slogan before the WSD carnival. Only half of the attendances (50.44%) knew that the thrombolytic therapy is the treatment choice of stroke. 58.06% and 40.32% attendances felt partially and completely matched their expectation respectively. Almost 72% of the attendances would like to join the WSD carnival in 2013. Good stroke literacy if people can correctly: 1. Recognize brain is the target damage organ; 2. Recognize at least 5 stroke risk factors; 3. Recognize more than 5 stroke symptoms, 4. An appropriate response when stroke happened, call 119 immediately¹¹. Around 350 people, only 20 of them had a good stroke

literacy that are mostly women, younger than 65 years old, and received at least high school education.

Conclusion The overall performance of the WSD carnival is barely satisfaction. The main themes of WSD carnival setting were failed to meet the need of the attendance. In the future carnival planning, need assessment should be conducted before the plan. The design of the booths should be based on the result of the survey. Advertisements should be conducted in a more efficient way before the carnival, by the mass medium and Internet. Post-carnival survey should be carried out as a routine process to evaluate the performance of the WSD carnival.

42

急性中風病患的血中玻尿酸濃度與功能性預後的相關性

湯頌君¹ 彭家勛² 胡朝榮³ 邱弘毅⁴ 鄭建興¹

¹台大醫院腦中風中心暨神經部

²三軍總醫院神經部

³台北醫學大學雙和醫院附設神經部

⁴台北醫學大學公共衛生學院

Association of Plasma Levels of Hyaluronic Acid and Functional Outcome in Acute Stroke Patients

Sung-Chun Tang¹, Giia-Sheun Peng², Chaur-Jong Hu³, Hung-Yi Chiou⁴, Jiann-Shing Jeng¹

¹Stroke Center and Department of Neurology, National Taiwan University Hospital, Taipei

²Department of Neurology, Tri-Service General Hospital.

³Department of Neurology, Taipei Medical University-Shuang Ho Hospital, Taipei

⁴School of Public Health, Taipei Medical University, Taipei, Taiwan

Background Delayed inflammatory mechanisms intrinsic to the damaged brain tissue as well as those from the circulating blood are the critical mediators causing cell death, angiogenesis or cell regeneration after stroke. Activation of hyaluronic acid (HA) and associated enzyme synthesis had been shown in experimental studies. In our study, we investigated the plasma levels of HA in acute stroke patients at two different time points as <48 hours (h) and 48-72 h after stroke onset and their associations with functional outcome.

Subject and method This is a multi-centre study. Patients with acute stroke and age and sex matched controlled subjects were recruited. Clinical information including stroke subtypes, and 3 months functional outcome, defined as modified Rankin scale (mRS), was collected. Plasma levels of HA were determined via standard ELISA method.

Results There were 159 non-stroke controls and 206 stroke patients including 43 intracerebral hemorrhage (ICH) and 163 ischemic stroke patients (IS). The plasma levels of HA (log transformed) were 4.84 ± 0.75 , 5.10 ± 0.72 , and 5.17 ± 0.97 ng/ml in controls, <48h and 48-72h after stroke, respectively ($p < 0.001$ and 0.01 between controls and strokes). In ICH patients, multivariate analysis

suggested that HA levels (<48h) exceeded 500 ng/ml was independent poor outcome predictor (odds ratio=44.151, 95% CI: 3.6 to 1444.346; p=0.01). In IS patients, although levels of HA failed to be an independent outcome parameter, further analysis using a generalized additive model identified a diverse associations between the plasma levels of log HA (48-72h) and outcome after adjustment of independent clinical parameters, that IS patients with high (>6.12) or low (<4.55) all tend to have poor functional outcome.

Conclusion Plasma levels of HA may increase after the onset of stroke and levels of HA within 48h after stroke onset may help in predicting functional outcome in ICH patients.

43

利用緊急醫療系統可以有效增加急性缺血性腦中風病患接受血栓溶解治療的比例

黃光雨¹ 謝明儒² 湯頌君¹ 蔡力凱¹ 馬惠明² 鄭建興¹

¹臺大醫院神經部 ²臺大醫院急診醫學部

Utilization of Emergency Medical Service Increases Chance of Thrombolytic Therapy in Patients with Acute Ischemic Stroke

¹Kuang-Yu Huang, ²Ming-Ju Hsieh, ¹Sung-Chun Tang, ¹Li-Kai Tsai, ²Matthew Huei-Ming Ma, ¹Jiann-Shing Jeng

¹Department of Neurology, National Taiwan University Hospital

²Department of Emergency Medicine, National Taiwan University Hospital

Object The aim of this study was to determine whether utilization of

emergency medical service (EMS) could increase use and expedite delivery of the thrombolytic therapy in acute ischemic stroke patients.

Background Thrombolytic therapy can only be administered in patients whose stroke onset within 3-4.5 hours. In addition, it has been shown that the sooner that thrombolytic therapy is given to stroke patients, the better the functional outcome.

Methods We analyzed consecutive patients presenting to the emergency department (ED) with an ischemic stroke within 72 hours of symptom onset from a prospective stroke registry in a tertiary medical center. Variables associated with early ED arrival (within 3 hours of stroke onset), and administration of intravenous thrombolytic therapy were analyzed with multivariate logistic regression and linear regression models.

Results During the study period from January 1, 2010 to July 31, 2011, a total of 1764 patients were collected in the registry. Patients were excluded if they were diagnosed as intracerebral hemorrhage, subarachnoid hemorrhage, transient ischemic attack or cerebral venous thrombosis (n=428), onset-to-ED time > 72 h (n=247), and in-hospital stroke (n=8). Finally, 1081 patients (62.3% men, age 69.6 ± 13 years) were included in this study.

Among them, 289 (26.7%) arrived in the ED within 3 hours, and 88 (8.1%) received thrombolytic therapy. Patients who arrived to the ED by EMS (n=279, 25.8 %) were independently associated with earlier ED arrival (adjusted odds ratio [OR] = 3.68, 95% confidence interval [CI] = 2.54 to 5.33), and higher chance of receiving thrombolytic therapy (adjusted OR = 3.89, 95% CI= 1.86 to 8.17). Furthermore, utilization of EMS significantly decreased onset-to-needle time by 26 minutes in patients receiving thrombolytic therapy.

Conclusions Utilization of EMS can not only help acute ischemic stroke patients in early presentation to ED, but also effectively facilitate thrombolytic therapy and shorten the onset-to-needle time. Our data highly strengthen the importance of EMS activation in acute stroke management.

44

高密度膽固醇影響粥狀動脈硬化性中風的預後

葉珀秀¹ 楊浚銘¹ 林聖翔² 王偉銘² 林慧娟¹
林高章¹ 張嘉祐¹ 鄭天浚¹ 李貽恆³

¹奇美醫院神經內科

²成大醫院臨床醫學研究所

³成大醫院內科部

Low level of high-density lipoprotein cholesterol in patients with atherosclerotic stroke

Poh-Shiow Yeh¹, Chun-Ming Yang¹,
Sheng-Hsiang Lin², Wei-Ming Wang², Huey-Juan
Lin¹, Kao-Chang Lin¹, Chia-Yu Chang¹,
Tain-Junn Cheng¹, Yi-Heng Li³

¹Department of Neurology, Chi-Mei Medical
Center, Tainan, Taiwan

²Department of Internal Medicine

³Institute of Clinical Medicine, National Cheng

Kung University College of Medicine and
Hospital, Tainan, Taiwan

Background and Purpose Lower high-density lipoprotein cholesterol (HDL-C) level has been reported to be associated with atherosclerotic stroke. In acute stage of stroke, HDL-C has been shown to be a neuroprotective agent and decreases stroke severity in animal experiments. We performed a prospective cohort study to evaluate the influence of baseline HDL-C on initial stroke severity and 6-month prognosis.

Methods From August 2006 through December 2011, acute stroke patients fulfilling the following criteria were recruited for the present study: (1) age 18 years or older (2) no lipid-lowering drugs use prior to admission, and (3) ischemic stroke or transient ischemic attack (TIA) due to large artery atherosclerosis and small vessel occlusion. Total cholesterol, triglyceride, low-density lipoprotein cholesterol (LDL-C) and HDL-C were checked and National Institutes of Health Stroke Scale (NIHSS) score were obtained at admission. The primary outcomes were a composite end point of all-cause mortality, recurrent stroke, or occurrence of ischemic heart disease at 6-month follow up. Results: During the study period, 3,093 subjects (mean age 67 yrs; male 62%) with ischemic stroke or TIA were qualified for this study.

Among them, 675 patients (22%) had HDL-C \leq 35 mg/dL at admission. At admission, the patients with low HDL-C had higher NIHSS score (low vs normal HDL-C: 6.4 ± 7.1 vs 5.3 ± 6.1 , $p < 0.001$). After adjusting for all clinical factors in multivariate logistic analysis, we found low HDL-C at admission (OR, 1.79, 95% CI, 1.40-2.29) was significantly associated with higher stroke severity (NIHSS score > 6). During the follow-up, 280 patients (9%) had developed one of the components of the composite end point, including 76 (11.3%) in patients with low HDL-C and 204 (8.4%) in patients with normal HDL-C at admission ($p < 0.001$). The Kaplan-Meier analysis showed a significantly worse clinical outcome in patients with low HDL-C (Log-rank test, $p = 0.017$). In multivariate Cox regression analysis, after adjusting for all clinical factors, low HDL-C at admission (HR, 1.41, 95% CI, 1.02-1.95) was a significant independent predictor of the composite end point at 6-month follow up. The patients with low HDL-C were divided into 2 groups: isolated low HDL-C (HDL \leq 35 mg/dL and LDL $<$ 160 mg/dL and triglyceride $<$ 200mg/dL), and non-isolated low HDL-C (HDL \leq 35 mg/dL combined with LDL \geq 160 mg/dL and/or triglyceride $>$ 200mg/dL). During follow-up, composite end point occurred in 53 (12%) patients with isolated low HDL-C group and 23 patients (9.8%) in non-isolated low HDL-C group ($p = 0.392$).

Conclusion Baseline low HDL-C (\leq 35 mg/dL) at admission is associated with higher initial stroke severity and is an independent prognostic indicator at 6-month follow up. Although isolated low HDL-C is associated with the risk of composite end point as the non-isolated low HDL, this lipid phenotype was significantly less treated.

45

以臺灣腦中風登錄資料分析慢性腎疾病對急性大血管阻塞性腦中風預後之影響

葉馨喬¹ 湯頌君¹ 蔡力凱¹ 鄭建興¹

臺灣腦中風登錄團隊

¹ 臺大醫院神經部暨腦中風中心

The Impact of Chronic Kidney Disease on the Outcome of Large Artery Atherosclerotic Stroke: Results from Taiwan Stroke Registry Shin-Joe Yeh¹, MD; Sung-Chun Tang¹, MD; Li-Kai Tsai¹, MD, PhD; Jiann-Shing Jeng¹, MD, PhD; and Taiwan Stroke Registry Investigators

¹ Stroke Center and Department of Neurology, National Taiwan University Hospital and National Taiwan University College of Medicine, Taipei, Taiwan

Objective To investigate the impact of chronic kidney disease (CKD) on the outcome of acute ischemic stroke with large artery atherosclerosis (LAA)

Background and Purpose CKD has been shown a risk factor for the development of LAA and stroke. However, the impact of CKD on the outcome of acute stroke patients with LAA has not been well documented.

Methods Patients who were prospectively registered in Taiwan Stroke Registry (TSR) and had LAA subtype of acute ischemic stroke were included. The severity of renal function impairment was evaluated by estimated glomerular filtration rate (eGFR) as normal (≥ 90 mL/min/1.73 m²), mild (60-89 mL/min/1.73 m²), moderate (30-59 mL/min/1.73 m²), and severe (< 30 mL/min/1.73 m²) renal function impairment. CKD was defined as eGFR < 60 mL/min/1.73 m². The association of renal function with acute stroke severity was analyzed. Logistic regression analysis, Kaplan-Meier method and Cox proportional hazard model were applied to assess factors determining the outcome, recurrent stroke and death at 6 months after stroke.

Results Between May, 2006 and April, 2009, there were 7728 patients (male, 61.8%; average age, 68.6 years) with LAA subtype of ischemic stroke. Acute stroke severity (represented as initial NIHSS scores) was correlated significantly with moderate and severe CKD ($P=0.026$ and < 0.0001 , respectively). Severe renal impairment was a major determinant for worse functional outcome (adjusted odds ratio, 1.39; 95% confidence intervals, 1.06 to 1.83). Patients with moderate (adjusted hazard ratio, 2.62; 95% confidence interval, 1.18-5.83) and severe (adjusted hazard ratio, 5.48; 95% confidence interval, 2.39-12.56) CKD had higher

mortality at 6 months after stroke. Patients with mild renal impairment had significantly higher risk of recurrent stroke within 6 months after stroke (adjusted hazard ratio, 1.68; 95% confidence interval, 1.02-2.78).

Conclusions In patients with LAA subtype of acute ischemic stroke, renal function at admission is crucial for prediction of long-term functional outcome, mortality, and recurrent stroke.

46

胰臟癌與腦中風之風險：以台灣人口為基礎的世代研究

詹博棋 紀心怡 徐敏獻 張偉倫 葉宗勳
秀傳醫療社團法人秀傳紀念醫院 神經內科

Pancreatic Cancer and Risk of Stroke: A Population-Based Cohort Study

Po-Chi Chan, Shin-Yi Jih, Min-Hsien Hsu,
Wei-Lun Chang, Chung-Hsin Yeh
Department of Neurology, Show Chwan
Memorial Hospital

Background Cerebrovascular disease occurs commonly in cancer patients. However, literature on risk of stroke in patients with pancreatic cancer is sparse. This study aims to investigate the risk of stroke in pancreatic cancer patients using a nationwide, population-based database in Taiwan.

Methods For the study cohort, we identified 7,116 patients newly diagnosed with pancreatic cancer in 2000-2007 from the Taiwan National Health Insurance Research Database. For the comparison cohort, 28,464

subjects without pancreatic cancer matched in terms of sex, age, and the index year were randomly extracted from the same dataset. Events of stroke from 2000-2009 were ascertained from medical claims (International Classification of Disease, Ninth Revision, Clinical Modification, ICD-9-CM, codes 430-438). Stratified Cox proportional hazard regression was performed on the two cohorts to compare the risk of stroke during follow-up period.

Results The incidence of stroke was higher in patients with pancreatic cancer, as compared to the noncancer group (32.43 vs. 16.83 per 10,000 person-years) during the follow-up period. After the stratified Cox proportional analysis for patients' demographic characteristics and comorbidities, overall risk of ischemic stroke and hemorrhagic stroke during the follow-up period after diagnosis of pancreatic cancer was 2.07 (95% confidence interval (CI) = 1.77-2.42) and 1.88 (CI = 1.22-2.90), respectively.

Conclusion Pancreatic cancer is associated with an increased risk of subsequent ischemic and hemorrhagic stroke.

47

中風病人表現之 Mirror movement- 個案報告與文獻回顧

廖岐禮 徐榮隆 葉建宏 邱浩彰
新光醫院神經內科

Mirror movement in a patient with stroke - A Case Report and Literature

Review

Chi-Li Liao, Jung-Lung Hsu, Jiann-Horng Yeh,
Hou-Chang Chiu
The Department of Neurology, Shin-Kong Wu
Ho-Su Memorial Hospital, Taipei

Background Mirror movement is an involuntary, synkinetic mirror reversals of an intended movement of opposite side. Erlenmeyer first used this term in 1879. We reported a 74 year-old woman who had an embolic infarct in the right MCA territory with the mirror movement

Case Report This 74 year-old woman had a history of HTN and SLE. She was just admitted on 03/19 due to the generalized weakness and poor verbal output for 5 minutes at home. Pneumonia, pancytopenia, SLE encephalopathy was initial diagnosed. She was discharged on 04/03 with prednisolone 4# BID for SLE. Two days later, her daughter found that she became easily choking, slurred speech, and slow response at dinner. She still could walk by herself. However, she started to have left side weakness with dysphagia and dysarthria since on 04/06 afternoon. No dizziness, no diplopia, no drop attack, no lost of consciousness. She was sent to our ER where E4V5M6, T/P/R: 36.2/ 92bpm/ 14rpm, Bp: 174/98mmHg. Dysphagia(+), Dysarthria(+), left hemiparesis(MP:4+/4+). Brain CT revealed no hemorrhage but right parieto-occipital hypodense and left basal ganglion lacunar infarct noted.

ECD reported no obvious stenosis, but TCD disclosed bilateral MCA occlusion. Under the impression of MCA-PCA stenosis, she was admitted for treatment. During admission, mirror movement was noted (synchronous movement of right hand and mouth when patient squeezed her left hand). Brain MRI showed right MCA territory multifocal infarct, and embolic stroke was suspected. Both cardiac echo and TEE (due to no finding in heart echo) reported no emboli noted. After discussed with family, we kept antiplatelet medication usage. We arranged rehabilitation for her when no stroke in evolution noted, and now dysarthria and dysphagia improved. MP(4+/4+). She could stand without titubation, and walk without assistance. Mirror movement also improved (not totally subsided). She discharged on April 18 with OPD follow-up.

Conclusion Mirror movements are the soft neurological signs that are rarely encountered in routine clinical practice and are bound to be missed if not specifically sought for. This patient represented mirror movement in the beginning of stroke, and improved gradually.

48

利用磁敏感加權成像預測惡性中大腦動脈梗塞病患的死亡率

趙書屏¹ 陳家媛² 蔡芳洋³ 陳榮邦² 陳晉誼¹

¹ 臺北醫學大學

² 萬芳醫院神經科放射科

³ 臺北醫學大學影像研究中心

Predicting Mortality in Malignant Middle Cerebral Artery Infarction patients by using Susceptibility-Weighted MR imaging

Shu P. Chao¹, Chia Y. Chen², Fong Y. Tsai³, Wing P. Chan², Chin- I Chen¹

¹ Department of Neurology, ² Radiology, Wan Fang Hospital, ³ Taipei Medical University Medical Imaging Research Center, Taipei Medical University

Objectives Malignant middle cerebral artery (MCA) infarctions are defined as hypodensity in more than 50-75% of the MCA territory on the computer tomography and have been associated with high mortality rate.

Susceptibility-weighted imaging (SWI) can depict deoxyhemoglobin (deoxy-Hb) and has been shown to predict stroke evolution. We use SWI and DWI to evaluate malignant MCA infarction patients and correlate the images to the clinical outcome.

Methods We retrospectively analyzed large MCA infarction patients who were admitted to Wanfang hospital during past three years. MRIs were reviewed by one neurologist and one radiologist respectively. We used the Alberta Stroke Program Early CT Score (ASPECTS) to evaluate patients' diffusion - weighted imaging (DWI) and SWI lesions obtained within 7 days after stroke.

Results Sixteen malignant MCA infarction patients are enrolled into this study and divided into mortality (n=6) and survival group (n=10). The

patients' clinical profiles and stroke risk factors are documented ($p > 0.1$). Although the DWI-ASPECTS and clinical profiles are similar in both groups, the SWI-ASPECTS in mortality group are significantly lower than that in survival group ($p < 0.001$).

Conclusions The extent of de-oxygenation area showed by SWI in malignant MCA infarction patients can predict mortality. Lower SWI-ASPETS is potentially better parameter than DWI-ASPECTS to predict poor outcome. Further prospective study and more cases are needed to clarify the role of SWI and guiding intervention therapy.

49

針刺治療對急性缺血性腦中風患者腦血流速度的影響

劉競雄 曾弘斌 林俊良 林鴻志
羅東博愛醫院 神經內科

The Effects of Acupuncture Therapy on the Cerebral Blood Flow Velocities of Acute Ischemic Stroke Patients

Ching-Hsiung Liu, Hung-Pin Tseng, Chun-Liang Lin, Hung-Chin Lin
Department of Neurology, Lotung Poh-Ai Hospital, Ilan, Taiwan.

Objectives Acupuncture in traditional Chinese medicine has been verified in many disease by thousands yeas. The acupuncture therapy applied in post stroke functional recovery has been considered as more benefit than physical therapy only to post stroke rehabilitation.. However, the effect and mechanism of acupuncture therapy in acute ischemic stroke patient still remains uncertain. The

aim of the present study would observe the dynamics changes in cerebral blood flow of acute ischemic stroke patients treated before and after acupuncture therapy.

Methods we collect newly onset of acute ischemic stroke patient without underling systemic major illness, and randomized assign the collected patients into two groups as acupuncture group and normal control group. Both group all treat with routine western medicine as standard stroke therapy. The methods of acupuncture performed by Jin's 3- needle technique (靳三針) with 'The 3-arm Points: Quchi (LI 11), Waiguan (TE 5), Hegu (LI 4)' and 'The 3-Leg Points: Zusanli (ST 36), Sanyinjiao (SP 6), Taichong (LR 3)', 'Three temporal points' and 'Four Spirit points' by 'uniform reinforcing-reducing method'. The therapeutic course of acupuncture in theses patients performed once daily for ten days. The blood flow velocity and other parameters were measured in bilateral internal carotid artery (ICA) and middle cerebral artery (MCA) before and after acupuncture treatment.

Results Total 34 patients were included in the study. 17 case for acupuncture group and 17 case for control group. The acupuncture group did not approach significant difference in all parameter of ICA and MCA in sonographic studies. However, after

sub-grouping the cases, the right ICA 's pulsatility index (PI) and resistance index (RI) decreased significantly in acupuncture group with the infarction area of the left side.

Conclusions Acupuncture therapy may decreased the PI and RI of ICA contra-lateral to infarction side in acute stroke patients. The results could be explain the possibly mechanism of acupuncture effect on cerebral blood flow which increasing the collateral arterial flow in acute stroke stage.

50

Valproate 透過降低 BBB 破壞和增進血管新生而促進腦梗塞大鼠的功能性恢復

蔡力凱^{1,2} 王志菲² 冷豔² Peter Leeds² 莊德茂²

¹ 台大醫院神經部暨腦中風中心

² 美國國家衛生院 NIMH

Valproate Attenuates BBB Disruption, Enhances Angiogenesis, and Promotes Functional Recovery in a Rat Model of Ischemic Stroke

Li-Kai Tsai, MD, PhD¹, Zhifei Wang, PhD², Yan Leng, MD², Peter Leeds², De-Maw Chuang, PhD²

¹ Department of Neurology, NTUH

² NIMH, National Institutes of Health, MD, USA

Objective To investigate the therapeutic mechanisms of valproate (VPA) in cerebral infarct.

Background Blood-Brain barrier (BBB) disruption after stroke results in brain edema and deteriorates the neurological condition. Enhanced angiogenesis facilitates neurovascular remodeling and

promotes functional recovery after stroke. Valproate (VPA), a histone deacetylase (HDAC) inhibitor, is known to protect against cerebral ischemia; however, its effects on BBB protection and angiogenesis are still unknown.

Methods Male rats underwent middle cerebral artery occlusion (MCAO) for 60 minutes followed by reperfusion. VPA (200 mg/kg, intraperitoneally) was administrated once daily for 14 days. Assessed parameters included the Rotarod test, T2/perfusion-weighted MRI, Evans blue extravasation analysis, Western blotting, immunohistochemistry, and gelatin zymography.

Results Postischemic VPA treatment improved the Rotarod performance and reduced infarct area in MCAO rats on Days 7 and 14 after ischemia. VPA treatment attenuated MCAO-induced BBB disruption and brain edema 24 hours after stroke. Meanwhile, VPA reduced MCAO-induced elevation of MMP-9 and degradation of tight junction proteins. In addition, VPA enhanced microvessel density, facilitated endothelial cell proliferation, and increased cerebral blood flow in the ipsilateral cortex on Day 14. The hypoxia-inducible factor-1 α (HIF-1 α) and its downstream proangiogenic factors, VEGF and MMP-2/9, were upregulated after MCAO and

potentiated by VPA. The beneficial effects of VPA were abolished by HIF-1 α inhibition.

Conclusion VPA treatment attenuates BBB disruption, enhances angiogenesis, and promotes functional recovery after brain ischemia. These effects may involve suppression of MMP-9 (early) and upregulation of HIF-1 α and its downstream proangiogenic factors (late).

51

眼動脈逆流於內頸動脈狹窄患者之臨床運用

蔡佳霖¹ 李俊泰¹ 陳俊安¹ 劉孟達² 陳震宇³
胡漢華⁴ 彭家勳¹

¹三軍總醫院神經內科

²國軍花蓮總醫院內科

³三軍總醫院放射科

⁴台北榮民總醫院神經內科

Clinical implications of reversal of ophthalmic artery flow in patients with unilateral severe carotid stenosis

Chia-Lin Tsai¹, Jiunn-Tay Lee¹, Chun-An Cheng¹,
Meng-Ta Liu², Cheng-Yu Chen³,
Han-Hwa Hu⁴, Giia-Sheun Peng¹
Departments of ¹Neurology and ³Radiology,
Tri-Service General Hospital, National
Defense Medical Center, Taipei; ²Department of
Internal Medicine, Hualien Armed Forces
General Hospital, Hualien, and ⁴Department of
Neurology, Taipei Veterans General Hospital,
Taipei, Taiwan

Objective High-grade cervical carotid stenosis (70–99%) or occlusion often accompanies the occurrence of reversed ophthalmic artery flow (ROAF), but its clinical implications in patients remain uncertain. The purpose of the present study was to assess ROAF and the related variables caused by carotid

hemodynamic compromise in patients with unilateral severe cervical carotid stenosis.

Methods A total of 200 patients with unilateral high-grade cervical carotid stenosis/occlusion were diagnosed by color-coded duplex ultrasonography. Of the 152 patients with unilateral high-grade cervical carotid stenosis were divided into 2 groups, according to the presence or absence of ROAF, to compare their hemodynamic parameters. Out of 200 patients, 159 underwent brain magnetic resonance imaging and were analyzed for risk factors impacting functional outcomes including ROAF.

Results Of the initial 200 patients, 152 (76.0%) were diagnosed with high-grade carotid stenosis and 48 (24.0%) with occlusion; ROAF was observed in 68 (34.0%) patients. Patients with ICA occlusion had significantly higher percentage of ROAF compared to patients with high-grade stenosis (44.1% vs. 13.6%, $p < 0.001$). In the ROAF group, there were significant differences in all the hemodynamics parameters of retrobulbar arteries between stenotic and non-stenotic vessels. The patients ($n = 159$) with history of stroke ($P = 0.035$), ROAF ($P = 0.023$) and intracranial stenosis ($P < 0.001$) exhibited significantly higher incidence of poor functional outcome

compared with the corresponding control groups. Multivariate analysis revealed that patients with cervical and intracranial stenosis in combination had a seven-fold (OR: 7.60, 95% CI: 3.44–16.81) higher risk for the presence of ROAF.

Conclusion ROAF may result from intracranial hemodynamic compromise. Patients with unilateral high-grade cervical carotid stenosis/occlusion in combination with intracranial stenosis appear to be a significant risk factor for poor functional outcome and increased incidence of ROAF.

52

台灣的孤立性皮質靜脈血栓研究：3 例臨床報告

鄭又禎¹ 李少白¹ 賴資賢^{1,2}

¹亞東紀念醫院神經內科

²國立陽明大學醫學院

Isolated cortical vein thrombosis in Taiwan: a 3 cases series

Yu-Chen Cheng¹, Siupak Lee¹, Tzu-Hsien Lai^{1,2}

¹Department of Neurology, Far Eastern Memorial Hospital

²National Yang-Ming University School of Medicine

Background Isolated cortical vein thrombosis (ICVT) without sinus involvement is uncommon and difficult to diagnose. Our aim is to investigate the clinical characteristics and neuroradiologic findings in patients with isolated cortical vein thrombosis in Taiwan.

Methods We retrospectively reviewed the medical records of all 3 patients discharged from Far Eastern Memorial Hospital with a diagnosis of isolated cortical vein thrombosis from January 2010 to December 2012. Brain magnetic resonance imaging (MRI) and angiography were performed in all patients. We evaluated their treatment and outcomes.

Results Three female patients (mean age 35 years; range, 30-40 years) were included. All presented with focal neurologic deficits. Headache was noted in two of three patients. None of the patients have seizure attacks. Brain MRI demonstrates parenchymal hyperintensities involving the cortical-subcortical regions around the ICVT on T2-weighted/FLAIR images. Angiography showed isolated cortical vein thrombosis without sinus involvement. Two of the patients received anticoagulant treatment while the other received antiplatelet treatment. Clinical outcomes were uniformly good, despite variable treatment strategies.

Conclusion The results of our study show that there are distinct clinical characteristics and neuroradiologic findings in isolated cortical vein thrombosis from those findings in venous sinus thrombosis. The outcome of the patients was good and the treatment options are discussed.

以中風醫療品質突破系列活動提升急性缺血性中風醫療品質

鄭建興¹ 連立明² 邱弘毅³ 邱浩彰²
中風醫療品質突破系列研究群

¹臺大醫院神經部

²新光醫院神經科 台北醫學大學公衛學院

Quality Improvement in Acute Ischemic Stroke Care Through the Breakthrough Series - Stroke

Jiann-Shing Jeng¹, Li-Ming Lien², Hung-Yi Chiu³, Hou-Chang Chiu², on behalf of the BTS-Stroke Investigators

¹Department of Neurology, National Taiwan University Hospital,

²Department of Neurology, Shin Kong WHS Memorial Hospital,

³School of Public Health, Taipei Medical University, Taipei, Taiwan

Background and Purpose Guideline adherence for acute ischemic stroke (AIS) management is often suboptimal, particularly in thrombolytic therapy and anticoagulants for atrial fibrillation. We sought to achieve quality improvement of AIS patients via a collaborative learning model, the Breakthrough Series (BTS)-Stroke, in a nationwide, multi-center activity in Taiwan.

Methods A BTS Collaborative, a short-term learning system for a large number of multidisciplinary teams from hospitals, was applied to enhance AIS care quality. There were 24 teaching and community hospitals participating in and submitting data for this stroke quality improvement campaign from August 2010 to June 2011. The Get With The Guideline (GWTG)-Stroke measures were adopted to evaluate the performance and outcome of the AIS

patients. The results of this study were compared to those of the previous Taiwan Stroke Registry (TSR, 22642 AIS patients from 39 hospitals, 2006-08).

Results Data from 24 hospitals with 13181 AIS patients during a 1-year period were analyzed. The BTS-Stroke (2010-11) had better performance as compared to the TSR (2006-08): intravenous thrombolysis frequency for all AIS patients (4.1% vs 1.5%), symptomatic hemorrhage after intravenous thrombolysis (6.0% vs 8.2%), early antithrombotics (96.6% vs 94.1%), anticoagulation for atrial fibrillation (57.1% vs 28.3%), lipid lowering drugs for low-density lipoprotein >100 mg/dL (63.4% vs 38.7%), antithrombotics at discharge (94.0% vs 85.5%), and one-month mortality (3.5% vs 4.0%). Temporal improvement was noted in 7 of 14 performance measures when the fourth BTS-Stroke quarter compared with the first quarter: intravenous thrombolysis frequency for all AIS patients (4.1% vs 3.7%), symptomatic hemorrhage after intravenous thrombolysis (3.4% vs 5.5%), lipid lowering drugs for low-density lipoprotein >100 mg/dL (67.3% vs 60.5%), antithrombotics at discharge (95.5% vs 91.4%), dysphagia screening (81.9% vs 63.4%), early rehabilitation (71.7% vs 63.6%), stroke education before discharge (95.6% vs 83.4%).

Conclusions A BTS collaborative learning and campaign model can improve the guideline adherence of stroke. The GWTG-Stroke can be successfully applied to other countries outside the United States.

54

以併發高血壓性腦幹病變及後部缺血性視神經病變之高血壓危象：個案報告
賴星融 湯頌君 鄭建興
台灣大學附設醫院神經部

Hypertensive emergency presents with hypertensive brainstem encephalopathy and posterior ischemic optic neuropathy: a case report

Hsing-Jung Lai, Sung-Chun Tang, Jiann-Shing Jeng
Department of Neurology, National Taiwan University Hospital, Taipei, Taiwan

Introduction Hypertensive emergency (HE) represents acute impairment of one or more organ systems related to uncontrolled hypertension, but concurrent involvement of central and peripheral nervous systems has not been reported. Here we reported a case with HE, suffering from reversible brainstem encephalopathy and unilateral posterior ischemic optic neuropathy (PION).

Case report A 32-year-old man visited our emergency room with high blood pressure (226/160mmHg), left monocular visual loss, right temporal visual loss and mild left upper limb weakness. Brain CT showed unilateral right midbrain and bilateral pontine hypodensity. Brain MRI showed increased apparent diffusion coefficient

in the above area. Fundus exam and fluoroangiogram did not show obvious arterial occlusion or disc abnormality. The flash visual evoked potential was absent in the left eye. After rapid normalization of blood pressure, right visual field defect and limb weakness improved significantly, but a permanent visual loss persisted after three months.

Conclusion Our case demonstrated a rare presentation of coexistent hypertensive brainstem encephalopathy and ischemic optic neuropathy in HE.

55

探討急診進行靜脈血栓溶解治療病患的美國國家衛生研究院中風量表各項分數分佈

謝函潔¹ 宋昇峯² 林慧娟³ 陳右緯⁴ 曾美君⁵ 陳志弘⁶

¹ 國立成功大學附設醫院斗六分院 內科部 神經內科

² 戴德森醫療財團法人嘉義基督教醫院 內科部 神經內科

³ 奇美醫院 神經內科

⁴ 壠新醫院 神經內科

⁵ 壠新醫院 資深研究員

⁶ 國立成功大學附設醫院 神經部

The Distribution of the Items of National Institutes of Health Stroke Scale (NIHSS) in Patients Receiving Intravenous Thrombolytic Therapy at Emergency Department

¹Han-Chieh Hsieh, ²Sheng-Feng Sung, ³Huey-Juan Lin, ⁴Yu-Wei Chen, ⁵Mei-Chiun Tseng, ⁶Chih-Hung Chen

¹ Division of Neurology, Department of Internal Medicine, Dou-Liou Branch, National Cheng Kung University Hospital

² Division of Neurology, Department of Internal Medicine, Chia-Yi Christian Hospital

³ Department of Neurology, Chi-Mei Medical Center

⁴ Department of Neurology, Landseed Hospital

⁵ Senior researcher, Landseed Hospital

⁶ Department of Neurology, National Cheng Kung University Hospital

Background and purpose Stroke code facilitates early recognition of stroke and speeds up the assessment. To accelerate the evaluation currently performed by triage personnel, a rapid and simple protocol for detecting stroke symptoms/signs is valuable. We aimed to determine the most sensitive sign(s) among the items of NIHSS that could be used to identify patients most likely to be eligible for thrombolysis.

Methods Data were retrospectively collected from January 2007 to June 2012 in four Stroke Centers (National Cheng Kung University Hospital, Chi-Mei Medical Center, Chia-Yi Christian Hospital, and Landseed Hospital). We explored the most critically relevant items from NIHSS in patients receiving intravenous tissue plasminogen activator (tPA) at emergency department (ED).

Results A total of 627 patients received tPA at ED, with a baseline median NIHSS score of 13 (interquartile range 8 to 19). The most common single abnormal NIHSS item is facial weakness (88.2%). If we added the items of motor weakness (5aL+5bR+6aL+6bR) together, the most prominent sign was motor weakness in at least one extremity (scored ≥ 1 point in the subtotal of motor category) (95.1%). After taking facial

weakness into consideration, the percentage rose to 97.8%.

Conclusions Motor weakness of any extremity is the most common sign in patients receiving intravenous thrombolytic therapy at ED. The high sensitivity is sufficient to identify most candidates for thrombolytic therapy for the first step of triage. The present triage protocol for acute stroke identification at ED may be simplified accordingly.

56

醫院與緊急醫療系統的合作計畫提升急性中風照護

謝明儒¹ 湯頌君² 蔡力凱² 黃光雨² 馬惠明¹
鄭建興²
臺大醫院¹ 急診醫學部² 神經部

Hospital and Emergency Medical Service Cooperation Program Enhances Acute Stroke Care

Ming-Ju Hsieh¹, Sung-Chun Tang², Li-Kai Tsai², Kuang-Yu Huang², Matthew Huei-Ming Ma¹, Jiann-Shing Jeng²
Departments of¹Emergency Medicine and²Neurology, National Taiwan University Hospital

Background The importance of emergency medical service (EMS) on hyperacute stroke care has been emphasized by the guidelines of American Stroke Association because utilization of EMS can improve both pre-hospital and in-hospital delays. Nevertheless, a close cooperation between hospitals and EMS for stroke patient care had not been well established in Taiwan until recent years. This study aimed to assess the impact

of the cooperation program on acute stroke care.

Methods From December, 2010 to February, 2011, emergency medical technicians (EMTs) in the catchment area of NTUH were educated to identify stroke patients with symptoms onset less than 3 hours by using Cincinnati Prehospital Stroke Scale and to perform prehospital notification if such patients were identified. Since March, 2011 to November, 2012, each prenotified acute stroke patient's characteristics and diagnosis was recorded. We also reviewed acute stroke patients during January, 2010 and February, 2011 for historical comparison.

Results Regarding the clinical performance of prenotification by EMTs, the positive predictive value was 78.7% (196/249) and the sensitivity was 59.4% (196/330). Seizure (35.8%) and onset time >3 hours (26.4%) were the two most common conditions leading to incorrect prenotification. Among all prenotified patients, 21.3% (53/249) received thrombolytic therapy. Hemorrhagic stroke / ischemic stroke with hemorrhagic transformation (40.3%) and minor symptom (NIHSS<4) / rapid recovery (17.3%) were the two most common reasons for no thrombolytic therapy in the prenotified stroke patients arriving within 3 hours. After the cooperation program, the percentage of patients arriving at ED within 3 hours of

onset among patients with acute stroke and transient ischemic attack was elevated significantly from 22.3% to 25.5% (rate ratio, 1.14; 95% confidence interval, 1.01 to 1.29; $P=0.031$); the percentage of patients receiving thrombolytic therapy among acute ischemic stroke patients increased significantly from 5.8% to 8.1% (rate ratio, 1.39; 95% confidence interval, 1.01 to 1.92; $P=0.043$).

Conclusions Through the cooperation program, the EMTs can make correct identification and prenotification of acute stroke. The frequency of thrombolysis in acute ischemic stroke improved significantly.

57

預測急性缺血性腦中風病患接受血栓溶解治療之後腦內出血與院內死亡的因子：一個為期8年的全國性調查

謝鎮陽^{1,2} 陳志弘³ 楊高雅慧²

¹ 台南新樓醫院腦中風中心暨神經內科

² 國立成功大學臨床藥學與藥物科技研究所

³ 國立成功大學附設醫院腦中風中心暨神經部

Factors Predicting Intracerebral Hemorrhage and In-hospital Mortality after Thrombolytic Therapy for Acute Ischemic Stroke Patients: a 8-year Nationwide Survey

Cheng-Yang Hsieh^{1,2}, Chih-Hung Chen³,
Yea-Huei Kao Yang²

¹ Stroke Center and Department of Neurology,
Tainan Sin Lau Hospital

² Institute of Clinical Pharmacy and
Pharmaceutical Sciences, National Cheng
Kung University, Tainan, Taiwan

³ Stroke Center and Department of Neurology,
National Cheng Kung University Hospital,
Tainan, Taiwan

Objective To analyze factors predicting intracerebral hemorrhage (ICH) and in-hospital mortality after thrombolytic therapy for Taiwanese acute ischemic stroke (AIS) patients using a nationwide dataset.

Background Recombinant tissue plasminogen activator (rtPA) is the only effective treatment for AIS. However, debate has been raised when regulators used hospital accreditation to implement rtPA across the nation. The hypothesis we want to test is that the experience of thrombolytic therapy of each hospital has an inverse relationship with complications after rtPA.

Methods We identified all hospitalized AIS patients receiving rtPA in the whole-population National Health Insurance Research Database, 2003-2010. The outcome of interest included ICH and in-hospital mortality after rtPA for each AIS admission. In addition to total rtPA experience of each hospital, the following factors were adjusted in the multiple regression models including age, sex, co-morbidities of the patients (i.e. Charlson co-morbidity index), weekend admission or not, and physician's specialty.

Results We identified a total of 2,742 AIS patients with thrombolytic therapy, accounting for 0.68% of all AIS hospitalized patients during 2003-2010. The rates of ICH and in-hospital

mortality are 3.96% and 9.18%, respectively. After adjusting for age, sex, co-morbidities, weekend admission, and physician's specialty, we found ICH was significantly associated with an increase of in-hospital mortality (adjusted odds ratio [OR]: 5.288; 95% confidence interval [CI]: 3.167-8.831), while rtPA experience of each hospital was associated with a decrease of ICH (adjusted OR: 0.992, 95% CI: 0.986-0.998) for patients receiving rtPA.

Conclusion The maxim "practice makes perfect" may be also applicable in stroke thrombolysis. Our results provide evidence regarding the urgent need to integrate the emergency medical service and centralize hospitals providing thrombolytic therapy for AIS patients in Taiwan.

58

降血壓處置延遲血栓溶解劑治療及其結果

簡崇曜 宋碧姍

國立成功大學醫學院附設醫院 神經部暨中風中心

Antihypertensive Therapy Before Thrombolysis

Chung- Yao Chien, Pi-Shan Sung
Department of Neurology and Stroke Center,
National Cheng Kung University Hospital

Background Pre-thrombolytic antihypertensive therapy in ischemic stroke patient, which mean systolic blood pressure >185mmHg or diastolic blood pressure > 110mmHg, is

suggested to avoid risk of symptomatic intracranial hemorrhage. It may exceed golden time of recanalization while managing elevated blood pressure. We try to examine the possible inferior consequence due to delaying intravenous thrombolysis, even in short period.

Method We reviewed medical records of ischemic stroke admissions treated with intravenous thrombolysis over a 6-year period at National Cheng Kung University Hospital. Those patients with delayed door-to-needle time (DNT) by any other reasons were excluded, such as cases prior to stroke code system establishment, cases without initiating stroke code, off-label usage of tissue plasminogen activator and complicated physical disorder before thrombolysis. The included patients were divided into two groups according to whether receiving pre-thrombolytic antihypertensive therapy or not. We analyzed door-to-needle time and outcome (modified rankin scale in one month) of these two groups independently.

Result Total 285 patients were enrolled. We excluded those patients with delayed DNT due to prior to group-call system establishment (36 patients), missed group-call, all off-label usage of tissue plasminogen activator (45 patients) and complicated physical disorder before thrombolysis (8 patients). Thus 196 patients were included. There were 172 patients did not receive pre-thrombolytic antihypertensive therapy, with average DNT of 61 minutes in and the median of

mRS was 2; the other 24 patients received pre-thrombolytic antihypertensive therapy and average DNT of 71 minutes and the median of mRS was 3.5. The median of NIHSS was 11 in former group and 9 in latter group.

Discussion According to our experience, receiving pre-thrombolytic antihypertensive therapy delayed DNT 10 minutes in average. The median of NIHSS in patients without pre-thrombolytic antihypertensive therapy was slightly higher than that in those received blood pressure lowering agents, which means no existence of significant difference between these two groups. It might be the consequence of delaying 10 minutes that inferior outcome in those needed pre-thrombolytic antihypertensive therapy, demonstrated by mRS in one month. However, higher blood pressure after ischemic stroke may indicate larger area penumbra or severer arterial stenosis, which may not directly reflect in NIHSS. It may also contribute the inferior outcome in patient needed pre-thrombolytic antihypertensive therapy.

Conclusion Early detection and effective management of elevated pre-thrombolytic blood pressure may be another importance issue for improving outcome in patient receiving thrombolytic therapy.

59

輕度阿茲海默氏症患者之認路功能：比較指北地圖/路徑地圖與地標之輔助功能

方楨文¹ 林松農² 歐陽昆² 柳永青²

¹ 台大醫院雲林分院 神經內科

² 雲林科技大學 管理學院

Comparison study of north-up and track-up electronic maps with and without landmarks on the wayfinding performance of mild Alzheimer's disease patients

Fang, Chen-wen¹, Sung-Nung Lin², Yang-Kun Ou², Yung-Ching Liu²

¹ Department of Neurology, National Taiwan University Hospital (Yunlin Branch), Yunlin, Taiwan

² Department of Industrial Engineering and Management, National Yunlin University of Science and Technology, Yunlin, Taiwan

Objective In this study, through four different exams on a virtual three-dimensional simulated maze, we compared the ability of way finding in three different groups of elderly. (Normal aging/ Minimal cognitive impaired (MCI)/ Early Alzheimer's patient) with different navigation systems.

Methods We prospectively recruited 40 participants (10 AD. 10 MCI. 20 normal control) with similar demographic distribution of age and gender. They received a series of cognitive battery exams, including complex figure test-copy version, clock drawing test, visual form discrimination, trail making test, useful field of view task. They then tried to reach the destination in 4 different mazes with 2 different

facilitating system (North-up v.s. Track-up) and landmarks (with landmarks v.s. without landmarks). They then needed to point out the start point and were asked to pick out a correct route on the paper. .

Results These groups did not differ in age, gender, education, and VFD scores. MMSE, TMT-B and clock drawing test were the 3 tests mostly corrected to error times. (P<0.001) 3 participant groups all made fewer errors with track-up maps (0.18) than with north-up maps (1.83); better outcome was also performed in maps with landmarks (0.91) than in maps without landmarks (1.10). In 3 participant groups, track-up map had shorter performance (126.85 s) time than the north-up map (170.17 s). But, maps without landmarks had a shorter performance time (140.49 s) than the map with landmarks (156.53s).

Conclusion We found that track-up map system could effectively improve the way-finding ability of people with Alzheimer's disease and minimal cognitive impairment. We also noticed that several surrogate markers in cognitive tests were much correlated with the performance of way-finding.

註解 [YHL4]: Mild cognition impaired?

註解 [YHL5]: Mild?

60

職能治療對輕中度失智症患者之療效

王瑾琦 劉景寬 周美鵬 李建勳 龔達璋

許惠敏

高雄醫學大學醫學系神經學碩士班 高雄醫學大學附設中和紀念醫院神經內科 高雄市

Effect of Occupational Therapeutic Program for Patients with Early to Mild Dementia

Chin-Chi Wang^{1,2,5}, Ching-Kuan Liu^{1,2},
Mei-Chuan Chou^{1,2,3}, Chien-Hsun Li^{1,2,4},
Ta -Wei Kung⁵, Hui-Min Hsu^{1,2}

¹ Department of Master's Program in Neurology,
Faculty of Medicine, College of Medicine,
Kaohsiung Medical University;

² Department of Neurology, Kaohsiung Medical
University Hospital;

³ Department of Neurology, Kaohsiung Municipal
Ta-Tung Hospital;

⁴ Department of Neurology, Kaohsiung Municipal
Hsiao-Kang Hospital;

⁵ Kaohsiung Dementia Association

Objectives We examined the efficacy of occupational therapeutic program modified from School of Wisdom of Taiwan Alzheimer's Disease Association (TADA) in improving cognitive function and emotion and prompting quality of life of family caregivers.

Methods This is a single-blinded interventional trial. Subjects with early to mild dementia received occupational therapeutic program two hours once a week. It lasted for 10 weeks each group. We also provided educational-support groups for the family caregivers. The primary parameters were Cognitive Abilities Screening Instrument (CASI) and Center for Epidemiologic Studies-Depression Scale (CES-D). The family caregivers were also evaluated with CES-D and quality of life (WHO-QOL). Paired-samples T tests were used to examine the intervention effect.

Results In total, 50 subjects (21 male and 29 female) participated in the study with a mean age of 73.94 (SD 7.35) years old and a mean education of 9.08 (SD 5.56) years. With paired-samples T test, the CASI ($t=-3.17, p=.003$) and CES-D ($t=2.42, p=.002$) scores of subjects showed significant effect for intervention. There was also a significant difference of the scores of quality of life of the family caregivers before and after intervention for the patients ($t=-2.12, p=.040$). However there was no significant difference of the CES-D of the family caregivers ($t=1.94, p=.059$).

Discussion Qualitatively, in the beginning, many of the patients may have lower activation and motivation for the program and have resistant passive behaviors. When it came to the middle or late stage of the group, they showed more spontaneity and less resistance. After the program, the intervention the participants showed increased social interaction in the group, enriched verbal expression, improved positive mood, and gained self-confidence and both the patients and family caregivers expected a continuous group for them. There were also individual effects for respective group observed. During the program, subjects shared their suffering and adjustment for dementia, which could help them cope with their illness; family caregivers could gain

psychological support to help them relieve their stress.

Conclusion The results were consistent findings of TADA. It implied that intervention of occupational therapeutic program could improve cognitive function of early to mild dementia patients and quality of life of their family caregivers. Occupational therapy could benefit dementia patients and their family, which deserves further promotion in Taiwan.

61

阿茲海默氏症病患經乙酰膽鹼酯酶抑制劑治療後於認知功能篩檢量表之變異

何柏陵 賴秋蓮 周美鵬 劉景寬 楊淵韓
高雄市立大同醫院 高雄醫學大學附設中和
紀念醫院 神經內科

The Change of CASI and Its Subscale after the Treatment of Acetyl-Cholinesterase Inhibitor in Patients with Alzheimer's disease

Bo-Lin Ho, Chiou-Lian Lai, Mei-Chuan Chou, Ching-Kuan Liu, Yuan-Han Yang
Department of Neurology, Kaohsiung Municipal Ta-Tung Hospital, Kaohsiung Medical University Hospital, Kaohsiung Medical University

Objective To evaluate the cognitive outcomes in Alzheimer's patients by *Cognitive Abilities Screening Instrument* (CASI) after annual medical treatment in Taiwan

Background Acetyl-cholinesterase inhibitors (AChEIs) are widely used for the treatment of Alzheimer's disease (AD). The CASI provides quantitative assessment on nine cognitive domains,

and has been widely used for dementia screening in several epidemiological studies. However, its usefulness in evaluating treatment outcome of AD has not been examined.

Methods Consecutive patients fulfilled the diagnostic criteria of AD from January 2007 to September 2010 were prospectively registered into our computerized database. For each recruited AD patient, a series of neuropsychological assessments, including Mini-Mental State Exam (MMSE), CASI, and Clinical Dementia Rating (CDR), were conducted annually to evaluate the therapeutic responses to AChEIs therapy.

Results A total of 385 AD patients were included in our study; 89 patients with global CDR 0.5, 237 with CDR 1.0, and 59 with CDR 2.0. The mean age was 76.96 ± 7.76 years and there were 113 men (29.35%). In CASI subscales analysis, statistically significant improvements were performed in fluency and short-term memory, but declines were demonstrated in orientation and long-term memory. Intergroup differences showed statistical improvement in concentration and orientation in patients with CDR 2.0.

Conclusion Based on the observational results of our study, the

treatment outcomes of AChEIs for AD patients were multidimensional and diverse in view of different cognitive domains. This may provide practical guidance for treatment options and prognostic evaluation in clinical settings.

62

病例個案報告：左側下顳葉腦迴出血引起之辭彙提取障礙

涂敏謙¹ 嚴寶勝^{2,3} 林佩怡¹

¹佛教慈濟綜合醫院台中院區神經內科

²影像醫學部

³慈濟大學

Word retrieval deficit after left inferior temporal gyrus hemorrhage:

A case report

Min-Chien Tu¹, Pao-Sheng Yen^{2,3}, Pai-I, Lin¹

¹Department of Neurology,

²Department of Radiology, Buddhist Tzu Chi General Hospital Taichung Branch, Taichung, Taiwan,

³School of Medicine, Tzu Chi University, Hualien, Taiwan

Abstract

Background Albeit learning process and speech production stream varied across different languages, similarity of neuronal substrate activation and mental conceptualization during oral word production might exist. Previous studies had highlighted the role on anterior and posterior temporal structures, denoting semantic and lexical processing, respectively. It is often the case that speech disturbance happening among subjects with multi-domain cognitive impairment consequent to more extensive brain pathology. Herein we presented a case with word retrieval deficits resulting from focal hemorrhage

at left inferior temporal gyrus and made detail distinction of impaired word retrieval from other possible causes.

Case Report A 82-year-old right handed woman with hemorrhage of left inferior temporal gyrus demonstrated long-lasting word retrieval deficit, in the presence of fluent spontaneous speech, accurate writing, and a few paraphasic errors. Neuropsychological assessment suggested a mismatched phonological representation with preserved semantics and visuospatial function, typical for genuine word retrieval failure (pure anomia). Confrontation naming tests suggested response favorable for category “tools” than “plants”/“animals” and partial benefit from phonological cue. Brain magnetic resonance images had unveiled the Wallerian degeneration from previous old hemorrhagic nidus.

Conclusion A distinct role of inferior temporal gyrus in dominant hemisphere was proposed, as the word being retrieved from the semantic system. Our study implied mechanism underlying phonological word production depends on different, but overlapping areas, in line with the deafferentation processes from neuroimages. On the basis of category-dependent response, it is possible the result of more perceptual attributes being allocated during

naming animals. Benefit from phonological but not semantic cue suggested a novel network, independent to semantic access, parallels major cascade representation process. Our study declared the Chinese phonological naming process was largely consistent with literatures from other languages.

63

失用症在皮質基底核退化症:個案研究

徐榮隆

新光吳火獅紀念醫院神經科

Apraxia in corticobasal syndrome: a case study

Jung-Lung, Hsu

Department of Neurology, Shin Kong WHS Memorial Hospital

Background Apraxia is an uncommon neurobehavioral symptom. However, it is often a presenting feature making it as one of the hallmark signs of corticobasal syndrome, one of the rare parkinsonism. Here we present a clinical case study of apraxia with image findings.

Case Report A 74-year-old retired high school chemistry teacher, a right-handedness, was admitted due to the delusion of infidelity and forgetful for 6 months. His wife first noted that he had the delusion of infidelity, irritable mood and poor sleep 6 months ago. He was visited a psychiatric clinic and anti-psychotic medication was prescribed. Two months later, his insomnia became more prominent and a sleep study was arranged in the other hospital. No REM behavior was documented. His gait

became more clumsy and his wife also noted that he became more dullness and forgetful. He was brought to our hospital for further evaluation. On examination, he was cooperative and orientated. He had good attention and his speech was fluent but slow. His comprehension on single command was preserved. On short-term memory, he only could memorize 5 words after 3 trials of 10 words list learning study. The spontaneous recall and recognition test showed severe deficit. He also demonstrated severe impairment on constructional ability and frontal lobe test such as category verbal fluency and Luria 3-steps test. He had a mask face and his left arm showed slow of motion, increased muscle tone. He could perform voluntary movement in his right hand but he could not perform simple movement in his left hand. His left hand could not pantomime brush/smoking movement. The imitation test also failure in his left hand. He also could not perform simple gesture in his left hand. However, he could understand the gesture meaning by visual inspection. No tremor, myoclonus or alien hand sign noted. His stance was flexion posture and no wide base. His gait was slow, with mild propulsive gait. On image study, brain MRI showed right frontal and bilateral parietal atrophy. HMPAO-SPECT study also demonstrated right frontal and bilateral parietal decreased perfusion.

TRODAT-SPECT study showed decreased the bilateral putamen binding ratio with more severe in the right side.

Conclusion Apraxia in corticobasal syndrome is a frequent feature. This patient demonstrates the limb apraxia in corticobasal syndrome is due to production system defect rather than the concept system or sensory/perceptual system lesion.

64

老年人的次發性躁症：個案研究與文獻回顧

陳軾正

奇美醫療財團法人柳營奇美醫院 神經內科

Secondary Mania in the Elderly: Case Study and Literature Review

Shih-Cheng Chen

Division of neurology, department of internal medicine, Chi Mei medical center, Liouying

Background "primary mania" means a state in bipolar disorder, whereas "secondary mania" results from pharmacological, metabolic, or neurologic causes. Mania has been estimated to represent the cause of 4.6% to 18.5% of all geriatric psychiatric admissions. Mania in older patients used to manifest with more irritability, confusion, psychosis, and mixed features. This syndrome is clinically important because it is associated with relatively poor outcomes in terms of cognition, morbidity and mortality.

Case Study 5 cases regularly followed-up in my clinic were reviewed,

who presented with mania during his/her disease courses. The age of the patients is between 79 to 89 years old. The diagnoses of the patients include right hemisphere infarction (1 case), dementia and parkinsonism (5 cases). The clinical dementia rating scores of the patients are 2–3. The symptoms of mania include decreased need of sleep, being hypertalkative and restless, singing, and psychotic features. Some patients show persisted mania and some have fluctuation of mood states. All 5 patients have been treated with valproic acid and most of them show responses.

Discussion Dementia with Lewy bodies is suspected in my reviewed patients, which is proposed an important etiology of secondary mania in the elderly. Even low-dose dopaminergic therapy is at risk to trigger a mania episode in such patients. Lesions involving the right hemisphere and specifically the orbito-frontal, basal temporal and basal ganglia areas are associated with mania. Dopamine dysregulation with post-synaptic hypersensitivity has been implied in the pathogenesis of mania. Valproic acid seems a reasonable choice to treat secondary mania, as long as the hepatic function is preserved. In conclusion, mood disorder is an important part of behavior and psychological symptoms of dementia, and mania should be

considered in dementic patients with insomnia, confusion or psychotic features, since the treatment responses differ.

65

眼控電腦溝通輔具介入對改善運動神經元疾病患者生活品質及照護者生活壓力之探討

黃啟訓¹ 翁賀修¹ 王麗芬¹ 張穎騰²

¹ 台北市立聯合醫院忠孝院區 神經內科

² 中國醫藥大學 分子系統生物醫學研究所

The application of eye-tracking assistive device for improving the life quality of ALS patients and the burden on caregivers

Chi-Shin Hwang¹, Ho-Hsiu Weng¹, Li-Fen Wang¹, Hao-Teng Chang²

¹ Department of Neurology, Taipei City Hospital - Zhong Xiao Branch

² Graduate Institute of Molecular Systems Biomedicine, College of Medicine, China Medical University

Objective Amyotrophic lateral sclerosis (ALS) is a relentlessly devastating neurodegenerative disease characterized by selective loss of motor function. As such, ALS patients usually retain a normal conscious level, but disease progression eventually results into quadriplegia and severe handicap of oral communication. This communication barrier can generate a great deal of stress for ALS patients and their caregivers. We aimed, therefore, to know whether the use of a communication-assistive device could improve the life quality of ALS patients and relieve the burden on their primary caregivers.

Methods Twenty quadriplegic severe handicapped ALS patients with their primary caregivers were collected from

the ALS center of Taipei City Hospital. Subjects were divided into two groups depending on whether they used (n = 10) or did not use (n = 10) an eye-tracking communication-assistive device. We assessed patients' quality of life and severity of depression using the ALS Specific Quality of Life Instrument-Revised and the Taiwanese Depression Questionnaire, respectively. The Caregiver Burden Scale was used to assess the burden on caregivers. The data were analyzed using GraphPad Prism software. For comparisons between two groups, the two-tailed Student's t-test was used.

Results The eye-tracking assistive device significantly improved patients' quality of life, as compared with patients in the non-user group. The assistive device also reduced the burden on caregivers. This likely resulted from more-effective communication between patients and caregivers.

Conclusions Our study shows that an eye-tracking communication technology can reliably improve the life quality of ALS patients and relieve the burden on their caregivers.

66

改善 β -澱粉樣蛋白(1~40)誘發學習記憶障礙模式的替代療法

葉宗勳^{1,2}, 謝明村³, 葛其梅², 吳啟瑞³, 廖俊旺⁴, 周寬基⁵

¹ 秀傳紀念醫院神經內科

² 國立中興大學生命科學系

³ 中國醫藥大學藥學院中國藥學暨中藥資源學系

⁴ 國立中興大學獸醫病理學研究所

⁵ 國立中興大學生物醫學研究所

Alternative therapy on amyloid β 1-40-induced Alzheimer's disease-like phenotype

Chung-Hsin Yeh^{1,2}, Ming-Tsuen Hsieh³, Chi-Mei Hsueh², Chi-Rei Wu³, Jiunn-Wang Liao⁴, Kuan-Chih Chow⁵

¹Department of Neurology Show Chwan Memorial Hospital, Changhua, Taiwan, (ROC)

²Graduate Institute of Life Sciences, National Chung Hsing University, Taichung 40001, Taiwan, (ROC)

³School of Chinese Pharmaceutical Sciences and Chinese Medicine Resources, College of Pharmacy, China Medical University, Taichung 40001, Taiwan, (ROC)

⁴Department of Veterinary Medicine, National Chung-Hsing University, Taichung 40001, Taiwan, (ROC)

⁵Graduate Institute of Biomedical Sciences, National Chung Hsing University, Taichung 40001, Taiwan, (ROC)

Abstract Alzheimer's disease (AD) is an irreversible neurodegenerative disorder characterized by amyloid accumulation, neuronal death and cognitive impairments. YCTMT is one of traditional Chinese decoction, which has never been used to enhance cognitive function and treat neurodegenerative disorders such as senile dementia. Whether YCTMT has a beneficial role in improving learning and memory in AD patients remains unclear. The present study showed that oral administration of YCTMT ameliorated amyloid β ($A\beta_{1-40}$)-injection induced learning and memory impairments in rats, examined using passive avoidance and Morris water-maze tests. Immunostaining and western blot results showed that continuous $A\beta_{1-40}$ -infusion caused amyloid accumulation and decreased acetylcholine level in

hippocampus. Oral administration of medium and high dose of YCTMT 7 days after the $A\beta_{1-40}$ -infusion decreased amyloid accumulation area and reversed acetylcholine decline in the $A\beta_{1-40}$ -injected hippocampus, suggesting that YCTMT might inhibit $A\beta$ plaque accumulation and rescue reduced acetylcholine expression. This study has provided evidence on the beneficial role of YCTMT in ameliorating amyloid-induced AD-like symptom, indicating that YCTMT may offer an alternative strategy for treating AD.

67

晚年代謝症候群預防七十五歲以上高齡男性的認知功能下降

劉建良^{1,2} 林明憲^{1,2} 彭莉甯^{1,2} 陳亮恭^{1,2}
蘇千田^{3,4} 劉力樞^{1,2} 陳亮宇^{1,2}

¹ 國立陽明大學 高齡與健康研究中心

² 台北榮民總醫院高齡醫學中心 高齡醫學科

³ 臺北醫學大學附設醫院 家庭醫學科

⁴ 臺北醫學大學公共衛生暨營養學院

Late-Life Metabolic Syndrome Prevents Cognitive Decline among Older Men Aged 75 Years and Over: One-Year Prospective Cohort Study

Chien-Liang Liu^{1,2}, Ming-Hsien Lin^{1,2}, Li-Ning Peng^{1,2}, *Liang-Kung Chen^{1,2}, Chien-Tien Su^{3,4}, Li-Kuo Liu^{1,2}, Liang-Yu Chen^{1,2}

¹ Aging and Health Research Center, National Yang Ming University, Taipei, Taiwan

² Center for Geriatrics and Gerontology, Taipei Veterans General Hospital, Taipei, Taiwan

³ Department of Family Medicine, Taipei Medical University Hospital

⁴ School of Public Health, College of Public Health and Nutrition, Taipei Medical University, Taipei, Taiwan

Background Although metabolic syndrome (MetS) has been reported to be associated with cognitive decline and dementia, little was known about late-life MetS and cognitive decline

among older old population. The main purpose of this study was to evaluate the role of MetS and cognitive decline among men aged 75 and over in Taiwan.

Methods This is a prospective cohort study which recruited men aged 75 years and older with intact cognitive function living in the Banciao Veterans Care Home, a retirement community for veterans in northern Taiwan. All participants received complete history taking, physical examinations, global cognitive tests and laboratory tests. Cognitive status was re-evaluated one year after enrollment to evaluate the role of MetS to cognitive decline in this study population.

Results Overall, 338 people participated in the study and 62 of them were excluded due to low baseline MMSE score, and the remaining 276 people (mean age: 82.4±4.2 years) were enrolled for study. The prevalence of MetS and annual cognitive decline were 22.5% and 15.6%, respectively. During the follow-up period, 9 (3.3%) participants died, 229(83.0%) complete the study. Subjects with cognitive decline were older and had lower serum levels of serum total cholesterol. Multivariate logistic regression showed that older age (OR:1.13, 95% C.I.: 1.01-1.25, P=0.026) and central obesity (OR: 4.19, 95% CI: 1.26-13.91, P=0.019) were independent risk factors for cognitive decline; and MetS defined by Adult Treatment Panel

III was a protective factor (OR: 0.20, 95% CI: 0.04-0.94, P=0.041). The protective effect of MetS remained the same when MetS was defined by the criteria of International Diabetes Federation.

Conclusions Age and central obesity were significant risk factors of cognitive decline, but late-life MetS, however defined, had protective effect on cognitive function. Further investigation is needed to clarify the possible mechanism of MetS and cognitive function in older adults.

68

阿茲海默症或庫賈氏症？

蕭元淳 白明奇
國立成功大學醫學院附設醫院 神經部暨
失智症中心

Alzheimer disease or Creutzfeldt-Jacob disease?

Yuan-Chun Hsiao, Ming-Chyi Pai
Department of Neurology & Alzheimer's
Disease Research Center, National Cheng
Kung University Hospital, Tainan, Taiwan

Case Report A 77 year-old retired pharmacist, with elementary education, first visited our Dementia Clinic on 26 Aug 2011. Episodic memory impairment, repetitive queries, misplacement, spatial navigational impairment, executive dysfunction, change in sense of taste, and stealing delusions were noted by his family for 2 years or longer which deteriorated in recent few months. His basic activities of daily living were all independent.

Apart from the aforementioned symptoms, he had no sleep deprivation, REM sleep behavioral disorders, daytime hypersomnolence, visual hallucinations, cognitive fluctuation, unexplained falls, startle response or myoclonus. He had no family history of dementia or Creutzfeldt-Jacob disease (CJD), surgery history or experience of blood transfusion or donation and no history of traveling abroad in his life. His CASI was 57/100 and MMSE 17/30 and EEG with diffused intermittent theta activities in August 2011. Brain MRI showed cortical ribbon hyperintensities on DWI and FLAIR in bilateral fronto-temporo-parietal lobes and a diagnosis of CJD or encephalitis was made by our radiologist. In January 2012, his cognitive function deteriorated with CASI 52/100 and MMSE 17/30, and he was admitted to our hospital in March 2012. CSF studies showed no evidence of infection, but 14-3-3 protein was positive. His mentality got worse after discharge with CASI 38/100 and MMSE 11/30 in August 2012. Brain MRI and EEG were done in June and August 2012 respectively and showed no progression compared with previous studies.

Conclusion Our patient's clinical presentation had been in favor of Alzheimer disease (AD) instead of CJD, although his cognitive deterioration was faster than in typical AD. The sensitivity and specificity of cortical hyperintensity

restricted to the cortex ("cortical ribbon sign"), striatum, or both in DWI and FLAIR were reported 92% and 94% respectively. The CSF 14-3-3 testing for CJD in recent studies also shows specificity 48% and specificity 65%. Our patient has both cortical ribbon sign and positive 14-3-3 protein. The absence of family history, blood transfusion or traveling abroad made familial CJD or variant CJD unlikely. AD, CJD or even a new variant disease is a diagnostic challenge.

69

代謝症候群與 apolipoprotein E 基因多型性於行為監控的角色

賴秋蓮^{1,2} 劉立民² 徐崇堯^{1,2} 王貞婷²
劉景寬^{1,2}

¹高雄醫學大學 醫學系神經學科暨碩士班

²高雄醫學大學附設醫院 神經科

The role of metabolic syndrome and apolipoprotein E genotypes in action monitoring

Chiou-Lian Lai^{1,2}, Li-Min Liou², Chung-Yao Hsu^{1,2}, Chen-Ting Wang², Ching-Kuan Liu^{1,2}

¹Department of and Master's Program in Neurology, Faculty of Medicine, College of Medicine, Kaohsiung Medical University

²Department of Neurology, Kaohsiung Medical University Hospital

Objective The aims of the present study are to investigate the effect of metabolic syndrome and apolipoprotein E (ApoE) genotypes on action monitoring in middle-aged and elderly adults without dementia.

Background Action monitoring is an important component of executive function. The metabolic syndrome, a constellation of cardiovascular and

metabolic origin, may be a risk factor for cognitive decline. Apolipoprotein E (Apo E) is a lipoprotein that transports cholesterol and other lipids. It is well accepted that $\epsilon 4$ is a risk factor for the development of AD, although the $\epsilon 4$ effect is discrepant for cognitive decline in normal elderly. The role of metabolic syndrome and Apo E genotypes in action monitoring needs to be reappraised.

Methods We recruited 89 mentally healthy middle-aged and older adults (M:F=32:57; age=65.96±5.81 y/o). Cognitive assessment (Cognitive Abilities Screening Instrument, CASI and Mini-Mental State Examination, MMSE), flanker task, metabolic syndrome, and Apo E genotypes were measured for all participants.

Results The percentages of metabolic syndrome and $\epsilon 4$ carrier among all participants were 34.83 and 17.98, respectively. When the participants were stratified according to the presence of metabolic syndrome, there was no difference in scores of CASI and MMSE-CE, the percentage of $\epsilon 4$ carriers and measurements of flanker task. The $\epsilon 4$ carriers did not display significant difference in CASI and MMSE scores, the percentage of metabolic syndrome, and measurements of flanker task.

Conclusion Our findings suggest that there is no association between scores of CASI and MMSE-CE, metabolic

syndrome, $\epsilon 4$ carrier and action monitoring in mentally healthy middle-aged and older adults.

動作障礙學

70

高血糖性半側舞蹈症病患運動皮質興奮性之改變

李介元 張秀姪
高雄榮民總醫院 神經內科

Changes in motor cortex excitability in patients with hyperglycemic hemichorea-hemiballism
Jie-Yuan Li, Betty Chang
Division of Neurology, Kaohsiung Veterans General Hospital

Objective Hemichorea-hemiballism (HC-HB) in uncontrolled diabetes mellitus is an uncommon manifestation of hyperglycemia. The pathophysiology of hyperglycemic HC-HB is not well understood. A previous report showed increased intracortical inhibition in the motor cortex (MC) in a diabetic patient with HC-HB. The objective of this study is to investigate MC excitability in patients with hyperglycemic HC-HB. We hypothesized that intracortical inhibition measured with transcranial magnetic stimulation (TMS), which likely reflects the excitability of cortical GABAergic circuits, would be impaired in patients with hyperglycemic HC-HB.

Methods We studied 15 patients with mean age 71.5 years (range 48 to 94

years) and 12 age-matched healthy subjects. The MC contralateral to the hemichorea was tested. TMS studies included motor evoked potential, recruitment curve, GABA_A mediated short interval intracortical inhibition (SICI), intracortical facilitation (ICF) and GABA_B mediated silent period (SP) duration and long interval intracortical inhibition (LICI).

Results There was no significant difference in motor threshold, recruitment curve response, SICI, ICF in both rest and active conditions between patients with hyperglycemic HC-HB and normal subjects. However, LICI was significantly increased during muscle activation but not at rest in patients with hyperglycemic HC-HB. The SP duration is also increased in patients with hyperglycemic HC-HB.

Conclusion LICI and SP are increased in the MC contralateral to the hemichorea in hyperglycemic HC-HB, but only during muscle activation. HC-HB may be associated with increased GABA_B receptor mediated inhibitory activity in the MC.

71

初始表現類似威爾森氏症的早發型亨丁頓舞蹈症之一病例報告

李佳舫 蔡力凱
台大醫院雲林分院 神經部

A Case of Juvenile Huntington's disease with Initial Presentations Mimicking Wilson's disease

*Chia-Fang Lee, Li-Kai Tsai
Department of Neurology, National Taiwan University Hospital, Yun-Lin Branch*

Background Huntington's disease (HD) is characterized by choreiform movements, psychiatric problems, and dementia. However, chorea is notably absent but with variable presentations including parkinsonism, behavior problems, and seizure in juvenile HD, also known as Westphal variant HD.

Case report A 23-year-old woman, without history of systemic diseases, presented as progressive flattening dysarthric speech and unsteady gait for 2 years. She also had psychiatric symptoms and depressive mood. She denied usage of illicit drug or neuroleptic agents and the family history was unremarkable. Neurological examination revealed prominent extrapyramidal signs, such as bradyphrenia, rigidity, blepharospasm, and torticollis. Monotonous speech with explosive character, impaired pursuit and voluntary saccades of eyes, and ataxic gait were also noted. Brain MRI showed diffuse cortical atrophy. Laboratory data showed a low ceruloplasmin level of 16.8 mg/dL (Norm, 20-60) with normal serum and urine copper level. She further received serial studies for diagnosis of Wilson's disease. However, the results of liver function tests and slip-lamp examination were normal. Liver biopsy showed no copper accumulation. The

results of autoimmune survey, thyroid function, and anti-HIV were all within normal limits. The genetic results for SCA (Spinocerebellar ataxia) 1, 2, 3, and 17 were negative. Finally, the genetic study confirmed the diagnosis of HD with 17/59 CAG repeats in HTT gene.

Conclusion Juvenile HD is clinically distinct from classic HD and may be difficult to be differentiated from other neurodegenerative disorders, such as Wilson's disease. Genetic testing is essential in diagnosis.

72

不痛的腿及移動腳趾之個案報告

李杰勳¹ 李介元^{2,3}

¹ 寶建醫院 神經內科

² 高雄榮民總醫院神經內科

³ 國立陽明大學醫學院 醫學系

A Case Report of Painless Legs and Moving Toes Syndrome

Chieh-Hsun Lee¹, Jie-Yuan Li^{2,3}

¹ Division of Neurology, Pao-Chien Hospital, Pingtung, Taiwan,

² Division of Neurology, Kaohsiung Veterans General Hospital, Kaohsiung, Taiwan, ³ Faculty of Medicine, School of Medicine, National Yang-Ming University, Taipei, Taiwan

Background Painful legs and moving toes is a rare syndrome consists of continuous or semicontinuous involuntary movements of toes associated with pain in the affected extremity. With respect to the painless variant, very few patients have been reported and most of them were idiopathic. We report a patient with 6-month history of involuntary movements of the toes clinically and

electrophysiologically similar to those seen in painful legs and moving toes syndrome, but without any associated pain or predisposing factors.

Case Report A 14-year-old girl presented with involuntary movements of her toes of the left foot without any associated pain from 6 months ago. The movements were not related to the time of day and persisted during sleep. Besides, the movements could be suppressed for a moment but would begin again when she focused on other things. She didn't have urges to move her legs or walk around. She didn't have any past history of trauma or family history of movement disorder. She denied taking any psychotropic agents in the past. Neurological examination revealed no abnormal finding except the involuntary movements of the toes. The movements were low frequency, semirhythmic and flexion-extension, with a sinusoidal, wriggling and quivering appearance. Blood analyses and brain CT scan were normal. An electromyography and nerve conduction studies revealed no evidence of lumbosacral radiculopathy or peripheral neuropathy. MRI of lumbosacral spine was normal.

Conclusions Painless legs and moving toes is a very rare syndrome. Until now, only 10 cases of painless legs and moving toes syndrome were

reported. To our knowledge, this is the eleventh reported case.

73

急性硬膜下出血合併雙側肢體舞蹈症

林奇模 張揚沛 施邦英 賴秋蓮
高雄醫學大學附設中和醫院 神經內科

Acute subdural hemorrhage presenting as parballism

Chi-Mo Lin, Yang-Pei Chang, Pang-Ying Shih, Chiou-Lian Lai
Department of Neurology, Kaohsiung Medical University Hospital

Background Rarely, chorea may be a presentation of subdural hemorrhage which is shown on MRI imaging.

Case Report A 84-year-old single woman was admitted due to accidental falling down and head injury. There were no obvious focal neurological sign at emergency department. Brain CT revealed skull laceration and falx subdural hemorrhage. Acute onset of intermittent bilateral limb large-amplitude and violent movement was noted three days later. In addition, she could not control her movement and multiple bruise was found over four limbs. Neurological examination was essentially normal except for parballism over four limbs. Brain CT revealed mild hydrocephalus and no progression of subdural hemorrhage. Limb movement improved gradually 4 days later. Her past history included hypertension, hepatitis B, chronic kidney disease. Brain MRI was not able to perform due to large amplitude of limb movement. Operation

was not performed for hydrocephalus because of old age.

Conclusion Like previous case reports, our patient suggests the parballism may be a clinical manifestation of acute subdural hemorrhage.

74

以反應緩慢及步態異常做為臨床表現的MELAS粒腺體基因突變個案

林邵臻 陳瓊美 張國軒
林口長庚紀念醫院 神經內科

A patient with slow responsiveness and gait disturbance carrying MELAS mitochondrial gene mutation

Shao-Cheng Lin, Chiung-Mei Chen, Kuo-Hsuan Chang
Department of Neurology, Chang-Gung Memorial Hospital and University College of Medicine, LinKou Medical Center

Background and Objective

Mitochondrial DNA 3243 A>G mutation has demonstrated a strong association with mitochondrial myopathy, encephalopathy, lactic acidosis, strokes syndrome (MELAS). However, a number of patients carrying this mutation developed other neurological features, such as bradykinesia, gait disturbance and dyskinesia as reported below.

Case report A female diabetic patient began to develop progressive slow responsiveness, gait disturbance and right hand dyskinesia at the age of 20 years old. Bilateral hearing impairment

was found two years later. Headache, stroke, visual impairment, seizure, mental or other developmental retardation were absent. She described a family history of young-onset diabetes mellitus and hearing impairment, which is noted in her mother and uncle. She was in a relatively small-sized body picture with a height of 143.5 cm and a weight of 35 kg. The neurological examinations revealed bilateral bradykinesia, shuffling gait and dystonic movements in her right hand. She had elevated HbA1c (14.7%). Her serum levels of calcium, inorganic phosphate, copper, T3, T4, intact-PTH and ceruloplasmin were normal. Bilateral peripheral sensori-hearing blockages were found by brain stem evoked potential study. Calcification of bilateral caudate heads, lentiform nuclei and thalamus, and diffuse cerebral and cerebellar cortical atrophy were shown by head computed tomography and magnetic resonance imaging studies. Her Tc99m-ethyl cysteinate dimer single photon emission computed tomography (SPECT) study showed decreased perfusion of bilateral cerebral cortex. However, no presynaptic dopaminergic lesion was found by Tc99M-TRODAT dopamine transporter SPECT study. Results from genetic test found the m.3243A>G MELAS gene mutation. Her slow response, gait disturbance and right hand dystonia were mildly improved by the treatment with low dose sinemet (200 mg per day).

Conclusion The m.3243 A>G MELAS mutation can be found in young-onset movement disorder patients especially with basal ganglion calcifications and diffuse cortical hypoperfusion.

75

FBXO7 基因在台灣巴金森症病患之角色

林靜嫻 陳孟伶 戴春暉 吳瑞美
臺大醫院 神經部

Mutational analysis of FBXO7 gene in Parkinson's disease in a Taiwanese population

Chin-Hsien Lin, Meng-Ling Chen, Chun-Hwei Tai, Ruey-Meei Wu
Department of Neurology, National Taiwan University Hospital

Objective To investigate the mutation frequency of *FBXO7* in patients with Parkinson's disease (PD) in Taiwan.

Background The ubiquitin-proteasome pathway plays a major role in the degradation of mis-folded or regulatory proteins in cells. Mutations in the *FBXO7* gene (PARK15), which protein is a component of ubiquitin E3 ligase, cause an autosomal-recessive early-onset parkinsonism with pyramidal tract signs. The information regarding *FBXO7* in risk of PD in other ethnicity is limited.

Methods We assayed *FBXO7* gene in a total of 900 participants comprising

448 PD patients and 452 age/gender matched controls from Taiwan. The entire *FBXO7* coding region and intron-exon boundaries were sequenced.

Results We identified two novel missense substitutions, p.Ile87Thr and p.Asp328Arg, in a single heterozygous state in two early-onset PD (EOPD) patients individually (1.1% in EOPD). These two variants were not observed in controls with total 904 normal alleles. Additionally, we also found one non-coding variant, exon 1 IVS-329C>T, modestly associated with PD. The frequency of CT/TT genotype was higher in PD patients compared with controls (OR=1.43, 1.02-2.01, P=0.04). The clinical phenotypes of genetic variant carriers are similar to that seen in idiopathic PD.

Conclusion We conclude that *FBXO7* gene contributes little to typical PD in our population. Further studies in other ethnic cohorts will be important to address its potential pathophysiologic role in PD.

76

視丘下核深腦刺激術後持續過久之異動症

翁儀靜 林衛邑 陳瓊珠 陸清松
林口長庚紀念醫院 神經內科

Prolonged dyskinesia after bilateral STN-DBS

Yi-Ching Weng, Wey-Yil Lin, Chiung-Chu Chen,
Chin-Song Lu
Department of Neurology, Chang Gung Memorial
Hospital Linkou, Chang Gung University

Background Bilateral subthalamic nucleus deep brain stimulation (STN-DBS) is the choice of treatment for motor complications of Parkinson disease. In previous reports, some cases developed stimulation and medication insensitive dyskinesia soon after implanting the electrodes. The dyskinesia resolved spontaneously in less than 12 weeks. Here we report a case presents different pattern of dyskinesia after the surgery.

Case report A 69 years old female is a case of Parkinson's disease for 13 years with the initial presentation of tremor and rigidity in the left limbs. She underwent bilateral STN-DBS due to rigidity and intractable neck dystonia. Pre-operation UPDRS scores were 43.5 at on phase and 57 at off phase. Dyskinesia rating scale before operation in medication on and off was 0. There was no complication in the perioperative period, and the implantable pulse generator (IPG) was installed. However, she developed dyskinesias in the right leg 2 weeks later without turning on the stimulator. Brain MRI disclosed neither microbleed nor malposition of the electrodes. The stimulation was switched on 2 weeks later. The dyskinesia was chorea like and persisted. There was also some interference in walking and daily living due to chorea. The dyskinesia rating

scale in medication on and off was 3. At the same time, right side rigidity and bradykinesia improved as left side and no tremor. The dyskinesias were not altered by stimulation on, stimulation off, changing stimulation settings, reducing levodopa (from 800 down to 400mg per day) or stopping all levodopa. The dyskinesias were not improved by biperiden, amantadine, clonazepam or haloperidol. The dreadful dyskinesia in the right leg disappeared spontaneously 6 months later.

Conclusion The patient developed prolonged dyskinesia after bilateral STN-DBS. The dyskinesia could not be relieved by medication or changing the parameters of stimulation. The duration of complicated dyskinesias after IPG implantation was even longer than those reported in the literature described as long dyskinesia. The underlying pathogenic mechanisms are warranted for further exploration

77

跑步機運動訓練改善巴金森氏病患者往後步態之成效

袁瑞昱^{1,2} 曾櫻枝³

¹臺北醫學大學醫學院醫學系神經學科

²臺北醫學大學附設醫院神經內科

³臺北醫學大學護理學院老人護理暨管理學系

Effects of treadmill exercise training on backward gait in early Parkinson's disease

Rey-Yue Yuan^{1,2} Ing-Jy Tseng³

¹Department of Neurology, College of Medicine, Taipei Medical University.

²Department of Neurology, Taipei Medical University Hospital.

³School of Geriatric Nursing and Care

Management, Taipei Medical University.

Objective To examine the immediate (within 1 week) and short-term (at 4 weeks) effects of a 12-week treadmill exercise training program on backward walking (BW) gait in patients with early stage Parkinson's disease (PD).

Background Treadmill exercise training for PD patients improves forward walking (FW) gait; however, training effects on BW gait are still undetermined.

Methods Sixteen patients with early PD (8 males, 8 females) received a 12-week (36 sessions) exercise training program by walking forwards on treadmill. A GAITRite[®] walkway was used to quantify the spatial and temporal parameters of BW and FW gait before training, within 1 week and at the 4th week after treadmill training was completed. A repeated measures design was applied to compare among pre- and post-training gait in BW and FW.

Results After training, PD participants walked backwards and forwards with increased velocity, enlarged stride length, prolonged swing phase, and decreased double support phase. These BW and FW gait improvements were seen within 1 week and at the 4th week after training was completed. Moreover, post-training swing time and stride

length became more consistent in backward and forward walking; the swing time variability and stride length variability in BW and FW were reduced within 1 week and at the 4th week after training. Post-training gait improvements in BW and FW were comparable. However, cadence did not differ among pre and post-training gait in BW and FW.

Conclusion These data extend the current knowledge, indicating that a 12-week treadmill exercise training program in forward walking improves both BW and FW gait for up to 4 weeks duration in early PD patients. Treadmill exercise training can be considered part of a rehabilitation strategy to overcome gait disturbances of PD in both walking directions.

78

合併使用 Tramadol, Dextromethorphan, Levodopa-引起血清素症候群-個案報告
許家綸 吳亞榮¹² 葉建宏
新光吳火獅紀念醫院神經科

Serotonin syndrome resulting from coadministration of tramadol, levodopa and dextromethorphan - Case report

Chia-Lin Hsu, MD¹, Ya-Ying Wu, MD^{1,2}, Jiann-Horng Yeh, MD¹

¹ Department of Neurology, Shin Kong Wu Ho-Su Memorial Hospital, Taipei, Taiwan

² Institute of Brain Science, National Yang-Ming University, Taipei, Taiwan

Background Serotonin syndrome is induced by several drugs interaction, such as SSRI, SNRI, antiemetics, and MAOI. Drug interactions are commonly

implicated in serotonin syndrome. We present a case of serotonin syndrome, shortly after combined use of tramadol, levodopa, and dextromethorphan.

Case Report A 86-year-old man, with history of chronic pulmonary obstructive disease, was brought to emergent department due to change in consciousness and generalized myoclonus, one day after discharged from chest care ward.

Dextromethorphan (120 mg/d) was regularly used chronically. Newly added tramadol(94.5mg/day) and levodopa(300mg/d) were used for few days. At ED, high fever to 40°C, agitation followed by severe hypotension(SBP/DBP:62/44 mmHg) were noted. Stimulus sensitive generalized myoclonus occurred in trunk and limbs simultaneously. Initially, midazolam(5mg) was administered for agitation and hyperthermia.

Laboratory investigation revealed leukocytosis with left shift, elevated hepatic enzyme (GPT:61U/L) and CPK level (856U/L). There was no infectious source. A presumptive diagnosis of serotonin syndrome was made. The offending drugs were discontinued, and oral cyproheptadine was administered (12mg, followed by 4mg, Q6h for one day, then taper to 4mg Q8h for a day). The next day, the agitation, myoclonus and consciousness improved gradually.

Discussion This is the first case report of serotonin syndrome caused by combination of tramadol, levodopa, dextromethorphan. Tramadol inhibits reuptake of serotonin and norepinephrine. Dextromethorphan binds to serotonergic receptors and could induce serotonin syndrome by conventional dose. Levodopa is proposed to involve displacement of endogenous serotonin into the synaptic cleft. Serotonin syndrome is far more common to be caused by a combination of drugs that act at different 5 HT receptor sites. We want to emphasize high risk of developing serotonin syndrome after combination of these commonly used drugs, especially in the elderly. Early diagnosis is crucial.

79

McLeod syndrome: 以神經精神症狀為起始表現且經基因證實之台灣第一位病例報告

¹陳珮昀 ¹甄瑞興 ²楊智超 ²李銘仁 ³邱廷慧 ⁴ 賴思佳 ⁴ 葉篤學 ⁴ 陸清松

¹ 台北市立聯合醫院仁愛院區神經內科

² 台灣大學附設醫院神經內科

³ 台北市立聯合醫院教學研究部

⁴ 林口長庚紀念醫院神經內科

McLeod syndrome: the first genetic-proved Taiwanese case with initial neuropsychiatric presentation

¹Pei-Yun Chen, MD, ¹Sui-Hing Yan, MD,

²Chih-Chao Yang, ²Ming-Jen Lee, ³Yen-Hui Chiu,

⁴Szu-Chia Lai, MD, ⁴Tu-Hsueh Yeh, MD, PhD,

⁴Chin-Song Lu, MD

¹ Department of Neurology, Taipei City Hospital, RenAi branch

² Department of Neurology, National Taiwan University Hospital

³ Department of Education and Research, Taipei City Hospital

⁴ Department of Neurology, Chang Gung Memorial Hospital

Background McLeod syndrome is a rare subtype of neuroacanthocytosis. It is an X-linked multisystem disorder involving central nervous system, neuromuscular, hematologic, cardiovascular and liver function. The genetic cause is mutations of the *XK* gene.

Case report A 67-year-old male first presented with paranoid persecutive delusion, anxiety and depression at the age of 48. Abnormal liver function was noted at the age of 56 but serology of hepatitis B and C were negative. Arrhythmia and coronary artery disease were diagnosed at the age of 58. Myalgia, fatigue and muscle wasting developed since he was 62 years old. Motor restlessness, choreoathetosis, grimacing face, shoulder shrugging, tics, tongue biting and unsteady gait gradually developed at the age of 63. Laboratory investigations were unremarkable except marked serum creatine kinase elevation (602-3328 U/L; normal, <190 U/L). Nerve conduction studies and electromyography revealed sensory predominant axonal polyneuropathy. Brain computed tomography and magnetic resonance image were unremarkable. The peripheral blood smear revealed 36% acanthocytes. Genetic testing of the patient showed a novel nonsense mutation (c.154C>T;

p.Gln52X) at the exon 1 of *KX* gene. His elder brother had epilepsy history and a special serology phenotype-McLeod phenotype was found incidentally when he underwent hip joint surgery.

Conclusion To the best of our knowledge, this is the first genetic-proved Taiwanese report of McLeod syndrome. The collecting phenotype of idiopathic movement disorder, psychiatric symptom, peripheral neuropathy, associated with markedly elevated creatine kinase indicates the necessity of erythrocyte morphology and serology test for Kell blood group antigen/antibody and genetic test for *XK* gene mutation. Multidisciplinary management including genetic counseling, surveillance for cardiovascular, hepatic, neuromuscular, epileptogenic symptoms, as well as banked autologous blood and Kx-negative blood are important for patient care.

80

GTP cyclohydrolase 1 (*GCHI*) Exon 1b Arg88Leu 突變所致之多巴胺反應型肌張力不全症家族

楊程智¹ 劉彥良³ 陸清松² 賴思佳² 劉瑞貞¹
呂明桂¹ 蔡崇豪^{1,4}

¹ 中國醫藥大學附設醫院 ² 林口長庚醫院 ³
署立彰化醫院神經內科

A Family of Dopa Responsive Dystonia Caused by Arg88Leu at GTP cyclohydrolase 1 (*GCHI*) gene exon 1b

CC Yang¹, YL Liu³, CS Lu², SC Lai², JJ Liu¹, MK Lu¹, CH Tsai^{1,2}

Department of Neurology, China Medical University Hospital¹, Chang Gung Memorial Hospital², Chang Hua Hospital³; Graduate

Institute of Neural and Cognitive Sciences, China Medical University⁴, Taiwan

Background Patients with Dopa-responsive dystonia (DRD) had been shown to be caused by 5 different mutations, including Ser81Pro, Ser76X, Gly203Arg, 249delA and IVS5+3insT, in the *GCHI* gene in Taiwan. Herein, we report a family with DRD with a mutation of Arg 88Leu at exon 1b. The family extended the DRD genotypic spectrum of the country.

Subject and Methods The 24-year-old woman developed feet clawing with slow wiggling movement since her 15 years. The symptoms would interfere with her running or even walking. The foot symptoms would also hinder her from falling asleep normally and she usually had to put her soles against the bed plate so as to suppress the involuntary movements at bedtime. Sleep benefit for around 1 hour was traced. Her symptoms were exacerbated a bit in recent 2 years. Neurological examination revealed feet dystonic movement. There was no akinesia, rigidity or tremor. Her feet dystonia responded to sinemet in daily dose of 150 mg well. Her father and 2 uncles have tremor of the limbs and probably her 2 grandaunts also had limbs tremor. No neurological symptom could be traced of her 2 elder sisters. Direct sequencing of the *GCHI* Gene revealed a point mutation of Arg 88Leu at exon 1b of the index

case, her father and asymptomatic eldest sister.

Conclusion The current report extends the DRD genotypic spectrum in Taiwan. In the genetically proved cases, the phenotypes are variable and range from asymptomatic, tremor to full blown features of dystonia. The phenomenon raises the caution for the neurologists on visiting the possible candidates in practice, especially in young patients.

神經肌病學

81

閃電擊傷造成之脊髓病變併周邊神經病變

林君賢 郭弘周

林口長庚紀念醫院 神經內科

Lightning strike with dorsolateral cord syndrome and peripheral neuropathies

Chun-Hsien Lin, Hung-Chou Kuo

Department of Neurology, Chang Gung Memorial Hospital, Lin-Kou Medical Center

Background Spinal cord injury following electrical trauma was rarely reported. We present an unusual clinical manifestation with myelopathy associated with severe peripheral nerves injuries in a patient struck by lightning.

Case report There is a 61 year old male got lightning strike during mountain climbing. The lightning caused inlet wound on right occipital scalp and outlet wound over right sacrum, lateral aspect of right distal leg and foot and left metatarsal-phalangeal regions and resulted in burning injury of seven

percent of total body. Tetraplegia and urinary retention were found after recovery from rhabdomyolysis with acute renal failure three days later. The neurological examination showed paraplegia and decreased muscle strength with Medical Research council of Great Britain (MRC) grade 1/5 in both arms and 4/5 in distal part of upper limbs, general areflexia and mild reduction of pain sensation to pinprick below fourth thoracic level and loss of vibration sensation over legs. The T2 weighted imaging of spinal magnetic resonance study revealed petechial hemorrhage and edema over bilateral lateral cervical cord. The motor and sensory evoked potential studies demonstrated cervical myelopathies. The nerve conduction studies revealed bilateral sciatic neuropathies that worse in right side and needle electromyogram showed marked spontaneous activities in all tested muscles. The nerves of upper limbs were relatively spare on the electrophysiological studies.

Conclusion The mechanism of neurological damage following electrical injury remains unclear. In the literature review, the lesion caused by lightning injury was reported along neuraxis, from cerebral cortex, cerebellar cortex, spinal cord and peripheral nerve. In view of our patient, the large myelinating fibers of central and peripheral nervous system are

labile to electrical injury. In addition to motor neuron syndrome or rhabdomyolysis, the neurological complication is dependent on the entry and direction of lightning electrical transduction that descending from cervical through lumbosacral cord to peripheral nerves of lower limbs.

82

PMP22 基因數目對再生髓鞘神經纖維的形態學影響

林恭平 李宜中

臺北榮民總醫院 神經醫學中心

Morphometric Analysis of Regenerative Myelinated Fibers Related to Dosage Effects of PMP22 Gene

Kon-Ping Lin, Yi-Chung Lee

Neurological Institute, Taipei-Veterans General Hospital

ABSTRACT

Objective We will examine the morphological changes of regenerative myelinated fibers(RMF)in sural nerve biopsies from patients with PMP22 duplication (Charcot-Marie-Tooth disease type 1A, CMT1A), PMP 22 deletion (Hereditary Neuropathy with Liability to Pressure, HNPP) and normal subjects. Try to understand the dosage effects of PMP22 gene on the pathohistologically morphometric parameters of their regenerative myelinated nerves such as cluster ratio (cluster number per 1000 myelinated fibers), axon diameter, g-ratio (axon diameter/fiber diameter) and scatter plot of g-ratio to axon diameter.

Background There were many reports

about the nerve pathohistologic analysis of CMT1A and HNPP in literatures, but no reports focus on their regenerative myelinated fibers.

Materials and Methods The study recruited 5 cases with PMP22 duplication, 6 cases with PMP22 deletion and 6 control subjects. PMP22 gene duplication or deletion was confirmed by “hot spot” detection by polymerase chain reaction (PCR) with allele-specific primers or microsatellites methods. Their bioptic specimens of sural nerve were examined by light microscope, electromicroscope, teased single fiber and histopathological morphometric analysis.

Results The results showed the patients with PMP22 duplication, whose cluster ratio, 9.51, 6.9, 16.7, 12.51 and 6.75, mean axon diameters of RMF, $1.83\pm 0.65\mu\text{m}$, $2.54\pm 1.06\mu\text{m}$, $3.03\pm 1.11\mu\text{m}$, $3.06\pm 1.26\mu\text{m}$ and $3.07\pm 0.97\mu\text{m}$, and g-ratio, 0.38 ± 0.11 , 0.51 ± 0.12 , 0.62 ± 0.11 , 0.51 ± 0.12 and 0.57 ± 0.13 respectively. G-ratio plot axon diameter scatter gram revealed RMF distributed out of the AIII fibers range to the AII fibers range; The patients with PMP22 deletion, whose cluster ratio, 0, 0, 0.48, 0, 1.03, 2.24, mean axon diameters of RMF, 0, 0, $1.8\pm 0.38\mu\text{m}$, $3.06\pm 0.95\mu\text{m}$, and 3.09 ± 1 , and g-ratio, 0, 0, 0.52 ± 0.08 , 0, 0.65 ± 0.09 , 0.71 ± 0.09 and 0.51 ± 0.12

respectively. G-ratio plot axon diameter scatter gram revealed RMF distributed within the AIII fibers range. The normal subjects whose cluster ratio, 0, 3.14, 1.75, 7.13, 7.42 and 7.63, mean axon diameters of RMF, $0, 2.4\pm 0.93\mu\text{m}, 2.0\pm 0.85\mu\text{m}, 1.64\pm 0.58\mu\text{m}, 2.44\pm 1.07\mu\text{m},$ and $1.6\pm 0.28\mu\text{m},$ and g-ratio, 0, $0.62\pm 0.09, 0.58\pm 0.1, 0.59\pm 0.1, 0.69\pm 0.08$ and 0.53 ± 0.06 respectively. G-ratio plot axon diameter scatter gram revealed RMF distributed within the AIII fibers range as well. The cluster ratio, mean axon diameters and g-ratio showed no statistically significance among these 3 groups of subjects.

Conclusions The pathohistologically morphometric analysis of RMF in subjects with different PMP22 gene dosage showed the decompensation of nerve regeneration in PMP22 duplication (CMT1A), but normal in PMP 22 deletion (HNPP) and normal subjects

83

癌症導致之周邊神經病變發生在糖尿病病患

林舜文 吳嘉倫
基隆長庚醫院 神經內科

Paraneoplastic neuropathy in a diabetic patient

Shun-Wen Lin, Chia-Lun Wu
Department of Neurology, Chang Gung Memorial Hospital, Keelung

Back ground Peripheral neuropathy is a major complication of diabetes mellitus, but any other causes of neuropathy could also happen in diabetic patients. A

neuropathy other than diabetics may also superimpose on an existing diabetic neuropathy.

Case report A 65-year-old male patient with 10 years type II diabetes mellitus history had suffered from insidious onset unsteady and feet numbness for 3 years. The numbness was exacerbating, ascending from toes to ankles with symmetric distribution. The neurological examination showed generalized reduced reflexes and absent ankles jerks. The muscle power, pin-prick and vibration sensation were also diminished distally. Nerve conductions and electromyographic study indicated a generalized sensorimotor peripheral neuropathy. Under the impression of polyneuropathy, a detail neuropathic risk factors survey, including immunological, oncological, and toxins screen, were done. The tumor marker screen showed elevated PSA level. Urology surgical intervention was performed and pathology proved to be a prostate adenocarcinoma. After the cancer removal surgery, the neuropathic sign/symptoms, including distal weakness and numbness, all showed dramatically improvement. The final diagnosis was paraneoplastic neuropathy, possible superimposed on a diabetic neuropathy. The pathology of paraneoplastic neuropathy was thought to be antibody direct against intra-cellular antigen in the cytoplasm

or nucleus in the neurons or extra-cellular antigen such as membrane channel.

Conclusion Peripheral neuropathy caused by any etiology could be happened, or superimposed on an existing neuropathy, in diabetic patients. Wild range screen studies are essential for the definite diagnosis. Even the pathogenesis of paraneoplastic neuropathies are immune mediated, results of conventional immunotherapy are always disappointed. The most effective treatment of paraneoplastic neuropathy is removal of the underlying malignancy.

84

Case report: CPT test 評估 Gabapentin

治療紫質症神經痛的成效

林鼎鈞 賴曉玲 黃彥筑 李建德 羅榮昇
嘉義長庚紀念醫院 神經內科

Concurrent perception threshold test for the evaluation of neuropathic pain in acute intermittent porphyria

Ting-Chun Lin, Shiao-Lin Lai, Yen-Chu Huang,
Jiann-Der Lee, Long-Sun Ro
Department of Neurology, Chang Gung
Memorial Hospital, Chiayi

Background To our knowledge, gabapentin treatment and using CPT tests to monitor neuropathic pain severity in AIP patients has not been reported. We used CPT testing to investigate the probable mechanisms and effects of gabapentin on AIP neuropathic pain.

Case Report A 28-year-old woman was admitted to a hospital for abdominal pain

and limb weakness. NCS showed sensory and motor axonal polyneuropathy, with the motor nerves more severely involved. Hallucination and generalized tonic-clonic convulsion episodes were also noted after admission. Her abdominal pain score, neuropsychiatric manifestations, and porphyrin biochemical data (2+, ALA: 70.91 mg/dL [reference values: 1.3–7 mg/dL], PBG: 184.87 mg/dL [reference values: 0–2 mg/dL]) obtained from 24-hour urine collection and axonal polyneuropathy were compatible with those for AIP. After hematin use, she demonstrated rapid clinical and biochemical improvement (including decreased urine levels of porphyrin, PBG, and ALA). Acute pain was relieved by analgesics such as morphine and meperidine. Unfortunately, she developed tolerance to morphine and meperidine. The chronic neuropathy pain was not well controlled. We designed a study to observe the effect of gabapentin on pain relief using CPT testing and visual analogue scales. Gabapentin was started at 300 mg/day and was slowly titrated to 1800 mg/day. After gabapentin use, the necessity of morphine or meperidine for acute pain decreased, fewer seizure episodes occurred, and improvement in limb pain was observed. There was a dose-dependent trend in current perception thresholds using a 2000-, 250- and 5-Hz stimulus. (Table 1 and Figure 1)

Conclusion CPT tests could provide information regarding the function of different sized fibers in peripheral neuropathy associated with gabapentin use. The results obtained in this study may provide an alternative for the evaluation and management of neuropathic pain in AIP patients.

Table 1: Current Perception Threshold (CPT) test data after gabapentin use

Dose	0	300	600	1200	1800
VAS	9	9	8	8	7
2000Hz	152	104	228	172	348
250Hz	69	46	72	65	174
5Hz	47	23	53	53	133

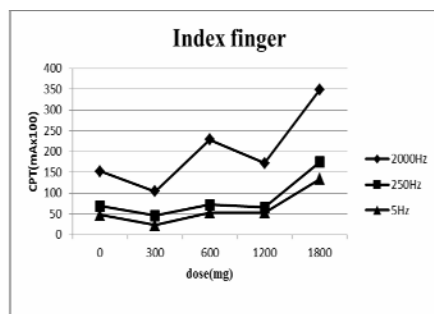


Fig. 1. The effect of gabapentin on current perception thresholds of the right index finger in patients with porphyria neuropathic pain. There is a dose-dependent trend in current perception thresholds using a 2000-, 250- and 5-Hz stimulus.

胃切除手術後之神經學併發症

曹維珈 郭弘周

林口長庚紀念醫院 神經內科

Neurological complication after gastric surgery: a report of two cases

Wei-Chia Tsao, Hung-Chou Kuo

Department of Neurology, Chang Gung

Memorial Hospital, Lin-Kou Medical Center

Background The neurological complication following gastric surgery is rare. We described two patients had severe neurological complications both in central and peripheral nervous systems after gastric surgery. The clinical picture, brain MRI and electrophysiological studies were also presented.

Case Report The first patient was a 33-year old woman who received Roux-en-Y surgery for morbid obesity six years before. Cervical myelitis-like syndrome, and an episode of amnesic syndrome were noted about 2 years after operation. This time she suffered from recurrent myelitis. Only relative low normal limitation of serum level in folate and 25-hydroxyvitamin D were noted. Her muscle strength had no response to pulse therapy, besides, nausea/vomiting developed after pulse therapy. Nerve conduction study and electromyography showed an acute motor axonal neuropathy. Intravenous vitamin B complex for 2 weeks as an intervention for acute stage and then oral multiple vitamin B was supplied for long term management. The

neurological symptom was much better during the 6 months follow-up period. The second patient was a 66 year-old man who undergone subtotal gastrectomy and Billroth II anastomosis 14 months before for gastric signet ring cell carcinoma. Weight loss of 6 kilograms in 2 months related to poor appetite was reported. He got gradual progression of weakness over legs for one month and rapid progression of limbs weakness within a week, proceeding to stupor, tetraplegia and ophthalmoplegia. Plasmaphoresis was arranged on the assumption of demyelinating diseases. Brain magnetic resonance imaging (MRI) revealed non-alcoholic Wernicke's encephalopathy, and vitamin B complex was given. Nerve conduction study showed severe axonal polyneuropathy. His neurological condition also got improvement during the 6 months follow-up period.

Conclusion We should put suspicion of nutritional deficiency in patients who had acute severe neurological syndromes involving both central and peripheral nervous systems after receiving gastric surgery several years later, especially who had concomitant gastrointestinal symptoms and weight loss. Intensive multiple vitamin B and balanced nutrition supplement could be benefit for them.

87

侷限性中樞暨周邊神經病變：不典型特殊個案討論

郭芷毓 張宏旭 呂榮國
林口長庚紀念醫院 神經內科

Concomitant Involvement of the Central and the Peripheral Nerve Systems in a Female with Undetermined Etiology

Chih-Yu Kuo, Hung-Hsu Chang, Rong-Kuo Lyu

Department of Neurology, Chang Gung Memorial Hospital, Lin-Kou Medical Center

Background We describe a case with a dominant clinical feature of sensory ataxia. Electrophysiology studies suggested involvement of the peripheral nervous system. A subsequent spinal MRI revealed non-enhanced lesions in the posterior column of the spinal cord. Extensive investigation showed no evidence of infections, neoplasms or autoimmune disorders. A transient improvement to intravenous immunoglobulin infusion was noted but the symptoms and signs otherwise persisted in spite of immunosuppressive or immunomodulative treatment.

Case Report A 32-year-old female complained acute onset followed by slowly progressive ascending numbness. This was followed by mild weakness of four limbs. After admission, her condition deteriorated and became dependent in standing or ambulation. Physiological examinations were unremarkable. Neurological examinations revealed no cranial nerve or cerebellar dysfunction. There was asymmetrical and mild weakness

without muscle wasting in the four limbs. Babinski sign was negative. Sequential sensory tests revealed progressive deterioration of the proprioceptive perception while the nociception was relatively spared. There were diffuse hyporeflexia, pseudoathetosis, a positive Romberg test and sensory ataxia. Routine hemogram and blood chemistry were unremarkable. There were also negative findings of endocrine studies, selective virus antibodies, autoimmune, infection disease and tumor markers. Serum and CSF protein electrophoresis were negative for paraproteins or monoclonal gamma globulins. A routine CSF study showed marked elevation of protein concentration. Nutrient and toxin survey were negative. No abnormality was detected in a whole body CT. Electrophysiological studies showed absence or marked amplitude decrease of sensory nerve action potential in the four limbs and were compatible with sensory dominant polyneuropathy or sensory neuronopathy. Autoimmune mediated neuropathy was suspected. Steroid, intravenous immunoglobulin infusion and plasmapheresis were given with a transient partial response but overall, there was no significant clinical improvement. In spite of clinical stationarity, there was gradual improvement of electrophysiological abnormality of nerve functions. A spinal MRI revealed long-segmental (C1 to T4) lesions without enhancement in the posterior column.

Discussion We report an unusual case who had a disorder involving the peripheral and central proprioceptive systems. No identified causes were found in spite of extensive evaluation. Although the response of therapies targeting on dysimmune diseases was unsatisfactory, we thought autoimmune factors, either humoral or cellular, may underlie the pathogenesis because of the specificity of the affected tissues.

88

僵直性肌陣攣運動失調症-個案報告

郭詠怡 甄瑞興 王毓禎 陳珮昀 林怡君
台北市立聯合醫院仁愛院區 神經內科

Opsoclonus myoclonus ataxia – a case report

Wing-Yee Kwok, Sui-Hing Yan, Yuh-Jen Wang,
Pei-Yun Chen, Yi-Chun Lin
Department of Neurology, Taipei City Hospital
Renai Branch

Background Opsoclonus myoclonus ataxia (OMA) is a rare neurological disorder. It appears to be the result of an autoimmune process involving the nervous system that includes opsoclonus along with diffuse or focal body myoclonus with or without ataxia and other cerebellar signs. OMA in adults may be paraneoplastic, parainfectious or idiopathic in origin.

Case Report A 50-year-old female was admitted due to sudden onset of blurred vision when she tried to fix her vision on a focal object in the early morning after she arrived from the U.S. on 27th September, 2012. The patient

had an URI attack one week before . On neurological examination ,conjugated dancing eyeballs was detected in different direction , and the condition was enhanced if the patient focused on one object. The patient also had paroxysmal left leg myoclonus and unstable gait one week later . Lumbar puncture showed inflammatory pattern with CSF WBC 15, glucose 87, protein: 50, LDH: 126. The result of serum HSV, EBV, HIV, TPHA/ RPR, ANA, C3, C4, Ig A, IgE, IgM, IgG were all within normal range. No malignant tumors were detected after brain MRI, tumor markers, GYN ultrasound, chest CT, whole body Ga-67 tumor and PET scan . Opsoclonus , myoclonus and ataxia did not improved after using steroid therapy initially but gradually showed response to Beclofen.

Conclusion Since no tumor was found after a series of examinations , parainfectious OMA following a flu like virus infection was considered .

89

韋格納肉芽腫對周邊神經系統的侵犯-醫學中心病例分析

黃俞華 郭弘周
林口長庚醫院 神經內科

Wegener's granulomatosis with peripheral nervous system involvement: A medical center based study

Yu-Hua Huang Hung-Chou Kuo
Department of Neurology, Chang Gung Memorial Hospital, Lin-Kou Medical Center

Objective Wegener's granulomatosis (WG) is a rare systemic autoimmune

disease with anti-neutrophil cytoplasmic antibody (ANCA)-associated vasculitis and granulomatous inflammation. We will give an overview of the clinical manifestations of the peripheral nervous system.

Methods Retrospective analysis of reviewed the medical records of all patients discharged from our hospital with a diagnosis of WG from January 2000 to December 2011. There were totally 14 patients, including 9 patients who definitely diagnosed by pathological study and 5 patients who diagnosed by positive serological test of C-ANCA and clinical manifestation. We reviewed the clinical, electrophysiological, radiological, and serological data.

Result In this study, 5 patients were identified to be associated with peripheral neuropathies out of 14 patients with WG. The nerve conduction studies showed 2 (14%) patients with axonal polyneuropathy; 1 patient with demyelination polyneuropathy (7%); 2 patients with mononeuropathy multiplex (14%)

Conclusion Nervous system manifestation in WG is less frequent than classical manifestations such as lung and kidney involvement. However, neurologic involvement is not uncommon in WG which requires

fast diagnostic work-up and early introduction of highly potent immunosuppression in order to prevent or reduce potential damage.

90

糖尿病周邊神經痛之治療:病患的期望與醫師的判斷

葉如芬

PATIENT EXPECTATIONS AND PHYSICIANS' JUDGEMENT IN THE TREATMENT OF DIABETIC PERIPHERAL NEUROPATHIC PAIN

Ju-Fen Yeh¹, Edith Schneider², Dan Ziegler³, Stefan Wilhelm², Alexander Schacht⁴, Frank Birklein⁵

¹ Presenting on behalf of Eli Lilly & Company, Indianapolis, IN(禮來股份有限公司 醫藥學術部)

² Medical Department Neuroscience, Lilly Deutschland GmbH, Bad Homburg

³ Deutsche Diabetes Zentrum, Heinrich-Heine Universität, Düsseldorf

⁴ Global Statistical Sciences, Lilly Deutschland GmbH, Bad Homburg

⁵ Klinik und Poliklinik für Neurologie, Johannes Gutenberg Universität, Mainz

Purpose Pain reduction is the main objective when treating patients with diabetic peripheral neuropathic pain (DPNP). However, DPNP is associated with further substantial patient burden which often is not appropriately addressed. Primary objective of this study was to evaluate which interference category from the Brief Pain Inventory (BPI) is most relevant from patients' perspective.

Method: Baseline data of a German prospective, non-interventional, 6 months study in DPNP patients starting or switching pain medication at the

discretion of the investigator. DPNP severity was evaluated using CGI-S (Clinician Global Impression-Severity), PGI-S (Patient Global Impression-Severity), and BPI. To evaluate the primary objective, patients were asked to rank each of the 7 BPI interference items for which they most expect improvement.

Result 2576 patients (mean age: 65.8 years) were enrolled by 307 physicians. Mean (SD) BPI average pain was 5.1(2.04). While the interference score was 4.8(2.18), items most impaired were 'walking ability' 5.5(2.60) and 'general activity' 5.4(2.37). The most relevant items for which patients expected improvement were 'general activity' (29.3%; 95%CI: 27.5%-31.0%) and 'walking ability' (24.4%; 95%CI: 22.8%-26.1%), followed by 'sleep' (14.7%), 'enjoyment of life' (13.6%), 'mood' (8.3%), 'normal work' (7.7%) and 'relations with other people' (1.9%). CGI-S assessment showed a moderate correlation with PGI-S (0.587; 95%CI: 0.562- 0.612), but weaker correlations with BPI severity (0.365; 95%CI: 0.331-0.398) and interference scores (0.420; 95%CI: 0.388-0.451).

Conclusion In addition to pain relief, this study identified 'general activity' and 'walking ability' as most relevant BPI interference items in which patients expect improvement from DPNP treatment.

侵襲性胸腺瘤引發之僵人症候群

葉建治 林精湛 蔡崇豪 黃匯淳

中國醫藥大學附設醫院神經部暨神經醫學實驗室

Stiff-person syndrome associated with invasive thymoma: a case report

Jian-Jhih Ye, Ching-Chan Lin, Chon-Haw Tsai,

Hui-Chun Huang

Neuroscience Laboratory, Department of Neurology, China Medical University Hospital, Taichung, Taiwan

Department of Oncology and Hematology, China Medical University Hospital, Taichung, Taiwan

Background The stiff-person syndrome is a rare neurologic disorder characterized by progressive paroxysmal axial and proximal limb rigidity and painful tonic spasms due to continuous motor unit activity. It has been reported to be associated with autoimmune diseases or paraneoplastic diseases such as thymoma, adenocarcinoma of breast, adenocarcinoma of colon, Hodgkin's lymphoma, small-cell carcinoma of the lung. Herein, we report a case of stiff-person syndrome associated with invasive thymoma treated with chemotherapy and prednisolone with good response.

Case Report A 47-year-old woman with a history of invasive thymoma was admitted because of falling backward repeatedly and unexpectedly due to episodes of sudden stiffness in bilateral lower extremities for two weeks. The episodes of stiffness were accompanied by paroxysmal painful muscle spasms, involving proximal lower extremities chiefly, which was precipitated by

sudden movement ignition and sound stimuli. Neurologic examination revealed rigidity and brisk deep tendon reflexes in the lower extremities, and bilateral plantar extensor response. Laboratory data showed anti- glutamic acid decarboxylase (anti-GAD) antibody level was >300 u/mL(normal<1.0). Computer tomography of the chest revealed one huge anterior mediastinal tumor in prevascular space. Invasive thymoma, type B2, with bilateral pleural invasion, lung metastasis and pericardium invasion was considered. The surface electromyography did not detect a continuous muscle discharge at rest in the lower extremities, but episodic motor unit potentials during paroxysmal painful muscle spasms precipitated by unexpected auditory stimuli were recorded in bilateral quadriceps and tibialis anterior muscles. According to the combination of clinical manifestations and the elevated anti-GAD antibody level, the diagnosis of stiff-person syndrome was made. The patient was treated with baclofen (80 mg/day) and rivotril (2 mg/day) with good response, but the drugs was titrated progressively according to her progressive condition. She was not allowed to receive thymectomy due to the invasive status of her thymoma. Instead, she was treated with regimen as three courses of chemotherapy, using 90 mg cisplatin and 150mg etoposide per day. Her painful tonic

spasm was more severe after the first regimen of chemotherapy, but was subsided after accompanied with dexamethasone treatment. Her lower legs rigidity, hyper-reflexia and painful tonic spasms were subsided progressively and we had tapered the baclofen, rivotril and prednisolone slowly. She was asymptomatic now during one-year follow-up visit.

Conclusion It is important to survey and treat the underline disease beneath stiff-person syndrome.

92

自發性後方腔室症候群造成之急性坐骨神經病變

蔡睿蕙 袁瑞昱 許昭俊 游家銘 高克培
何俊森
台北醫學大學附設醫院神經科

Acute sciatic neuropathy due to spontaneous posterior compartment syndrome

Jui-Ping Tsai, Rey-Yue Yuan, Jau-Jiuan Sheu,
Jia-Ming Yu, Ko-Pei Kao, Chun-Sum Ho
Department of Neurology, Taipei Medical
University Hospital

Background The common causes of sciatic neuropathy have been reported as hip surgery, diabetic mononeuropathy, acute external compression, trauma or idiopathic. We presented here an infrequent cause, about a case after sleeping on lounge chair for 8 hours, secondary to spontaneous posterior compartment syndrome of the thigh.

Case Report A 45 years old healthy male had right leg paralysis after sleeping

on lounge chair for 8 hours while waking up in the morning. At that time, he noticed a severe swelling over posterior aspect of right thigh, with ecchymotic and pain. He insisted drank bottles of beer without drunk the last night and denied any history of systemic diseases, coagulopathies, medication, blunt trauma or exercise. Due to right foot drop and subsequent walking difficulty, he received conservative treatment in the district-hospital and was transferred to our hospital after 2 weeks. At interview, he appealed of right anterior tibialis muscle and hip tenderness. Mild weakness (4/5) of right hip flexion/extension, knee extension/flexion was noted but ankle plantarflexion /dorsiflexion and big toe extension were completely paralyzed (0/5), together with hypesthesia of L5 dermatone of right lower leg. Pelvic magnetic resonance imaging showed extensive ischemic muscular necrosis with right sciatic nerve compression, indicated rhabdomyolysis. Symptoms as right foot drop and paraesthesia showed poor recovery under medication and rehabilitation after discharge.

Conclusion A clinical diagnosis of spontaneous atraumatic posterior compartment syndrome was made, base on the patient's history and clinical presentation. If an early surgical intervention had been

performed, the patient might have different outcomes.

93

侵犯性胸腺瘤相關之僵人症候群併發急性呼吸衰竭

蕭丞宗 蔡清標 林恭平 尤香玉 李宜中
台北榮總神經內科

Stiff-person syndrome associated with invasive thymoma and complicated by acute respiratory failure

Cheng-Tsung Hsiao, Ching-Piao Tsai, Kon-Ping Lin, Hsiang-Yu Yu, Yi-Chung Lee
The Neurological Institute, Taipei -Veterans General Hospital

Background Stiff-person syndrome is characterized by progressive rigidity of the axial musculature, superimposed by painful spasms with an exquisite sensitivity to external stimuli. It can be paraneoplastic sometimes and the coexistence of stiff-person syndrome and thymoma with or without myasthenia gravis has been previously characterized. The respiratory function is rarely compromised in stiff-person syndrome. Herein, we report a patient with malignant thymoma presenting with progressive general malaise and acute respiratory failure as the main manifestations of the paraneoplastic stiff-person syndrome.

Case Report A 44-year-old lady with recurrent invasive thymoma visited the emergency room due to progressive axial stiffness and general malaise for five months. She was able to deal with the activities of daily living until double vision occurred about one month before

she visited ER. Because of the difficulty in chewing, she became unable to have a meal smoothly. About two weeks after the onset of diplopia, intermittent jerk of four extremities developed with increasing frequency and intensity, which interfered her walking and she became bed-bound. At the same time, she had frequent general painful spasms, which were usually provoked by movements. On the neurological examination, the patient had normal consciousness and cognition, no specific cranial nerve signs, almost normal muscle strength, generalized hyper-reflexia, rigid muscle tone, normal coordination, and no sensory deficit. Repeated episodes of four limbs jerks and an opisthotonus followed by hypercapnia respiratory failure happened during observation, so she received endotracheal intubation with mechanical ventilator support. During the hospitalization, the video-EEG with surface EMG recorded events characterized by generalized myoclonic jerk, mainly on trunk and sometimes caused generalized stiffness. The titer of serum anti-GAD antibody is 121.50 U/mL (reference: < 1 U/mL). The diagnosis of stiff-person syndrome is established on the base of clinical manifestation and a positive serum anti-GAD antibody. The initial treatment with Methylprednisolone pulse therapy (1g/day for 5 days) and five course of plasmapheresis had only little effect.

The condition began to obviously improve after administration of intravenous immunoglobulin (IVIG: 0.4g/kg). The axial stiffness subsided and the patient received extubation of endotracheal tube smoothly. However, the patient still had general spasm once daily, although treated adjuvant with Clonazepam, Baclofen, Levetiracetam, and Pregabalin. The symptoms were totally resolved after she received four courses of chemotherapy with the regimen of Cyclophosphamide-Vincristine, and plus Prednisolone for the malignant thymoma.

Conclusion Generalized muscle spasms could result in acute respiratory failure in stiff-person syndrome. In addition to plasmapheresis, IVIG should be considered as an alternative therapeutic choice in stiff-person syndrome. As a GABA agonist, Pregabalin also have a temporal effect to relieve symptoms for stiff-person syndrome. It is still necessary to aggressively manage underlying malignancy for eradicating the stiff-person syndrome with paraneoplastic oringin.

94

河豚毒中毒以格林-巴利徵候群表現

¹戴逸承 ²黃登福 ¹陳彥文 ¹崔煥文

¹義大醫院 神經科

²國立海洋大學 生命科學系

Tetrodotoxin Intoxication mimicking Guillian-Barre syndrome

¹Yi-cheng Tai, M.D., ²Deng-fwu Hwang, Ph.D.,

¹Yen-wen Chen, M.D., ¹Huan-wen Tsui, M.D.

¹Department of Neurology, E-DA Hospital / I-Shou University, Kaohsiung, Taiwan

²Department of Food Science, National Taiwan Ocean University, Keelung, Taiwan

Background The 45 year-old man, with untreated diabetes for 3 years, complained of acute dizziness, vertigo, nausea, and vomiting half an hour after taking over 200 pieces of spiral sea shells captured in southern Taiwan Strait. Soon after, he had circumoral numbness and dead skin sensation in fingers and toes. The numbness ascended up to forearms on the next day when he came to our emergency department.

Case Report On examination, there was decreased muscle strength (4/5 in MRC scale) in distal upper limbs and decreased pinprick sensation in hands, feet, and the middle area of the chest and abdomen. Impaired joint position and vibration sensation developed in the following 1 to 2 days. All blood tests including biochemistry, VDRL, and HIV were unremarkable. Nerve conduction study showed length-dependent sensori-motor polyneuropathy without evidence of demyelination. All symptoms gradually subsided in 9 days after intravenous hydration.

Conclusion The sea shells were recognized as *Niotha clathrata* and *Zeuxis scalaris*. Tetrodotoxin was found in the remnants of *Niotha clathrata* (82±39 MU) and *Zeuxis*

scalaris (129±65 MU), the patient's urine (1.28ng/mL), and stool (1.79ng/mL). Both species are distributed in India Ocean, Red Sea, and Southeast Asia, including Taiwan. The major reported presentations of sea shell TTX intoxication were acute progressive circumoral numbness, dizziness, hand numbness, ataxia, and nausea, as those of our patient. These symptoms may mimic Guillian-Barre syndrome and thus TTX intoxication should be considered as one of the differential diagnosis of Guillian-Barre syndrome.

95

在尤塞氏症候群病人身上表現免疫性多發神經病變

謝宗達 張宏旭 羅榮昇 張國軒
林口長庚紀念醫院 神經內科

Immune-mediated polyneuropathy in a patient with Usher syndrome

Tsung-Ta Hsieh, Hong-Shiu Chang, Long-Sun Ro, Kuo-Hsuan Chang
Department of Neurology, Chang Gung Memorial Hospital and University College of Medicine, Lin-Kou Medical Center

Background Usher syndrome is an autosomal recessive genetic disorder characterized by progressive sensorineural deafness and retinitis pigmentosa. A number of neuropsychiatric presentations have been shown in the patients with Usher syndrome. However, polyneuropathy has not been seen in those with Usher syndrome

Case Report A 26-year-old male had progressive visual loss caused by retinitis

pigmentosa since the age of 5, and hearing impairment since the age of 15. This time, he began to develop acute bilateral legs weakness and distal limbs numbness, which impaired his walking in two weeks. Vaccination, infectious event or diarrhea was not found before the onset of limbs weakness. There was no remarkable family history or abnormal developmental milestones. His physical examinations revealed impairments of pinprick, thermal, joint position and vibration senses over all limbs. Mild weakness (MRC grade 4) was noted over lower limbs. He had diffuse areflexia and sensory ataxia. Cerebrospinal fluid revealed albuminocytologic dissociation (protein 302.4 mg/dL, leukocyte count 0 uL). Results of his nerve conduction study were compatible with a sensory-predominant axonal polyneuropathy. His visual evoked potential demonstrated prolonged P100 on both sides. Treatment with double-filtrating plasmapheresis significantly improved his sensory impairment and gait disturbance.

Conclusion This is the first case report about the presentation of immune-mediated polyneuropathy in the patients with Usher syndrome. More clinical studies should be performed to clarify the association between acute sensory neuropathy and Usher syndrome.

96

先天性肌強直：關於兩例偶發性病例報告

簡士超 簡浴沂
林口長庚醫院神經內科

Myotonia congenita: A report of 2 sporadic cases

Chien Shih Chao Chien Yu Yi
Department of Neurology, Chang Gung Memorial Hospital, Linkou, Taiwan

Background Generally speaking, the causative gene for classic myotonia congenita is CLCN1 gene, and, thus far, over 60 mutations in this gene have been identified. However, disorders, meet criteria of myotonia congenita, have different kinds of clinical presentations, for example, the response of myotonia to medications, the age of onset, or the pattern of attack. We are curious to know the factors causing these differences.

Case report We have studied 2 sporadic cases of myotonia congenita with clinical features resembling, as well as differing from, most cases of autosomal recessive myotonia congenita. Both patients progress slowly during childhood and adolescence, neither presents as muscular dystrophy, and both have myotonic discharges on EMG, rather high serum CK levels, and type 1 muscle fiber atrophy on muscle biopsy.

Result/Conclusion One has herculean appearance whose myotonia is alleviated by both mexiletine and acetazolamide, and the other is short but not stocky whose myotonia response only to

acetazolamid. Their family histories were reviews and genetic analyses were performed.

神經基因學

97

血漿 FGF21 在小腦萎縮症病患與粒線體疾病病患之表現情形

巫錫霖¹ 黃靜珊² 鄭文玲² 劉青山^{1,2,3}

¹.財團法人彰化基督教醫院 神經醫學部

².財團法人彰化基督教醫院 血管暨基因體研究中心

³.中國醫藥大學中西醫學結合研究所

FGF21 in ataxia patients with spinocerebellar atrophy and mitochondrial disease

Shey-Lin Wu¹, Ching-San Huang², Wen-Ling Cheng², Chin-San Liu^{1,2,3*}

¹.Department of Neurology, Changhua Christian Hospital, Changhua, Taiwan

².Vascular and Genomic Center, Changhua Christian Hospital, Changhua, Taiwan

³.Graduate Institute of Integrated Medicine, College of Chinese Medicine, China Medical University, Taichung, Taiwan

Objective Serum fibroblast growth factor 21 (FGF21) was proven to be a useful biomarker for the presence of mitochondrial neuromuscular disease.

Methods In the present study, we used the difference in the serum FGF21 level to differentiate between ataxia patients with hereditary spinocerebellar atrophy (SCA-ataxia) and those with mitochondrial syndrome (Mito-ataxia). Patients with SCA-ataxia (SCA2, SCA3) and Mito-ataxia (MELAS, MERRF, LHON, maternal inherited hearing impairment mtDNA A1555G mutation) were

recruited in this study. All SCA-ataxia patients revealed a consistent pattern of cerebellar atrophy. On the contrary, some of the Mito-ataxia patients exhibited a vascular lesion with cerebellar infarction.

Results An extremely high level of serum FGF21 was found in the Mito-ataxia patients with MERRF and MELAS diseases, but not in patients with SCA-ataxia or LHON/mtDNA A1555G mutation. The positive trend correlation between the mtDNA heteroplasmy and the level of serum FGF21 was indicated in either MERRF ($P = 0.003$, $r = 0.923$) or MELAS ($P = 0.070$, $r = 0.566$) patients.

Conclusion The serum FGF21 level can be applied as the first molecular screening in patients with hereditary ataxia and neuromuscular degeneration prior to mass genetic screening.

98

GNB4 基因突變會造成顯性中間型遺傳性運動感覺神經病變

李宜中¹ 高閻仙² 宋秉文¹ 張鳴宏³ 林恭平²

¹台北榮民總醫院 神經醫學中心

²陽明大學生命科學院

³台中榮民總醫院 神經內科

Mutations in *GNB4* cause Dominant Intermediate Charcot-Marie-Tooth disease

Yi-Chung Lee¹, Lung-Sen Kao², Bing-Wen Soong¹, Ming-Hon Chang³, Kon-Ping Lin¹

¹The Neurological Institute, Taipei Veterans General Hospital

²School of Life Science, National Yang-Ming University

³Division of Neurology, Taichung Veterans General Hospital

Objective To identify the causative gene for a novel type of dominant intermediate Charcot-Marie-Tooth disease (DI-CMT.)

Background We previously characterized a three-generation Chinese family afflicted with a DI-CMT, and mapped the locus of the candidate gene to chromosome 3q28-q29.

Methods Exome sequencing was utilized to identify the mutation causing CMT in this family. We further screened the index patients of 88 families selected from 251 CMT pedigrees after excluding mutations in the common CMT causative genes. Mutant gene products were surveyed on human sural nerve samples by immuno-histochemistry and in vitro to investigate their functional impact.

Results We identified a heterozygous p.G53D mutation in the Guanine nucleotide-binding protein subunit beta-4 gene (*GNB4*) that co-segregated with the CMT phenotype in the original family. Further sequence analysis identified a de novo *GNB4* mutation, p.K89E, in another CMT patient. Guanine nucleotide-binding protein beta-4 subunit (Gβ4) is abundantly expressed in the axons and cytoplasm of Schwann cells of sural nerves. In a functional assay for Gβ4, in contrast to the wild-type Gβ4 which

facilitates the bradykinin-induced cytosolic inositol triphosphate (IP3) production and intracellular calcium concentration elevation, both mutant proteins, Gβ4 G53D and Gβ4 K89E, inhibit the bradykinin-induced signaling.

Conclusion This study identified *GNB4* as a novel gene that, when mutated, causes a CMT phenotype. Heterozygous *GNB4* mutations occurred in 0.8% of our patients with CMT. *GNB4* mutations cause CMT by abolishing the Gβ4-related G-protein couple signaling, which may play an important role in the pathogenesis of CMT.

99

KCND3 基因的序列變異是引起第二十二型脊髓小腦運動失調症的原因

李宜中¹ 黃彥華² 連正章³ 宋秉文¹

¹台北榮民總醫院暨國立陽明大學 神經內科, ²國立陽明大學系統及合成生物學中心, ³國立陽明大學神經科學研究所

Mutations in *KCND3* cause spinocerebellar ataxia type 22

Yi-chung Lee,¹ Yen-hua Huang,² Cheng-chang Lien,³ Bing-wen Soong¹

¹Department of Neurology, National Yang-Ming University School of Medicine and Neurological Institute, Taipei -Veterans General Hospital

²Department of Biochemistry and Center for Systems and Synthetic Biology, National Yang-Ming University, Taipei, Taiwan

³Institute of Neuroscience, National Yang-Ming University, Taipei, Taiwan

Objectives To identify the causative gene in SCA22, an autosomal dominant cerebellar ataxia mapped to chromosome 1p21-q23.

Subjects and Methods We previously characterized a large Chinese family with progressive ataxia designated SCA22. The disease locus in a French family and an Ashkenazi Jewish American family was also mapped to this region. Members from all three families were enrolled. Whole exome sequencing was performed to identify candidate mutations, which were narrowed by linkage analysis and confirmed by Sanger sequencing and co-segregation analyses. Mutational analyses were also performed in 105 Chinese and 55 Japanese families with cerebellar ataxia. Mutant gene products were examined in a heterologous expression system to address the changes in protein localization and electrophysiological functions..

Results We identified heterozygous mutations in the voltage-gated potassium channel Kv4.3-encoding gene *KCND3*: an in-frame three-nucleotide deletion c.679_681delTTC p.F227del in both the Chinese and French pedigrees, and a missense mutation c.1034G>T p.G345V in the Ashkenazi Jewish family. Direct sequencing of *KCND3* further identified three mutations, c.1034G>T p.G345V, c.1013T>C p.V338E and c.1130C>T p.T377M, in three Japanese kindreds. Immunofluorescence analyses revealed that the mutant p.F227del Kv4.3 subunits were retained in the

cytoplasm, consistent with the lack of A-type K⁺ channel conductance in whole-cell patch-clamp recordings. Haplotype analyses revealed that there was no common founder between the pedigrees from Taiwan and French.

Conclusion Our data identify the cause of SCA22 in patients of diverse ethnic origins as mutations in *KCND3*. These findings further emphasize the important role of ion channels as key regulators of neuronal excitability in the pathogenesis of cerebellar degeneration.

100

帕金森氏病合併 VPS35 基因顯現臨床異質表徵

林瑞榮 樂國柱

國際帕金森氏病基因流行病研究協會
竹山秀傳醫院 神經科

Clinical Heterogeneity Associated with VPS35 Gene in Parkinson Disease

Juei-Jueng Lin, Kuo-Chu Yueh, on behalf of the Genetic Epidemiology of Parkinson's disease Consortium

Departments of Neurology, Chushang Show-Chwan Hospital, Nantou, Taiwan

Objective A large multi-centre study to analyze clinical manifestations in patients with Parkinson's disease (PD) with pathogenicity of vacuolar protein sorting 35 (VPS35) variants in diverse populations worldwide.

Background Current studies identified a mutation (p.Asp620Asn) in the vacuolar VPS35 gene responsible for an autosomal dominant Parkinson disease. The clinical manifestations in the

affected patients often presented with tremor-predominant levodopa-responsive parkinsonism. However, clinical variants in different populations and non-motor symptoms in this kind of pathogenicity have not yet been reported.

Methods A total of 15383 individuals (8870 cases and 6513 controls).form 23 sites representing 19 countries in the Genetic Epidemiology of Parkinson disease (GeoPD) Consortium were included for genetic analysis for the pathogenicity of VPS35 gene variants in this study. Overall, there were mutations with p.Asp620Asn in seven cases, p.Leu774Met in six cases and one control, p.Gly51Ser in three cases and two controls. One o PA patients had double mutations (p.Asp620Asn and p.Leu774Me). We further analyze the clinical manifestations, including motor and non-motor symptoms, in those 15 PD patients carried pathogenic variants and two controls..

Results All PD patients were clinically diagnosed with PD. Two out of seven patients carrying the p.Asp620Asn variant presented without any family history for PD. Affected individuals exhibited classical symptoms of PD (resting tremor, bradykinesia, rigidity). The clinical diagnosis of PD was made by movement disorder specialists who used UK brain bank criteria for PD. Non-motor symptoms were present in

the majority of PD patients carrying a pathogenic variant. Interestingly, hallucinations and dementia were also observed in one asymptomatic carrier

Conclusion Our study represents the first evidence for the clinical heterogeneity associated with VPS35 in PD patients among different populations worldwide.

101

第三型小腦萎縮症病患之 OPA1 與 PINK1 基因異常表現

劉青山^{1,2,3} 鄭文玲²

¹ 財團法人彰化基督教醫院 神經醫學部

² 財團法人彰化基督教醫院 血管暨基因體研究中心

³ 中國醫藥大學中西醫學結合研究所

Over Expression of Opal and PINK1 Genes in Patients with SCA3

Chin-San Liu^{1,2,3*}, Wen-Ling Cheng²

¹ Department of Neurology, Changhua Christian Hospital, Changhua, Taiwan

² Vascular and Genomic Center, Changhua Christian Hospital, Changhua, Taiwan

³ Graduate Institute of Integrated Medicine, College of Chinese Medicine, China Medical University, Taichung, Taiwan

Objective Mitochondrial fusion, fission and mitophagy may be involved in neuropathology of spinocerebellar ataxia type 3 (SCA3).

Methods Ten healthy subjects and twenty SCA3 patients were recruited. Scale for the Assessment and Rating of Ataxia was applied for clinical evaluation. The CAG repeat number of ataxin-3, expression of mitochondrial fusion genes (*OPA1* and *MFN2*), fission genes (*DNM1L* and *FIS1*) and mitophagy genes (*PINK1*, *PARK2* and *RHOT1*) were evaluated by RT-PCR.

Results Significantly increased of

express of *OPA1* ($p < 0.05$) and *PINK1* ($p < 0.05$) were noted in leukocyte of SCA3 patients compared with healthy subjects and corresponding to the expansion of CAG repeat number and the disease severity of SCA3.

Conclusion Mitochondrial fusion and mitophagy are related to the pathogenesis of SCA3 which may capitalize the mechanism of stress-induced mitochondrial fusion to reserve the availability of mitochondria in recycling as well as quality control. Further investigation is needed for ascertaining the *OPA1* and *PINK1* expression levels as biomarkers for SCA3 disease progression.

神經生理及電生理學

102

大腦預設模式網路活性之一致性及振動性在早期阿茲海默症與輕度知能障礙患者的不同：以腦波研究

王毓禎¹ 蕭富榮²

台北市立聯合醫院神經科¹ 及教研部²

Altered Oscillation and Synchronization of Default-Mode Network Activity in Mild Alzheimer's Disease Compared to Mild Cognitive Impairment: An Electrophysiological Study

Yuh-Jen Wang¹, Fu-Jung Hsiao²

¹ Department of Neurology and ² Department of Education and Research, Taipei City Hospital, Taipei, Taiwan

Objective To examine whether electroencephalography (EEG) is as useful as functional magnetic resonance imaging (fMRI) in investigating brain default mode network (DMN) activity and differentiating early stage AD from

mild cognitive impairment (MCI).

Background Some researchers have suggested that the DMN plays an important role in the pathological mechanisms of Alzheimer's disease (AD). However, fMRI is not available in every institution. Instead, EEG is more accessible.

Methods EEG was recorded from 21 mild AD and 21 mild cognitive impairment (MCI) patients during an eyes closed, resting-state condition. The spectral power and functional connectivity of the DMN were estimated using a minimum norm estimate (MNE) combined with fast Fourier transform and imagery coherence analysis.

Results Our results indicated that source-based EEG maps of resting-state activity show alterations of cortical spectral power in mild AD when compared to MCI. These alterations are characteristic of attenuated alpha or beta activities in the DMN, as are enhanced delta or theta activities in the medial temporal, inferior parietal, posterior cingulate cortex and precuneus. With regard to altered synchronization in AD, altered functional interconnections were observed as specific connectivity patterns of connection hubs in the precuneus, posterior cingulate cortex, anterior cingulate cortex and medial temporal regions. Moreover, posterior theta and alpha power and altered connectivity in

the medial temporal lobe correlated significantly with scores obtained on the Mini-Mental State Examination (MMSE).

Conclusion EEG is a useful tool for investigating the DMN in the brain and differentiating early stage AD and MCI patients. This is a promising finding; however, further large-scale studies are needed.

103

以穿顱直流電刺激右背外側前額葉皮質調節空間工作記憶的干擾作用

吳怡真¹ 張期富² 曾祥非² 阮啟弘² 白明奇³
林宙晴³

¹ 國立成功大學附設醫院斗六分院神經科

² 國立中央大學認知神經科學研究所

³ 國立成功大學附設醫院神經部

Modulating the Interference Effect on Spatial Working Memory by Applying Transcranial Direct Current Stimulation over the Right Dorsolateral Prefrontal Cortex

Yi-Jen Wu¹, Chi-Fu Chang², Philip Tseng², Chi-Hung Juan², Ming-Chyi Pai³, Chou-Ching Lin³

¹ Division of Neurology, National Cheng Kung University Hospital, Dou-Liou Branch

² Institute of Cognitive Neuroscience, National Central University

³ Department of Neurology, National Cheng Kung University Hospital

Objective Spatial working memory (SWM) is the ability to temporarily store and manipulate spatial information. It has limited capacity and is quite vulnerable to interference. Dorsolateral prefrontal cortex (DLPFC) is one of the brain regions in the SWM network but its role in SWM is still

under investigation. This study investigated the role of the right DLPFC in processing the interference effect on SWM.

Methods Eleven healthy young adults were enrolled. Transcranial direct current stimulation (tDCS) noninvasively provides polarity-specific electric stimulation to the targeted brain region. Anodal tDCS (1.5mA) was applied on the right DLPFC for 15 minutes before participants performed a forward- and backward-recall computerized Corsi Block Tapping task (CBT), both with and without a concurrent motor interference task (the modified Luria manual sequencing task). The response accuracy for the memorized span and reaction time were recorded.

Results With tDCS, participants' reaction time improved in all four conditions (forward, backward, forward with interference, and backward with interference). Although there was a consistent decline of memory span in the motor interference conditions, tDCS significantly improved participants' SWM span (sham group: 5.1, tDCS group: 5.7, $p < 0.05$) in the "backward-recall with motor interference" condition, which was the most difficult condition.

Conclusion This study demonstrated that the motor interference degraded SWM performance. Right DLPFC anodal

tDCS shortened the reaction time of SWM performance and improved SWM capacity in high-difficulty conditions with concurrent interference. These results suggest the right DLPFC plays a crucial role dealing with the interference effect for spatial working memory.

104

引發多發性神經病變及認知功能失調病例報告

林圻域 蔡松彥

彰化基督教醫院 雲林分院 神經內科

Polyneuropathy and possible cognitive dysfunction induced by exposure to ethylene oxide **Ethylene oxide**

Background Ethylene oxide is a well-known neurotoxin which cause polyneuropathy. The involvement of central nervous system is also reported in the past. In this case report, the patient suffered from autonomic dysfunction, including abdominal fullness and impotence as first symptoms after exposure to Ethylene oxide for 4 years.

Case Report A 47 y/o married man visited our outpatient department due to progressive bilateral calf cramp and acroparesthesia for more than one month. He has been a sterilizer worker exposed to ethylene oxide for 4 years. Initially, he experienced abdominal fullness, poor appetite and impotence in the first week of June and followed by bilateral calf cramp, which got

worse in the night. One month later, he suffered from acroparesthesia and poor attention also. There were no fever and other autonomic dysfunctions including nausea, vomiting, diarrhea, urinary or bowel movement dysfunction. Neurological examination revealed intact of cranial nerve, full strength of limbs muscle power, decreased deep tendon reflexes, distal sensory impairment, predominantly lower limbs, including all modalities which are pinprick, light touch, vibration and joint position sense, and positive Romberg's test. The brain CT and cervical/lumbosacral MRI did not show abnormal findings. The NCV study found polyneuropathy. The ABEP study revealed bilateral brain stem dysfunctions. He was diagnosed as toxic polyneuropathy caused by ethylene oxide. After using personal protective mask during working, his symptoms including bilateral calf cramp, acroparesthesia and impotence were improved.

Conclusion Neuropsychologic impairment and Peripheral neuropathy after long term exposure to EtO has been documented in past series report. This patient has autonomic dysfunction, including abdominal fullness, nausea, vomiting and impotence. In addition, we also complete evaluated EtO toxic damage to nerve system, including anatomic and functional study. We also known that CNS and PNS involvement has reversible effect, but autonomic effect has uncertain damage in the past

case report and this case.

105

足底振動改變單腳站立時的姿勢控制

林聖皇 錢振愷 李筱媛 黃信祺 郭藍遠 楊志鴻

財團法人佛教慈濟綜合醫院神經內科
慈濟大學醫學院物理治療學系
高雄醫學大學醫學院運動醫學系

Foot Plantar Vibration Changes Postural Control With One-Leg Standing

Sheng-Huang Lin, Chen-Kai Chien,
Hsiao-Yuan Lee, Sin-Chi Huang, Lan-Yuen Guo, Chich-Huang Yang
Department of Neurology, Buddhist Tzu Chi General Hospital; Department of Physical Therapy, College of Medicine, Tzu-Chi University; Faculty of Sports Medicine, College of Medicine, Kaohsiung Medical University

Abstract Postural control is critical in human upright activities (e.g. standing, walking and running), which is an integral output of musculoskeletal, motor and sensory nervous system. Notably, somatosensory input of plantar area is an essential role in postural control and compromised in patients with polyneuropathy. The purpose of this study was to examine whether plantar vibration may alter postural control in people with plantar desensitization after ice immersion. A single-leg upright posture over a forceplate was selected to examine the capability of postural control under 3 conditions (pre-intervention, plantar desensitization, and with vibration). The preliminary results have shown that significant reduced postural control in both eyes open and eyes

close conditions were found in people with plantar desensitization (after ice immersion), which indicating increased area, root mean square and mean velocity of center of pressure (COP) ($p < 0.05$). Meanwhile, plantar vibration intervention did not improve the parameters (Area, RMS and MV) of COP. The findings confirm the role of plantar sensory input is a key role to mediate the postural control. In contrast, plantar vibration over the calcaneus provides adverse effect on the postural control in a single-leg upright standing posture.

癲癇與腦波

106

巴金森氏病臨床第五期之高齡老婦左上牙齦蜂窩性組織炎合併骨髓炎以全身不自主抽搐表現

王崇仁¹ 賴達昌² 彭志鋼³
振興醫療財團法人振興醫院¹ 老年醫學科² 神經內科³ 牙科

An Parkinson's Disease Clinical Stage Five Old Lady Left Upper Gum Cellulitis and Osteomyelitis Manifested as Generalized Involuntary Twitching

Chung-Jen Wang¹, Ta-Chang Lai², Tzi-Kang Peng³
Division of Geriatrics¹, Division of Neurology²,
Department of Dentistry³, Cheng Hsin General Hospital

Background We reported a Parkinson's Dz clinical stage V female patient suffered from severe infection of the gingivae, presented as atypical toxic symptom and sign.

Case Report One 85-year-old woman,

suffered from PDz for more than 10 years. Also medical Hx of CAD, old CVAs, depression disorder, DJD of T-L spine with scoliosis and marked kyphosis, T12-L1 compression Fx, osteoporosis with T-score: -2.5 to -2.7, VHD, HCVD, chronic liver Dz, senile anemia, calcified tendinitis of Rt supraspinatus, chronic paranasal sinusitis.....etc. Generalized twitching of all limbs and the trunk occurred during regular OPD visit. Seizure disorder was concerned and was admitted in the ward at once. After hospitalization, mentality was clear but poor and dull responses. No definite cerebral or cerebellar dysfunction. Brain MRI disclosed many old lacunar infarcts with moderate cerebral cortical atrophy. EEG told us no epileptic focus. Biochemical studies, including electrolytes, thyroid function test, Vit B12 & folate check-up were within normal limits except high sensitivity of C-reactive protein (CRP-HS) was up from 0.37 to 1.51 to 9.53 (normal <0.80 mg/dl). The leucocyte was around 5500 to 7800. The temperature was never over 38°C. No evidence of UTI, pneumonia or hepato-biliary tract inflammation. We tried Depakine and Rivotril, the involuntary movement little improved. Pt just called help of dentist of Taipei-VGH for periodontal problem about one month prior to this admission. We consulted our dentist and the diagnoses were left upper gum cellulitis with pus formation plus

osteomyelitis on #21-26 gingivae. Debridement and removal of necrotic bone with 20 stitches suture were performed. The pus culture were Staph. aureus, Kleb. pneumoniae, Acin. baumannii & Pseudo. aeruginosa. The pathological Dx showed picture of chronic osteomyelitis, composed of sequestrum surrounded by granulation tissue with aggregated of inflammatory cells & fibrosis. Tapimycine & Teicoplanin were prescribed at first and shifted to Ampicillin & Sulbactam 13 days later. After next 2 weeks, changed to Augmentin. The total hospital days was 6 weeks. Dental procedure intervened 10 days after admission, involunraty movement of whole body, low-grade fever, anorexia and constipation improved day by day.

Conclusion Physical Examination in the elderly, oral condition evaluation is omitted most of the time. In this case, we delayed over 1 week. Be careful, somewhere is under obvious infection in the senior person even no leukocytosis, no high fever and even NO PAINFUL SENSATION!

107

新腦皮質癲癇異常神經纖維與癲癇電生理活動的關聯研究

辛裕隆¹ 彭徐鈞²

¹花蓮慈濟醫院 神經內科

²國立中央大學 電機工程系

Abnormal Neural Networks Responsible for the Spread of Seizure Electric Activity: Studying the Reorganization of Nerve Fibers in

Patients with Focal Neocortical Epilepsy

Yue-Loong Hsin¹, Shu-Chun Peng²

¹Department of Neurology, Hualien Tzu Chi Medical Center

²Department of Electrical Engineering, National Central University

Objective If a patient has one seizure focus, the seizure semiology tends to be stereotyped. That supports the hypothesis: certain nerve fibers are responsible for the sequential propagation of seizure electric activity into the corresponded symptomatogenic areas. We analyzed tensor brain MRI, functional brain MRI, ictal intracranial EEG and cortico-cortical evoked potential (CCEP) study from patients with partial neocortical epilepsy. Our aim is to depict the neural networks, which correlate with seizure electric activity.

Methods Four patients with partial neocortical epilepsy and with normal brain MRI who underwent epilepsy surgery were studied. The location of each subcortical electrode extracted by rendering the post electrodes implantation brain CT was used to identify region of interest (ROI). We compared the regional differences of apparent diffusion coefficient (ADC) and fractional anisotropy (FA) of brain tensor images with age-matched normal subjects. We used resting-state functional MRI to detect high connection nodes and edges of neural networks over the ROI. The temporospatial dynamics of seizure

electric activity were represented by the individual seizure electrocorticographies. Then we conducted cortico-cortical evoked potentials study by paired-electrode stimulation to detect neurophysiological connectivity.

Results Increased diffusivity (increased ADC and decreased FA were the major finding in tensor imaging study) adjacent to the seizure-onset zone was found. The high connection nodes and edges of networks collocated with the seizure-onset zone and the regions with early seizure spread. High P1/N2 waves of CCEPs over the early seizure-spread regions were obtained by electrical stimulation over the seizure-onset zone.

Conclusion Changes in the white matter integrity of the regions with epileptic discharges indicated the microstructural reorganization of nerve fibers even the patients with no visible lesion in brain MRI. The spatial accordance of dynamics of seizure electric activity with specific functional network suggested a fundamental system underlying the direction of seizure propagation. Our findings support that there are designated routes in for conducting the electric current in the brain with focal epileptogenicity.

108

初診斷小兒癲癇病患用藥順從性之研究

邵時傑^{1,2} 賴嘉鎮² 高雅慧² 謝鎮陽^{2,3}
¹ 行政院衛生署基隆醫院 藥劑科

² 國立成功大學醫學院臨床藥學與藥物科技研究所

³ 台南新樓醫院 神經內科

Adherence to Antiepileptic Drugs in Pediatric Patients with Newly Diagnosed Epilepsy

Shih-Chieh Shao¹, Edward Chia-Cheng Lai²,
Yea-Huei Kao Yang², Cheng-Yang Hsieh^{2,3}

¹ Department of Pharmacy, Keelung Hospital, Department of Health, Executive Yuan, Keelung, Taiwan

² Institute of Clinical Pharmacy and Pharmaceutical Sciences, College of Medicine, National Cheng Kung University, Tainan, Taiwan

³ Department of Neurology, Sin-Lau Christian Hospital, Tainan, Taiwan.

Objective To investigate the adherence to antiepileptic drug (AED) therapy in pediatric patients with newly diagnosed epilepsy in Taiwan.

Background Adherence to AED for at least two years was important for patients with epilepsy to control their seizure. However, the information of AED adherence in pediatric patients with epilepsy was insufficient.

Methods A retrospective cohort study was conducted by using National Health Insurance Research Database (NHIRD) containing all pediatric patients who received AED for epileptic purpose. We included patients aged eighteen or less who were newly prescribed with AED from 1 Jan, 2005 to 31 Dec, 2008 and diagnosed with epilepsy within six months prior to or following the initiation of AED. Eligible patients were followed by each eight quarters of the two years

after AED initiation. We measured patients' adherence to AED therapy by calculating medication possession ratio (MPR) and defined as MPR less than 0.8 was non-adherent.

Results A total of 9,897 patients with 55.9% male gender and age of 8.9±5.1 years were identified. The mean MPR was 0.73 in the first quarter, and then 0.61, 0.58, 0.56, 0.55, 0.54, 0.53, 0.52 in following seven quarters. About 58.5% of the patients were non-adherent and the overall mean first two-year MPR was 0.59.

Conclusion We found that the adherence to AED therapy in pediatric patients significantly decreased with time, and more than half of the patients are non-adherent in the first two year after initiation of AED. Our findings implicate considerably poor AED adherence in pediatric patients with epilepsy and warrant attention and further action of the health care providers.

109

頑固型多發性癲癇治療:海馬迴刺激術

曾偉恩 吳禹利

林口長庚紀念醫院 神經內科

Hippocampal stimulation in treatment of medically refractory, multi-epileptic foci of mesial temporal lobe epilepsy

Wei-En Johnny Tseng, Tony Wu

Department of Neurology, Chang Gung Memorial Hospital, Lin-Kou Medical Center

Objective: Our aim was to evaluate the safety and efficacy of electrical

stimulation of the hippocampus in a medically refractory, mesial temporal lobe epilepsy with multi-epileptic foci patient.

Case report: A 30 year-old male who is a chronic epilepsy patient had generalized tonic clonic seizure at first onset age of 9 year-old. At age of 21, the seizure pattern changed to automotor seizure with impairment of consciousness. He had aura of bitter taste, post-ictal confusion with déjà vu, and frequency of 1-2 attacks per month, despite under valproate 1000mg/day and lamotrigine 300mg/day. On 2012/08/15, he was admitted for long term video EEG monitoring and found phase reversal at F8T2 with synchronized Fp2 > Fp1 sharp wave, sphenoid EEG revealed F8 = T2 = Sp2 but sometimes Fp2 > F8 > T2 > Sp2. In addition, neuroimaging MRI disclosed right hippocampal atrophy and PET showed decreased glucose metabolism at right mesial temporal lobe. He was diagnosed of right mesial temporal lobe epilepsy with bilateral frontal involvement. After fully discussed the pros and cons to the patient and family, bilateral hippocampal depth electrode was implanted on 2012/11/19. Depth electrode recorded three times of recruiting pattern of increasing amplitude and frequency of RT0-3 rhythmic spike-wave complex with phase reversal at RT1, suspect seizure attack without clinically ictal

presentation. Under test stimulation parameters (90usec, 1V, 145 Hz), the amount of inter-ictal epileptiform discharge has reduced > 50% compared to non-stim situation. He was discharged under previous AEDs dosage and OPD follow up for stimulation initiation and seizure frequency monitoring.

Conclusion: Treatment challenge arises in mesial temporal lobe epilepsy with multi-epileptic foci patient. Our case presented a 50% reduction in inter-ictal epileptiform discharge after bil. hippocampal stimulation. Long-term monitor for ictal frequency is warrant for efficacy evaluation.

110

癲癇和威爾森氏症：腦波、神經影像和臨床相關性

黃啟瑞 黃錦章

林口長庚紀念醫院 神經內科

Epilepsy in Wilson's disease: EEG, neuroimages and clinical correlation

Chi-Jui Huang, Chin-Chang Huang

Department of Neurology, Chang Gung Memorial Hospital, Lin-Kou Medical Center

Objective To investigate clinical characteristics of seizures in Wilson's disease (WD) and to correlate with electroencephalography (EEG) changes and *magnetic resonance imaging(MRI)* abnormalities.

Background Seizures may occur in WD, with a prevalence of 4.2%-8.3%, which is uncommon and atypical. However, the mechanisms and

pathogeneses are not fully understood. Here we analyze clinical features and seizure pattern in Wilson's disease and correlated with the brain MRI.

Subjects and Methods We retrospectively reviewed the medical records of all patients from CGMH with the diagnosis of WD from January 2001 to October 2012 and charted the clinical features, EEG findings and MRI findings.

Results Six out of 91 patients (6.6%) with WD have seizures. The types of seizures included generalized tonic-clonic (2 patients), complex partial (1 patient), and partial seizures with secondary generalization (3 patients). One patient had status epilepticus. EEG abnormalities were noted in 5 out of 6 patients consisting of background slowing and epileptiform discharges. Brain MRI revealed varying degrees of atrophy and signal changes involving subcortical white matter of the frontal lobe in the patients with partial seizures with secondary generalization, while mild cortical atrophy in another patient with generalized tonic-clonic seizure. The outcome of seizures was relatively good with seizure free (33.3%), good control (50%), and poor control (16.7%).

Conclusion Seizures are not uncommon in WD. Patients with seizures usually had subcortical white matter changes than those without.

Patients with seizures and white matter changes tended to have partial seizures with secondary generalization and had a good drug response.

111

過氧化體增殖活化受體 (γ) 在癲癇發作與癲癇生成之角色

黃欽威¹ 蔡景仁¹ 黃朝慶²

¹成大醫院神經科

²小兒科

The role of peroxisome proliferator-activated receptors- γ in epileptic seizures and epileptogenesis

Chin-Wei Huang¹, Jing-Jane Tsai¹, Chao-Ching Huang²

¹Department of Neurology;

²Department of Pediatrics, National Cheng Kung University Hospital

Background Peroxisome proliferator-activated receptor (PPAR) is a member of the nuclear hormone receptor superfamily, which plays an important role in adipocyte differentiation, lipid biosynthesis, glucose homeostasis and immunomodulation. Among them, the isoform PPAR γ , in addition to the lipid and glucose modulating effects, have been found to be actively involved in neuroprotection. Thus, we conducted an experimental study to know if the PPAR γ agonist-pioglitazone could ameliorate the seizures and epileptogenesis in an animal model of epilepsy

Materials and methods Adult male B6 mice were divided into two groups: the pioglitazone (PGZ) group and the normal saline (control) group. The PGZ group

was treated with PGZ (i.p. at doses of 10 mg/kg), and the control group was treated normal saline injection (i.p.) one hours before pilocarpine (60 mg/kg, i.p.)-induced seizures and excitotoxicity. Then the PGZ group was fed with PGZ (10 mg/kg) for 28 days. We evaluated the acute seizure susceptibility, severity, and mortality. Both acute neuronal loss and chronic mossy fiber sprouting in the CA3 area were evaluated. Both groups were blood-sampled to monitor the blood glucose level before and 30 minutes after seizure challenge.

Results The blood glucose level before and after pilocarpine-induced seizures was similar in both groups. The PGZ group had longer latency to severe seizures, compared to the control group. The PGZ group showed similar neuronal loss in the hippocampal CA3 area with the control group. In contrast, the PGZ group attenuated chronic mossy fiber sprouting.

Conclusion PPAR γ agonist (pioglitazone) appeared to attenuate pilocarpine acute seizures and excitotoxicity. The similar neuron loss in both the control and the PGZ groups suggested the dissociation between acute seizures and excitotoxic neuronal death. Our studies will provide a potential therapeutic gateway in epileptogenesis and epilepsy prevention.

112

頭孢類抗生素引起之廣泛週期性癲癇樣腦波：苯二氮平是否有所助益？

劉虹余^{1,3} 尤香玉^{2,3}

¹ 佛教慈濟綜合醫院台北分院神經科

² 台北榮民總醫院神經醫學中心神經內科

³ 陽明大學醫學院

Cephalosporin related generalized periodic epileptiform discharges on EEG: should benzodiazepines be given?

Hung-Yu Liu^{1,3}, Hsiang-Yu Yu^{2,3}

¹ Department of Neurology, Buddhist Tzu Chi General Hospital, Taipei, Taiwan

² Department of Neurology, Neurological Institute, Taipei Veterans General Hospital, Taipei, Taiwan

³ School of Medicine, National Yang-Ming University, Taipei, Taiwan

Objectives To investigate the response to benzodiazepines (BZDs) of patients with cephalosporin related generalized periodic epileptiform discharges (GPEDs) on electroencephalography (EEG).

Methods We collected the cases with GPEDs on EEG, and selected those whose GPEDs were temporally related to cephalosporin use. The medical records of the patients were reviewed for the clinical presentations, treatments and outcomes.

Results Nine patients with cephalosporin related GPEDs on EEG with certain degree of consciousness disturbances were included. Eight patients were treated as nonconvulsive status epilepticus (NCSE) and received BZDs. Only one patient improved immediately after BZD administration while the other 7 patients recovered their

consciousness gradually after withdrawal of cephalosporin. The rest of one patient who did not receive BZDs or any AEDs recovered his consciousness gradually in 1 day after cephalosporin was stopped.

Conclusions BZDs did not ameliorate the clinical manifestations in most of the patients with cephalosporin related GPEDs.

113

臉臂肌失張性癲癇發作的腦波表現：橋本氏腦病變

蔡孟翰 莊曜聰

高雄長庚醫院神經內科系 腦功能暨癲癇科

Electroencephalography of faciobrachial dystonic seizures in a patient with Hashimoto encephalopathy.

Meng-Han Tsai, Yao-Chung Chuang

Division of Epilepsy, Department of Neurology, Kaohsiung Chung Gung Memorial Hospital, Taiwan

Background Faciobrachial dystonic seizures (FBDS) have recently been described as a special seizure type of limbic encephalitis associated with leucine-rich glioma inactivated-1 (LGI1) antibodies. Nonetheless, its EEG correlates have not been clearly characterized.

Case report Here we report this distinctive seizure semiology in association with clinical diagnosis of Hashimoto encephalopathy. A 58 year-old man presented with cognitive decline and personality change,

followed by frequent episodes of unilateral facial grimacing and upper limb dystonic posturing. Ictal electroencephalography showed that FBDS were preceded by a contralateral high amplitude direct current (DC) shift associated with background rhythm attenuation. Brain magnetic resonance imaging (MRI) revealed increased T2 signal in both temporal lobes. Conventional anti-epileptic drug treatment was ineffective but steroid therapy resulted in significant improvement.

Conclusion We described a unique EEG pattern in associated with FBDS. We emphasized the importance of recognition of FBDS because of the implication of earlier diagnosis of autoimmune encephalopathies. Prompt treatment of steroid may prevent long-term cognitive sequelae and fatal outcome. Screening of anti-thyroid antibodies in addition to anti-LGI1 antibodies in epilepsy patients presented with FBDS may be a useful alternative and worth further studies.

頭痛及疼痛

114

以大腦假性腫瘤為首要表現的轉移性肺腺癌

王建瑋 蔡銘駿

中國醫藥大學附設醫院 神經部

Pseudotumor cerebri as a first manifestation of metastatic adenocarcinoma of the lung

*Chein-Wei Wang, Ming-Jun Tsai
Department of Neurology, China Medical University Hospital, Taichung, Taiwan*

Introduction Pseudotumor cerebri (PTC) is a syndrome characterized by elevated intracranial pressure of unknown cause. The syndrome classically manifests with headaches, transient visual obscurations, and pulsatile tinnitus in the overweight women. There is normal cerebrospinal fluid (CSF) composition, and no hydrocephalus or other cause of intracranial hypertension evident on neuroimage. We report a case of newly diagnosed adenocarcinoma of the lung metastatic to meninges presenting symptoms and signs consistent with pseudotumor cerebri.

Case presentation A previously healthy 47-year-old woman came to our emergent department for deteriorated headache since 1 month ago. About one month ago, gradual onset of neck tightness, occipital and bi-temporal headache developed. The pain was improved slightly with acetaminophen at the beginning. Two weeks ago, the frequency and the severity of headache increased, and episodes of nausea/vomiting, transient visual change and left tinnitus were associated. Headache aggravated at midnight and sometimes awakened her from sleep, and it was also enhanced by Valsalva maneuver. One week ago, double vision occurred. On

examination, the patient was afebrile without meningismus at admission. Extraocular movement revealed bilateral abducens palsy. A fundoscopic examination demonstrated mild bilateral papilledema. On pure tone audiometry, left-sided buzzing tinnitus with mild sensorineural hearing loss was detected. The CSF profiles demonstrated an opening pressure of 36 cm H₂O, white blood cells 4/ μ l, red blood cells 2/ μ l, micro protein 21 mg/dl and glucose 41 mg/dL. CSF cytology revealed no malignant cell. Initial brain CT showed unremarkable findings (fig 1). The symptoms were temporarily subsided after the lumbar puncture, so pseudotumor cerebri was impressed. Whereas, headache got worse, and complicated with generalized seizure in the following days. She was treated with ventriculoperitoneal shunt. Brain DWI and T2 flair MRI(fig 2) showed increased intensity in anterior cisterna around pons and one small enhanced nodule (about 8mm in diameter) in the left parietal lobe. CEA was elevated (491ng/mL). Stereotactic biopsy demonstrated as metastatic adenocarcinoma. Malignancy survey revealed pathology-proved adenocarcinoma of the left lung(fig 3). Oral gefitinib (IRESSA) was used in combination with whole-brain radiotherapy (WBRT). Her headaches resolved much and no abducens palsy was noted at follow up.

Discussion PTC is a diagnosis of exclusion. The modified Dandy criteria proposed for diagnosis are (1) Symptoms and signs of increased intracranial pressure (2) No other neurologic abnormalities or impaired level of consciousness (3) CSF pressure greater than 200 mmH₂O with normal composition (4) Normal brain CT scan. The clinical manifestation and examination of our case correspond with the modified Dandy criteria. Whereas, PTC has been reported with other potential secondary causes, such as vitamin A excessive intake, steroid withdrawal, oral contraceptives, hypoparathyroidism, obstructive sleep apnea, obstruction of cerebral venous drainage, infection, carcinomatous or lymphomatous meningitis. In our case, brain MRI (DWI and flair T2) showed significant abnormal findings compatible with carcinomatous meningitis and further examination proved the origin as adenocarcinoma in the lung. Friedman and Jacobson updated the criteria and emphasized the importance of MRI and MR venography. In summary, our findings emphasized the significance of MRI (especially DWI and flair T2) in a case of pseudotumor cerebri, even normal CSF profile with negative finding of malignant cells.

115

內皮前驅細胞於可逆性腦血管收縮
症候群

王署君^{1,2} 傅中玲^{1,2} 陳世彬^{1,2}

¹ 台北榮民總醫院神經醫學中心神經內科

² 國立陽明大學醫學系

Circulating endothelial progenitor cells in reversible cerebral vasoconstriction syndromes

Shuu-Jiun Wang,^{1,2} Jong-Ling Fuh,^{1,2} Shih-Pin Chen,^{1,2}

¹ Department of Neurology, Neurological Institute, Taipei Veterans General Hospital, Taipei, Taiwan.

² Faculty of Medicine, National Yang-Ming University School of Medicine

Background The pathophysiology of reversible cerebral vasoconstriction syndromes (RCVS) remains unknown. We hypothesized that patients with RCVS might have reduced capacity of circulating endothelial progenitor cells (EPCs) to repair the dysfunctional endothelial vasomotor control.

Methods We prospectively recruited RCVS patients (within 2 weeks of disease onset) and healthy controls. Flow cytometry was used to quantify the numbers of circulating EPCs defined as KDR⁺CD133⁺, CD34⁺CD133⁺, CD34⁺KDR⁺ double-positive mononuclear cells. The mean flow velocities of middle cerebral arteries (V_{MCA}) and Lindegaard index (LI) in patients with RCVS were recorded via transcranial color-coded sonography.

Results This study recruited 18 patients with RCVS and 17 age-and-sex matched controls. Patients with RCVS had reduced numbers of CD34⁺KDR⁺ (0.010±0.006% vs. 0.017±0.011%, p=0.031) and KDR⁺CD133⁺ cells (0.030±0.012% vs. 0.043±0.022%,

p=0.032), but not CD34⁺CD133⁺ EPCs (0.039±0.019% vs. 0.054±0.034%, p=0.126), in comparison with controls. The numbers of CD34⁺KDR⁺ (r=-0.64, p=0.018) and CD34⁺CD133⁺ (r=-0.56, p=0.049) cells were negatively correlated with the LI of the right MCA.

Conclusions Patients with RCVS had reduced circulating EPCs, which was correlated with the severity of vasoconstrictions. Endothelial dysfunction might be important in the pathogenesis of RCVS.

116

慢性偏頭痛患者氣味恐懼的腦部構造改變：前驅研究

王嚴鋒^{1,3} 傅中玲^{1,3} 凌憬峰^{2,3} 王署君^{1,3}

¹ 台北榮民總醫院神經內科, ² 台北榮總放射線部, ³ 國立陽明大學醫學院

Brain structural changes in chronic migraine patients with osmophobia: A pilot study

Yen-Feng Wang^{1,3}, Jong-Ling Fuh^{1,3}, Jiing-Feng Lirng^{2,3}, Shuu-Jiun Wang^{1,3}

¹Department of Neurology, and ²Department of Radiology, Taipei Veterans General Hospital, ³National Yang-Ming University School of Medicine

Objective To investigate the brain structural changes in chronic migraine (CM) patients with osmophobia with voxel-based morphometry (VBM).

Background Osmophobia during migraine attacks is reported by as many as 62.2% of migraineurs. The presence of osmophobia was

associated with higher Hospital Anxiety and Depression Scale scores. There are significant overlaps in brain structures processing olfaction and emotion.

Whether there is structural alteration in these brain areas remains to be determined.

Methods We prospectively enrolled CM patients. Brain magnetic resonance imagings were obtained using a 3T MR system (Trio, SIEMENS Medical Solutions, Erlangen, Germany). Structural alterations were assessed by voxel-based morphometry (VBM) using Diffeomorphic Anatomical Registration Through Exponentiated Lie Algebra (DARTEL) method, and comparisons between patients with and without osmophobia were made.

Results In total, 18 patients (5M/13F, age 35.1 ± 11.4 years) fulfilling ICHD-2 criteria were enrolled. Of them, 12 patients (66.7%) had osmophobia. As compared to those without, patients with osmophobia appeared to have increased volumes in right insula and bilateral temporal areas on VBM analyses.

Conclusion The presence of osmophobia in CM patients seemed to be associated with volume increases in right insula and bilateral temporal areas.

117

由 Bortezomib 誘發之可逆性後腦病變
症候群：個案分析與文獻討論

何建輝¹ 羅中平^{2,3} 涂敏謙¹

佛教慈濟綜合醫院臺中分院¹ 神經內科² 放射診斷科³ 慈濟大學醫學院

Bortezomib-induced posterior reversible encephalopathy syndrome- A case report and review of literature.

Chien-Hui Ho¹, Chung-Ping Lo^{2,3}, Min-Chien Tu¹

¹Department of Neurology, ²Department of Radiology, Buddhist Tzu Chi General Hospital Taichung Branch, Taichung, Taiwan, ³School of Medicine, Tzu Chi University, Hualien, Taiwan

Background Posterior reversible encephalopathy syndrome (PRES) is a rare and unappreciable complication among patients receiving targeted chemotherapy. Herein we presented a case of PRES after bortezomib treatment and proposed possible underlying mechanism on the basis of image findings.

Case presentation A 51-year-old woman who received three cycles of bortezomib (2.5 mg/each) within one month as multiple myeloma treatment developed generalized tonic clonic seizure with post-ictal confusion after two hours of blurred vision and headache. Initial brain magnetic resonance images (MRI) showed cortical-subcortical gyriform enhancement, sulci effacement, and vasogenic edema with diffusion hyperintense periphery at posterior poles, which were dramatically reversed to faint subcortical hyperintensities 2 weeks later.

Conclusion With increasing

application of targeted chemotherapy, prompt recognition of PRES turned to be a clinical issue. The vasogenic edema with preferential white matter involvement was attributed to overwhelmed cerebral autoregulation, whilst cortical-subcortical gyriiform enhancement was inferred as the toxin-mediated blood-brain barrier damages. Our report may raise the alertness of clinician on this rare syndrome and prudent use of targeted chemotherapy.

118

可逆性腦血管收縮症候群之視網膜血管研究

杜怡萱 傅中玲 王署君 陳世彬
台北榮民總醫院神經內科 國立陽明大學醫學院

Retinal Microvascular Involvement in Reversible Cerebral Vasoconstriction Syndrome

Yi-Hsuang Dou, Jong-Ling Fuh, Shuu-Jiun Wang, Shih-Pin Chen
Department of Neurology, Neurological Institute, Taipei Veterans General Hospital, National Yang-Ming University School of Medicine

Introduction Reversible cerebral vasoconstriction syndrome (RCVS) is characterized by recurrent thunderclap headache and reversible vasoconstrictions involving medium to large intracranial arteries. Whether there is microvascular involvement in RCVS is still unknown. The cerebral and retinal microvasculature shared important anatomic, physiologic, and embryologic features, which means change in the retinal microvasculature may mirror changes in the cerebral microvasculature.

Method We investigated the retinography in patients with RCVS and

age-and-sex matched controls from 2010 to 2012 at Taipei Veterans General Hospital. The demographics and vascular risk factors of participants were collected. We measured the caliber width of retinal arterioles and venules coursing through a zone between 0.5 and 1 disc diameter from the optic disc margin. The diameters of retinal arterioles and venules were corrected with Parr and Hubbard formula. The retinal arteriole to venule ratio (AVR) was derived by dividing the mean arteriolar caliber with the mean venular caliber.

Result Patients with RCVS (n=27) had larger retinal arteriolar and venular calibers in the right eye in comparison with the control group (n=31) (retinal arterioles: 118.9 ± 12.3 vs. 109.2 ± 13.1 μm , $p=0.008$; retinal venules: 139.3 ± 17.9 vs. 127.9 ± 13.9 μm , $p=0.012$). The AVR in patients with RCVS was significantly smaller on the left eye (0.83 ± 0.06 vs. 0.88 ± 0.10 , $p=0.035$) and nominally smaller on the right eye (0.70 ± 0.06 vs. 0.74 ± 0.08 , $p=0.115$) in comparison with controls.

Conclusion Patients with RCVS had low AVR attributed to disproportionately dilatation of retinal arterioles and venules. Longitudinal study is required to elucidate whether the retinal microvascular abnormalities are inherited traits or could evolve with disease status.

119

錢幣性頭痛合併高頻率之自體免疫障礙

李姿慧¹ 李連輝¹ 邱文燦² 陳忠仁² 陳偉熹¹
高雄長庚紀念醫院 神經內科¹ 風濕免疫科²

A High Frequency of Autoimmune Disorders in Nummular Headache

Tzu-Hui Li¹, Lian-Hui Lee¹, Wen-Chang Chui², Chun-Jen Chen², Wei-Hsi Chen¹
Departments of Neurology¹ and Rheumatology², Kaohsiung Chang Gung Memorial Hospital, and College of Medicine, Chang Gung University, Kaohsiung, Taiwan

Objective The nummular headache (NH) is currently considered a form of peripheral neuralgia originating from the terminal branch in epicranial tissue but its etiopathogenesis is still unknown. Since autoimmune disorders often involve the trigeminal sensory nerve to provoke craniofacial pain, we hypothesize that autoimmunity aberration may play a role with regards to NH.

Methods The antibodies to antinuclear factor, ds-DNA, extracted nuclear antigens, rheumatoid factor, as well as antiphospholipid antibodies, were examined in 23 primary NH patients. The diagnostic criteria proposed by the 2nd edition of International Classification of Headache Disorders were adopted.

Results Among them were 16 patients (69.6%) found as having at least one abnormal autoimmune indices, namely, antibodies to antinuclear factor in 8 patients, SSA/La in 6 patients, rheumatoid factor in 4 patients, SSB/Ro in 2 patients, and ds-DNA in 1 patient, respectively. An abnormal increase of blood anti-beta2-glycoprotein I antibody was noted in 4 patients and lupus

anticoagulant in 1 patient, whereas HLA-B27 seropositivity was detected in 1 patient. A total of 15 patients (65%) were finally diagnosed as having Sjogren/sicca syndrome, rheumatoid arthritis or antiphospholipid antibody syndrome afterwards.

Conclusion A high prevalence of abnormal autoimmune indices and disorders is present in primary NH patients, suggesting a probable relationship between autoimmunity aberration and epicranial neuralgia in NH.

120

雙局部錢幣性頭痛：臨床分析和世界文獻報告

林宏昇 陳昶宏 傅睦惠 李姿慧 李連輝
陳偉熹
高雄長庚紀念醫院 神經內科

Bifocal Nummular Headache: A Clinical Analysis and Review of Literature

Hung-Sheng Lin, Chang-Hung Chen, Mu-Hui Fu, Tzu-Hui Li, Lian-Hui Lee, Wei-Hsi Chen
Department of Neurology, Kaohsiung Chang Gung Memorial Hospital, and College of Medicine, Chang Gung University, Kaohsiung, Taiwan

Objective Nummular headache (NH) is a new category of primary headache disorder characterized by consistent location, size, and shape of painful areas. The pathogenesis is uncertain. Bifocal painful areas are rare manifestations but may expand the clinical diversity of NH.

Methods The clinical characteristics

of five bifocal NH patients were reported and those of 11 patients in previous studies were reviewed. The diagnostic criteria proposed by the 2nd edition of International Classification of Headache Disorders were adopted. We classified the bifocal NH into two types. Type I was defined as a simultaneous activation of two painful areas while type II was defined as two painful areas occurring in different times.

Results All 16 patients were female, with mean age of onset and initial presentation of 54.7 years and 58.2 years, respectively. There were seven type I and nine type II patients. The parietal area, especially the tuber parietale, was the leading site of involvement in both types of patients. The shape and size of painful areas were also similar between these two groups. There was an equal frequency of ipsilateral and contralateral painful areas. The pain intensity was similar in both types of patients but was milder in new painful areas than in previous painful areas in type II patients.

Conclusion Bifocal NH suggests a central role of NH but does not debunk the peripheral theory of NH. The accumulated findings in bifocal NH patients do not support a generalization of pain occurrence or a reproduction of local process of epicranial neuralgia at multiple sites in NH.

121

穿蝶竇手術後引起之錢幣性頭痛

崔智¹ 陳偉熹²

屏東寶建醫院 神經外科¹

高雄長庚紀念醫院 神經內科²

Nummular Headache Shortly After Trans-sphenoidal Surgery

Chi Chui¹, Wei-Hsi Chen²

Department of Neurosurgery¹, Paochien Hospital, Pingtung, Taiwan

Department of Neurology², Kaohsiung Chang Gung Memorial Hospital, and College of Medicine, Chang Gung University, Kaohsiung, Taiwan

Background Nummular headache (NH) is a newly-categorized primary headache characterized by a consistent location, shape and size of painful area in each attack. The etiopathogenesis is entirely unknown. Currently, the peripheral theory of epicranial neuralgia is widely accepted than the central theory but it cannot fully explain the clinical picture.

Case Report A patient who suffered a relapsing and remitting course of NH at the high parietal area and vertex shortly after trans-sphenoidal surgical resection for pituitary prolactinoma was reported. There was no focal trophic change or paresthesia but a mild allodynia in the painful area. Patient did not exhibit trigeminosensory feature or cranial trauma entirely. The pain favorably responded to gabapentin.

Conclusion The patient herein was the second one formally reported in

literature. Physicians should be alerted for postoperative NH which is amenable to treatment. The findings in our patient support a dual mechanism of NH and central NH a form of referred pain.

122

**質子幫浦抑制劑增加頭痛的風險：
一全國性病例交叉研究**

梁仁峰^{1,3} 陳永泰² 傅中玲^{1,3} 王署君^{1,3}
台北榮民總醫院¹神經醫學中心神經內科
²內科部腎臟科
³國立陽明大學醫學系

**Association of Headache Events with
Proton Pump Inhibitors Use: A
Nationwide Case-Crossover Study**

Jen-feng Liang^{1,3}, Yung-Tai Chen², Jong-Ling
Fuh^{1,3}, Shuu-Jiun Wang^{1,3}
¹Department of Neurology, Neurological Institute,
and ²Division of Nephrology, Department of
Medicine, Taipei Veterans General Hospital,
³Faculty of Medicine, National Yang-Ming
University

Objective The study sought to assess the risk of headache events associated with use of proton pump inhibitors (PPIs).

Method We conducted a case-crossover study of 320,963 new-onset headache patients (ICD-9-CM codes: 784.0, 346.x, 307.81) enrolled in the National Health Insurance Research Database in Taiwan from 1998 to 2010. The authors compared the rates of PPIs use during case and control time windows of 7, 14, 28 and 56 days. Stratified analyses were performed for valuing the interaction between the headache risk of PPIs use and PPI type, age and sex. The analyses of association between different

headache types and PPI use were also performed. The conditional logistic regression model was used to estimate the odds ratios (OR) and their 95% confidence intervals. The adjusted OR (aOR) was estimated after controlling for confounding medication exposures.

Results The aOR of all types of headache risk with PPI exposure was 1.52 (95% confidence interval=1.24–1.85) using 7-day time windows, and the ORs were 1.48, 1.37 and 1.22 separately using 14, 28 and 56-day time windows. The risks of tension-type headache or other non-specific headaches were elevated in 7 or 14- day time windows, but risk of migraine only increased in 28 or 56-day time windows. Compared with other PPIs, rabeprazole were not associated with developing headache across all time windows. Younger patients who took PPIs had a greater risk to develop tension-type headache and other non-specific headaches. The sex and age of PPIs users were not associated with an increased risk of migraine.

Conclusions PPIs usage, except rabeprazole, was associated with an increased risk of headache. The risk was decreased over time after PPIs exposure. Most headaches tended to occur within 2 weeks of PPI exposure, whereas migraine tended to develop after 2 weeks.

123

偏頭痛患者的失眠情形

陳怡如¹ 王博仁²

¹活水神經內科診所 ²新樓醫院神經內科

Insomnia in migraineurs

Yi-Ju Chen¹, Po-Jen Wang²

¹Living Water Neurological Clinic;

²Department of neurology, Sin Lau Christian Hospital

Purpose Sleep disturbance is frequently found in migraineurs. Poor sleep quality often triggers a migraine attack; on the other hand, headache would interfere the sleep. After long term insomnia, the migraineurs would get more attacks and the quality of life becomes worse. The aim of this study is to evaluate whether there is a higher incidence rate of insomnia in more severe migraineurs.

Materials and methods This is a cross-sectional research design. Totally 107 patients with diagnosis of migraine and probable migraine were recruited from living water clinics from March, 2012 to June 2012. We used insomnia severity index (ISI) as a tool to evaluate the severity of insomnia. According to the definition, the insomnia severity index ≥ 15 indicated clinical insomnia. At the same time, estimated insomnia days in recent one month were recorded. The migraineurs were divided into chronic daily headache (CDH) group and non-CDH group.

Result Finally 103 migraineurs' data were analyzed; 4 were excluded due to

missing data. In this study the mean age was 41.85 and standard deviation (SD) was 17.05. The mean insomnia severity index was 9.68 with standard deviation 6.67. There were 15 CDH patients and 88 non-CDH patients. Twenty five patients had insomnia problem (insomnia severity index ≥ 15); 7 patients belonged to the CDH group, 18 to non-CDH. In other words, in our study 46.67% CDH patients suffered from insomnia and 20.45% non-CDH patients complained about insomnia. However, 10 CDH patients (66.67%) reported that they had insomnia more than 15 days in one month, and 37(42%) reported in the non-CDH patients.

Conclusions The results showed a higher rate of insomnia in CDH patients. However, overestimated insomnia was also noted in these patients. Nevertheless, insomnia was also not infrequent in non-CDH patients. We need to pay more attention to sleep problem in migraineurs.

124

椎體骨泥整形術後引起顱內低壓性頭痛之案例報告

陳彥文 陳蔚邦 張振聲 許世斌 郭弘昌

義大醫療財團法人義大醫院神經內科 義守大學

Intracranial Hypotension as a Rare Complication Post Vertebroplasty: A Case Report

Yen-Wen Chen, Wei-Pang Chen, Chen-Sheng

Chang, Shih-Pin Hsu, Hung-Chang Kuo

Department of Neurology, E-DA Hospital /

I-Shou University, Kaohsiung, Taiwan

Background The vertebral compression fracture was one of the frequent complications of osteoporosis. The percutaneous vertebroplasty (PVP), a minimally invasive therapeutic procedure, has been applied in treatment of osteoporotic vertebral compression fractures with generally considered low risk of complication.

Case report A 51-year-old healthy woman without any history of neurologic or orthopedic illness suffered from severe low back pain since about ten days ago. Her pain radiated to bilateral subcostal areas and was aggravated by body bending forwardly. The orthopedic survey included T-L spine X ray and MRI revealed T12 compression fracture. Bone densitometry (BMD) examination proved osteopenia. Those symptoms were not relieved under conservative treatment or medication only. PVP was performed and the whole operation course was smooth without obvious intra-operative complication. However, symptoms of intracranial hypotension including acute onset of severe orthostatic headache, head fullness sensation, nausea, and vomiting were noted just a few hours after PVP. The followed spinal MRI revealed fluid accumulation at posterior epidural space of T11-12-L1 and cerebrospinal fluid (CSF) leakage was impressed. After adequate hydration and complete bed-rest for five days, her symptoms got successful improving.

Conclusion Our report highlights the possibility and importance of intracranial hypotension related to CSF leakage after procedure of PVP. It reminded the clinicians watching for any possibility of occurrence of such complication during or after procedure of PVP and there was no definite benefit than other conservative treatment.

125

可逆性腦血管收縮症候群之高解析度 3T 血管壁磁振造影研究

傅中玲^{1,2} 王署君^{1,2} 陳世彬^{1,2}

¹台北榮民總醫院神經醫學中心神經內科

²國立陽明大學醫學系

Intracranial arterial wall imaging using high-resolution 3-tesla MRI in reversible cerebral vasoconstriction syndromes

Jong-Ling Fuh,^{1,2} Shuu-Jiun Wang,^{1,2} Shih-Pin Chen^{1,2}

¹Department of Neurology, Neurological Institute, Taipei Veterans General Hospital, Taipei, Taiwan.

²Faculty of Medicine, National Yang-Ming University, Taipei, Taiwan

Background Limited histopathological studies suggested that there was no vascular wall inflammation in reversible cerebral vasoconstriction syndromes (RCVS); however, the procedure was invasive and there could be sampling biases. We investigated the vascular wall pathology in RCVS using a non-invasive high-resolution magnetic resonance arterial wall imaging.

Methods We prospectively recruited patients with RCVS from the headache clinic of Taipei Veterans General Hospital from 2010 to 2012. Age-and-sex matched migraine patients were recruited for comparison. All participants received vascular wall imaging using contrasted T1 fluid-attenuated inversion recovery (T1-FLAIR) with a 3-tesla magnetic resonance machine. The vascular wall involvement was rated as marked, mild (patchy) and no vascular wall enhancement. Some patients with vascular wall enhancement received follow-up images to evaluate whether the enhancement was reversible.

Results Fifty-four patients with RCVS and 20 patients with migraine were recruited during the study period. After excluding patients with poor imaging quality, 46 RCVS and 16 migraine patients were eligible for final analysis. In patients with RCVS, 6 (13%) had marked, 17 (37%) has mild, and 23 (50%) had no vascular wall enhancement; while only 2 (13%) of the migraine patients had mild vascular wall enhancement and none had marked vascular wall enhancement ($p=0.031$). The arterial wall enhancement was not associated with any vascular risk factors, severity of vasoconstriction or triggering factors. Three patients with marked vascular wall enhancement received follow-up; one had complete resolution of enhancement, one improved to only patchy involvement and one remained the same.

Conclusions Half of the RCVS patients could have a vascular wall pathology using a high-resolution arterial wall imaging, but the etiology could be heterogeneous. Reversibility of vascular wall enhancement in selected cases suggested that a certain degree of vascular wall inflammation should still be considered.

126

臺灣陣發性與慢性偏頭痛患者失能情況、生活品質、及醫療資源利用之比較分析

彭冠博，王博仁，傅中玲，王署君
台北榮民總醫院；活水神經內科診所

Comparisons of disability, quality of life, and resource use between chronic and episodic migraineurs: A clinic-based study in Taiwan

Kuan-Po Peng, Po-Jen Wang, Jong-Ling Fuh, Shuu-Jiun Wang
Taipei Veterans General Hospital; Living Water Neurological Clinic

Background Chronic migraine (CM) was associated with a higher disease burden than episodic migraine (EM) in a recent international web-based survey. However, Asians with CM were underrepresented in this study.

Objectives We investigated if CM and EM differed in headache-related disability, health-related quality of life (HRQoL) and health care resource utilization in Taiwan.

Methods: This study enrolled patients with EM and CM from two headache clinics in Taiwan, the Taipei Veterans General Hospital and Living Water

Neurological Clinic. Migraine diagnosis was made by physicians based on the International Classification of headache disorders, 2nd edition (ICHD-2) and CM diagnosis based on the Silberstein-Lipton criteria. All participants completed a questionnaire including sociodemographics, Migraine Disability Assessment (MIDAS), EuroQol five-dimensions (EQ-5D), Migraine-Specific Quality of Life v2.1 (MSQ), Patient Health Questionnaire-4 (PHQ-4), productivity and health care resource utilization.

Results A total of 331 patients completed the study, including 164 (49.5%) EM patients and 167 (50.5%) CM patients. CM patients, compared to EM patients, reported a higher MIDAS score, lower generic (EQ-5D visual analogue scale score and EQ-5D index score) and migraine-specific (all three domains of MSQ) HRQoL, higher levels of anxiety and depression (PHQ-4 ≥ 6), and greater health care resource utilization and productivity loss. Positive correlations were found between these instruments and levels of anxiety and depression.

Conclusion Compared to EM, CM was significantly associated with higher disability, lower HRQoL, and greater health care resource utilization and productivity loss.

127

顳動脈炎頭痛之病例報告及文獻回顧

黃子洲 蘇慧真 柯登耀 王博仁
活水神經內科診所

Headache Attributed to Temporal Arteritis – a case report and literatures review

Tzu-Chou Huang, Hui-Chen Su, Teng-Yao Ke, Po-Jen Wang
Living Water Neurological Clinic

Background Headache attributed to temporal arteritis (TA) is a secondary headache caused by granulomatous inflammation of temporal artery. It affects individuals over 50 years of age and is quite rare in Taiwan. We report a patient who had pathology-proved TA and discuss about the cases which had been reported in Taiwan.

Case report A 73-year-old woman has past history of coronary artery disease. She complained of bilateral temporal headache 2 weeks prior to the visit. It was relatively acute onset with throbbing character and was moderate in severity. The pain persisted all the day and would extend to frontal and occipital areas sometimes. No nausea or tearing was combined. She also complained blurred vision and bilateral jaws soreness especially when chewing. Physical examination showed nothing special except for visible, engorged tender vessels over bilateral temporal areas. Lab result revealed elevated ESR level. We soon prescribed prednisolone and did temporal artery biopsy (TAB). The pathology showed

positive for temporal arteritis. We then kept on prednisolone treatment. This patient got obviously improved after treatment.

Discussion TA is rare in eastern countries. Although pathological proof is important, it is not essential for the diagnosis. According to the criteria of American Academy of Rheumatology, new headache, onset age more than 50, physical finding on the affected temporal artery and elevated ESR are sufficient to make diagnosis. International Classification of Headache Disorders–II criteria require new headache, tender scalp vessel and elevated ESR (or CRP) or positive TAB, plus an effectiveness of steroid treatment. Headache is the most frequent symptom, but the other systemic or specific symptoms should also be noted. These include fever, malaise, jaw claudication, polymyalgia rheumatica and, most notable, visual complaints. Temporal artery is not the only artery which would be affected. Clinicians should pay attention to other arteries such as coronary artery when treating these patients. There are 8 TA patients being reported in literatures in Taiwan. Five of them are male. Their age ranged from 68 to 93. Six of them are pathology-proved. All of them had elevated ESR, 7 had engorged or tender temporal artery, 4 had jaw claudication, 3 had diplopia, and 3 had systemic complaint such as malaise or body weight loss. Four of them had

complication of blindness, one had tongue necrosis and one had basilar-vertebral artery involvement and eventually expired. Severe outcome is not uncommon in Taiwan.

128

鼻腔內麻醉時的雷擊性頭痛

黃敬棠 陳盈助

佛教慈濟綜合醫院台中分院神經科

Thunderclap Headache During Intranasal Anesthesia

Ching-Tang Huang, Ying-Chu Chen
Neurological Institute, Buddhist Tzu Chi
General Hospital Taichung Branch

Background Thunderclap headache refers to an abrupt and very severe headache reaching peak intensity within 1 minute. In addition to aneurysmal subarachnoid hemorrhage, there are many secondary causes which need thorough investigations. We present a case of recurrent thunderclap headache with onset during intranasal anesthesia.

Case Report A 39-year-old female without systemic disease or recent trauma history presented to our emergency room complaining of sudden onset bilateral occipital thunderclap headache during intranasal anesthesia with lidocaine-epinephrine soaked cottage, and two recurrences in the following 5 days: one attack provoked by defecation and another spontaneous attack during sleep. Initial brain CT was normal. However, minimal cortical subarachnoid

hemorrhage at bilateral occipital lobe was found in brain MRI (T2-FLAIR). Further cerebral angiography study disclosed multifocal vasospasm involving the bilateral anterior and middle cerebral arteries. This patient was given oral nimodipine, and got satisfied outcome. The clinical presentation and imaging findings are consistent with reversible cerebral vasoconstriction syndrome (RCVS).

Conclusion RCVS can be primary or secondary. Vasoactive substances are important secondary factors, such as intranasal administration of lidocaine-bosmin in our case. Clinicians should be aware of this neurological emergency in order to provide early diagnosis and treatment.

129

叢集性頭痛患者在額部痛覺調控網絡中灰質體積之改變

楊富吉^{1,2}, 周坤賢³, 傅中玲⁴, 凌憬峰⁵, 林永煒^{1,4}, 林慶波^{3,6*}, 王署君^{1,4*}

¹ 國立陽明大學腦科學研究所 ² 三軍總醫院神經內科 ³ 國立陽明大學神經科學研究所 ⁴ 台北榮民總醫院神經內科 ⁵ 台北榮民總醫院放射科 ⁶ 國立陽明大學生物醫學影像暨放射科學系

Altered Gray Matter Volume in the Frontal Pain Modulation Network in Patients with Cluster Headache

Fu-Chi Yang^{1,2}, Kun-Hsien Chou³, Jong-Ling Fuh⁴, Jiing-Feng Lin⁵, Yung-Yang Lin^{1,4}, Ching-Po Lin^{3,6*}, Shuu-Jiun Wang^{1,4*}

¹ Institute of Brain Science, National Yang-Ming University,

² Departments of Neurology, Tri-Service General Hospital, National Defense Medical Center,

³ Institute of Neuroscience, National Yang-Ming University,

⁴ Department of Neurology, National Yang-Ming University,

⁵ Department of Radiology, National Yang-Ming University,

⁶ Department of Biomedical Imaging and Radiological Sciences, National Yang-Ming University

Objective Previous functional imaging studies in episodic cluster headache (CH) patients revealed altered brain metabolism concentrated on the central descending pain control system. However, it remains unclear whether changes in brain metabolism during the “in bout” period are due to structural changes and whether these structural changes vary between the “in bout” and “out of bout” periods.

Methods To quantify brain structural changes in CH patients, the regional gray matter volume (GMV) was compared among 49 episodic CH patients during the “in bout” period and 49 age- and sex-matched controls using voxel based morphometry approach (VBM). Twelve patients were rescanned during the “out of bout” period to evaluate the changes, if any, between these two periods.

Results Compared with healthy controls, CH patients showed significant “in bout” GMV reductions in the bilateral middle frontal, left superior and medial frontal gyri. Compared to “out of bout” scans, the “in bout” scans revealed significant GMV increases in the left anterior cingulate, insula, and fusiform gyrus. Additionally, compared to healthy

controls, the “out of bout” scans revealed a trend of GMV reduction in the left middle frontal gyrus. No area of GMV increase was found in patients during the “in bout” or “out of bout” periods.

Conclusion These affected regions primarily belong to frontal pain modulation areas. Therefore, these GMV changes may reflect insufficient pain-modulating capacity in the frontal areas of CH patients and may be important to the pathophysiology of CH.

130

可逆性後腦病變症候群併腦血管收縮症候群-個案報告

蔡志宏 黃文柱

國立成功大學醫學院附設醫院神經部

Posterior reversible encephalopathy syndrome associated with reversible cerebral vasoconstriction syndrome- Case report

Chih-Hung Tsai, Wen-Juh Hwang

Department of Neurology, National Cheng Kung University Hospital

Background Posterior reversible encephalopathy syndrome (PRES) is a clinico-radiological diagnosis and the patient typically presents with headache, visual disturbance, elevated blood pressure, confusion, or seizures. Reversible cerebral vasoconstriction syndrome (RCVS) usually presents as a thunderclap headache in middle-aged women. We presented 2 cases who suffered from both PRES and RCVS at the same time.

Case Report The first case is a 47-year-old woman who suffered from intermittent severe throbbing headache at posterior neck to vertex, associated with visual disturbance, nausea, and vomiting for about one week. Physical and neurologic examination showed elevated blood pressure (168/113 mmHg), poor attention, and visual field defect. Diffusion-weighted brain MRI revealed bilateral parieto-occipital high signal intensity and MR angiography showed multifocal stenosis at bilateral MCAs. She was treated with nimodipine and aspirin, with gradual improvement. The second case is a 33-year-old pregnant woman (GA 32+1wks) who suffered from headache at posterior neck, elevated blood pressure (191/118 mmHg), and HELLP syndrome (hemolysis, elevated liver enzymes, and low platelet count). She developed two episodes of generalized convulsions, with postictal right hemiparesis. Brain CT showed hypodense lesions at bilateral frontoparietal lobes and left occipital lobe. Brain MRI FLAIR **sequence** revealed multifocal stenosis in bilateral ACAs, MCAs, and PCAs in addition to the high signal change at bilateral frontoparietal and left occipital lobes. After emergent cesarean section and treatment with phenytoin, levetiracetam, and nimodipine, her general condition gradually returned to normal.

註解 [SC6]: And MRA?

Conclusion We reported two middle-aged women with headache whose image studies showed the findings of both PRES and RCVS. We suspect that the vasogenic edema seen in the PRES and the multifocal stenosis of cerebral vessels in the RCVS may share some common pathophysiology. Brain MRI and MRA may be indicated in patients whose CT scan showed the findings of PRES. Prompt diagnosis and adequate treatment are crucial for preventing brain damage and irreversible neurological deficits.

131

偏頭痛患者腦波頻譜於近頭痛期之正常化現象

賴冠霖^{1,2,3,4} 蕭富榮⁵ 廖光淦^{2,3} 傅中玲^{2,3}

王署君^{2,3,5}

¹ 台北市立關渡醫院神經內科, ² 台北榮民總醫院神經內科, 國立陽明大學醫學院³ 醫學系, ⁴ 臨床醫學研究所, ⁵ 腦科學研究所

Normalization of EEG Power Spectrum in Patients with Migraine During Peri-ictal Periods

Kuan-Lin Lai^{1,2,3,4}, Fu-Jung Hsiao⁵, Kwong-Kum Liao^{2,3}, Jong-Ling Fuh^{2,3}, Shuu-Jiun Wang^{2,3,5}

¹Department of Neurology, Taipei Municipal Gandau Hospital; ²Neurological Institute, Taipei Veterans General Hospital; National Yang-Ming University School of Medicine, ³Faculty of Medicine, ⁴Institute of Clinical Medicine, ⁵Institute of Brain Science

Background Previous resting EEG spectral analyses in patients with migraine showed inconsistent results. The inconsistency might be related to the spontaneous fluctuation of electrophysiological activity in a

headache state-dependent manner in patients with migraine. On the other hand, EEG gamma-band activity has not yet been adequately evaluated in patients with migraine.

Objective To investigate the resting EEG power spectrum and its relation to migraine state.

Methods Resting EEG data (30 seconds for 3 times) was recorded with 256 Hz sampling rate, and 19 electrodes positioned according to the international 10-20 system, while the subjects kept awake and alert without attention demand or cognitive load. After manual and automatic rejection of artifacts, independent component analysis (ICA) was applied to remove the noises. Minimum norm estimate (MNE) analysis was then used to transform the original electrode-based EEG signal into specific brain region-of-interest (ROI)-based EEG activity. After fast Fourier transformation (FFT), individual alpha frequency (IAF) peak was firstly determined. With reference to the IAF, the frequency bands of interest were classified into delta (IAF-8 to IAF-6 Hz), theta (IAF-6 to IAF-2 Hz), alpha (IAF-2 to IAF +2), beta (13-30 Hz), and gamma (30-40 Hz). Furthermore, a normalization of spectral power was done by normalizing the power at each frequency band with total power from delta to gamma to reduce the inter-individual variability. We then compared the relative power of each band across all ROIs in patients with migraine and control subjects. Statistical significance was defined as a

p-value of < 0.05. All tests were two-tailed.

Results One hundred and twenty-seven episodic migraine patients were recruited (M/F: 29/98, age: 35.1 ± 10.3, headache frequency: 4.3 ± 2.6 (days/m). Compared to age- and gender-matched controls (n=20, M/F: 8/12 [*p*=0.163], age: 36.4 ± 6.8 [*p*=0.454]), patients during inter-ictal period (n=75) showed decreased alpha and theta power over the whole brain and increased delta power over bilateral frontal regions. These spectral abnormalities were less obvious or normalized during pre-ictal (n=21), ictal (n=19) or post-ictal (n=12) periods. Of note, compared with controls, patients with migraine had a consistent increment of beta- and gamma-band powers regardless of their clinical headache state.

Conclusions Resting EEG spectral analysis in patients with migraine showed a state-dependent fluctuation at delta-, theta- and alpha-band range, which tended to be normalized during peri-ictal periods. Besides, we found that gamma-band power, and beta-band power to a lesser extent, were consistently increased in patients with migraine, which deserves further studies to evaluate its potential as a non-invasive biomarker.

132

偏頭痛失能量表與偏頭痛病人皮質厚度關聯性之分析

賴資賢¹⁻³ 龔怡嘉² 傅中玲^{3,4} 周坤賢² 林慶波²
王署君^{3,4}

¹亞東醫院神經內科 ²陽明大學神經科學研究所
³醫學系 ⁴台北榮總神經內科

Investigating the correlation between

Migraine Disability Assessment Scale and cortical thickness in patients with migraine

1-3Tzu-Hsien Lai, MD; 1Yi-Chia Kung, MA; 2, 4Jong-Ling Fuh, MD; 1Kung-Hsien Chou, PhD; 1Ching-Po Lin, PhD; 2, 4Shuu-Jiun Wang, MD

¹Section of Neurology, Department of Internal Medicine, Far Eastern Memorial; ²Institute of Neuroscience and ³Department of Medicine, National Yang-Ming University; ⁴Department of Neurology, Neurological Institute, Taipei Veterans General Hospital

Objective To discover the main causes of MIDAS whether related with emotion or not from the clinical and neuroimaging researches.

Method First, we examined the relationship between MIDAS score and clinical variables by the multiple regression analyses. We then examined the relationship between cortical thickness change and Migraine Disability Assessment (MIDAS) score within 94 migraine patients, including 34 episodic migraine (EM) patients and 60 chronic migraine (CM) patients. In the end, the relationship between emotional variables, depression and anxiety score of HADS, and MIDAS-associated brain areas were analyzed.

Results The migraine frequency explained the highest variance of the MIDAS score together with migraine patients ($R^2=0.244$), followed by depression score, photophobia, and migraine intensity with a total variance of 43.6% (F-value=9.406, *p*<0.001). Cortical thickness was negatively

correlated with MIDAS score in patients with migraine over left superior temporal, left precentral, left supramarginal, left superior frontal, left temporal pole, right insula, and right inferior temporal areas.

Conclusions From both the behavioral and biological evidences, the disability assessed by MIDAS was not only related with migraine per se, but also the comorbid depression though the design of this questionnaire has no mention of the emotion questions.

133

頸因性頭痛—一案例報告

蘇慧真 林典佑 許永居 王博仁

活水神經內科診所

國立成功大學附設醫院神經內科

戴德森醫療財團法人嘉義基督教醫院神經內科

Cervicogenic headache- A case report

Hui-Chen Su¹ Tien-Yu Lin² Yung-Chu Hsu³

Po-Jen Wang¹

¹ Living Water neurological clinic, Tainan, Taiwan

² Department of neurology, National Cheng-Kung University Hospital, Tainan, Taiwan

³ Division of Neurology, Department of Internal medicine, Ditmanson Medical Foundation Chia-Yi Christian Hospital, Taiwan

Background Cervicogenic headache is known as a secondary headache originating from neck including cervical spine, nerve and muscle. The criteria of cervicogenic headache in ICDH-II were proposed. However, the differential diagnosis with cervicogenic headache is quite important and the clinical presentation sometimes bothered the neurologist. We presented a patient with symptomatic headache compatible with

cervicogenic headache clinically.

Report of Cases A 49 year-old worker without headache history visited the outpatient clinic due to abrupt thunderclap headache while walking in the previous night. He complained persistent, extremely severe headache over left temporal-occipital area which was exacerbated with neck movement, cough and swallowing and was not relieved by any medicine at all. And, his motion of neck was restricted because of his severe headache and neck pain. The initial results of neurologic examination were unremarkable except presentation of bilateral Babinski signs. On the other day, progressive urinary difficulty was reported; besides, hypethesia over right extremities and left upper limb minor weakness were noticed. Brain computed tomography revealed segmental hyperdense lesion from left side cervicomedullary junction to C4 cervical cord. Cervical MRI with gadolinium enhancement showed segmental lesion with hypointense signal on T1WI and hyperintense signal on T2WI, with a small enhancing nodule within the left C1 spinal cord. The patient received C1 laminectomy with grossly total excision of intramedullary lesion and duraplasty. Pathological findings commented that there are aggregates of small-caliber vessels with thin wall

without presentation of elastic fiber after Verhoeff-van Gieson stain, suggesting vascular malformation. The headache relieved after his operation.

Discussion The cervicogenic headache is a secondary headache with prevalence of 1-4%, and much higher to 53% in patients after neck trauma. It is less common than migraine and tension-type headache and is underdiagnosed easily. Although the pathophysiology is still debated, several disorders share similar feature as cervicogenic headache including dissecting aneurysm of vertebral/carotid artery, posterior fossa lesion, neck-tongue syndrome, C2 neuralgia and cervical migraine, etc. The diagnosis of cervicogenic headache indeed is a challenge to the physicians. Our patient presented as severe headache and neck pain which correspond with the clinical criteria of cervicogenic headache and it resulted from rupture of cervical vascular malformation.

神經放射線學

134

三叉神經神經鞘許旺氏細胞瘤引起之
三叉神經感覺及運動病變：案例報告

周政達 梁仁峯

台北榮民總醫院神經醫學中心神經內科

**Trigeminal Schwannoma presented as
trigeminal sensorimotor neuropathy: A
case report**

Chen-Ta Chou, Jeng-feng Liang

Department of Neurology, Neurological Institute,
Taipei Veterans General Hospital

Background Trigeminal neuropathy with motor involvement are relative uncommon and the etiology is diverse. Trigeminal Schwannomas are the second common intracranial Schwannomas next to the vestibular Schwannomas. The most common symptom is facial hypesthesia and pain; masseter muscle atrophy is relatively rare.

Case Report A 58-year-old male suffered from progressive facial paresthesia and pain located at the dermatome of left mandibular nerve (V3) for 4 months. Two months following the onset of paresthesia, the patient noted atrophy of his masseter muscle. Blink reflex study revealed normal result while needle electromyography showed active denervation change over masseter muscle which was compatible with trigeminal motor neuropathy. The sella computed tomography did not show any abnormality. A posterior fossa MRI scan was arranged thereafter but still revealed no intracranial lesion. Due to symptom progression, we arranged thin-section MRI (1.5mm focused on sella) 3 weeks after the previous MRI study and disclosed a 1.6* 1.5* 0.3 cm tumor at cavernous sinus and temporal floor with extracranial extension via foramen ovale adhered to mandibular nerve. After the tumor removal, the pathologic report revealed Schwannoma. This patient got

improvement in paresthesia after the operation.

Discussion The common causes of trigeminal neuropathy include trauma, neoplasm, inflammation/autoimmune diseases or idiopathic. Most trigeminal neuropathy caused sensory symptoms such as pain, numbness or loss of sensory, but sometimes motor symptom was noted. However, motor involvement with muscle wasting may rarely be seen in autoimmune/ inflammatory related or idiopathic trigeminal neuropathy. The existence of trigeminal nerve-innervated muscle atrophy raises the concern of mass lesion and warrants a detailed image study.

Conclusion Trigeminal neuropathy with motor involvement is rarely idiopathic. A small tumor, such as trigeminal Schwannoma is a possible etiology. Thin-section MRI study is required for these cases if preliminary image study is fail to demonstrate the lesion.

135

Chiari 氏畸形第一型併脊髓空洞症 – 以單側背心狀感覺缺損表現

林鴻志¹ 馮偉雄² 劉競雄³
羅東博愛醫院 神經內科

Type I Chiari malformation with severe syringomyelia presented with unilateral “vest-like” sensory impairment

Hung-Chih Lin, Vai-Hong Fong, Ching-Hsiung Liu
Department of Neurology, Lo-Tong Pohai Hospital, I-Lan, Taiwan

Background Chiari malformation (CM) is a congenital disorder in which the cerebellar tonsils protrude through the foramen magnum into the spinal cord. There are four types of CM, and CM type I (CM-I) can occur in children and adults and may or may not be symptomatic. Syringomyelia is present in 25% of patients with Chiari Malformation.

Case report A 14 years old girl has experienced slowly progressive inability to feel hot sensation when taking shower and feel tingling pain by mosquito sting over neck, upper arm and upper back on the left side for 2 years. Initially, Brain CT and EP study showed normal finding 2 years ago . Recently , expansion of the location of sensory impairment was noted. She denied previous headache, neck or back pain ,tinnitus, vertigo, limb weakness, numbness , unsteadiness of gait , urine or stool disturbance. No previous history of traumatic head, neck or cervical injury. The neurological examination revealed loss of pin prick and temperature sensation over left neck,upper arm and left upper trunk above T9 level(unilateral vest-like pattern) with preservation of soft touch and proprioception. Brain and spinal MRI showed a elongated, peg-shaped cerebellar tonsils extending below the foramen magnum and a syringohydromyelia at whole spines. The final diagnosis was Chiari

malformation with syringomyelia. No medical management was advised because of no headache or any painful sensation. We referred this patient to medical center for further evaluation of pediatric neurosurgeon. No clinical improvement of sensory deficit after drainage of CSF was mentioned by patient about 1 year later.

Conclusion We report a case of late childhood onset CM-I with syringomyelia which clinically presented with painless unilateral “vest-like” sensory loss. The presence of syrinx is known to give specific signs and symptoms that vary from dysesthetic sensations to algethmal dissociation to spasticity and paresis, and is one of absolute indications for surgical intervention.

136

腦中類澱粉蛋白沈積、多巴脫羧酶活性及葡萄糖代謝在一位 Logopenic 失語症合併巴金森症候群患者的表現

范齡勻¹ 王樹聲² 林靜嫻³ 陳達夫³ 曾凱元⁴
顏若芳⁴ 邱銘章³

¹ 恩主公醫院 神經科

² 國立台灣大學醫學院附設醫院 家庭醫學科

³ 國立台灣大學醫學院附設醫院 神經科

⁴ 國立台灣大學醫學院附設醫院 核子醫學科

Amyloid Retention, DOPA Decarboxylase Activity and Glucose Metabolism in A Patient with Logopenic Aphasia and Parkinsonism

Ling-Yun Fan¹, Shu-Sheng Wang², Chin-Hsien Lin³, Ta-Fu Chen³, Kai-Yuan Tzen⁴, Ruoh-Fan Yen⁴, Ming-Jang Chiu³

¹Department of Neurology, En Chu Kong Hospital

²Department of Family Medicine, National Taiwan University Hospital

³Department of Neurology, National Taiwan University Hospital

⁴Department of Nuclear Medicine, National Taiwan University Hospital

Background Logopenic aphasia (LPA) variant of primary progressive aphasia (PPA) is featured with word retrieval difficulty without memory impairment. The underlying pathology of LPA is mostly linked to amyloid A β deposition, as in Alzheimer’s disease. As compared to another variant of PPA, progressive nonfluent aphasia, LPA is rarely reported to associate with parkinsonism and the underlying mechanism is unclear. Using conventional and nuclear imaging studies, we measured whole-brain amyloid deposition, glucose metabolism, and dopa decarboxylase activity in a patient with LPA and asymmetric parkinsonism.

Case Report A 74-year-old healthy man began to have word-finding difficulties and decreased verbal output since two years ago with preserved comprehension and grammar abilities. PPA was clinically diagnosed according to Mesulam’s criteria. Memory and other cognitive impairment developed about one-year later. Parkinsonism feature with right limbs clumsiness, right jaw tremor and facial myokymia gradually developed later. Neuropsychological test revealed deficits in language, visuospatial and both verbal/non-verbal memory functions with MMSE was 6 (education: 6 years). Brain magnetic resonance image (MRI) demonstrated asymmetrical atrophy in the left perisylvian, temporal and parietal areas. The [18F]FDG scan showed hypometabolism in the areas corresponding to MRI atrophy with preserved and symmetrical metabolism of basal ganglia. Consistent with previous report, the amyloid retention was diffuse throughout cortexes and basal ganglia without asymmetry.

Unexpectedly, the [18F]FDOPA scan revealed symmetrical and normal uptake in bilateral basal ganglia, suggesting no obvious pre-synaptic dopaminergic neuronal loss with intact dopa decarboxylase activity. The genetic analysis for C9orf72 gene was normal without increased number of hexanucleotide repeats.

Conclusion Our case demonstrated the patterns of preserved and symmetrical glucose metabolism and dopa decarboxylase activity in bilateral basal ganglia, which are different from the findings of corticobasal degeneration (CBD), and Parkinson's disease with dementia. Our findings support a disorganized sensorimotor model that disintegration of circuits between left temporal-parietal cortex and basal ganglion due to cortical amyloid deposition and cortical hypofunction causing the asymmetrical Parkinsonian features in our patient rather than presynaptic dopaminergic dysfunction or neuronal loss.

137

以逐體素為基礎的型態計量學之整合分析來評估猝睡症患者的腦結構變化

翁旭惠¹ 蔡元雄¹ 陳志峰¹ 楊子賢¹ 李建德² 許家瑜³ 楊俊毓⁴

¹嘉義長庚紀念醫院 放射診斷科

²嘉義長庚紀念醫院 神經內科

³雲林長庚紀念醫院 神經內科

⁴高雄醫學大學 公共衛生學系

Meta-analytical Comparison of Voxel-Based Morphometry Studies in Narcolepsy

Hsu-Huei Weng¹, Yuan-Hsiung Tsai¹, Chih-Feng Chen¹, Tzu-Hsien Yang¹, Jiann-Der Lee², Chia-Yu Hsu³, Chun-Yuh Yang⁴

¹Department of Diagnostic Radiology, Chang Gung Memorial Hospital at Chia-Yi, Taiwan.

²Department of Neurology, Chang Gung Memorial Hospital at Chia-Yi, Taiwan.

³Department of Neurology, Chang Gung Memorial Hospital at Yun-Lin, Taiwan.

⁴Faculty of Public Health, College of Health

Sciences, Kaohsiung Medical University, Kaohsiung

Background Voxel-based morphometry (VBM) is an automatic unbiased method to detect group differences in the gray matter (GM). Neuroimaging meta-analysis methods are available recently.

Objective To identify consistent and specific structure changes in patient with narcolepsy by reviewing the literature on the results of VBM of MR imaging studies.

Methods We searched PUBMED for the relevant articles published from January 2000 to November 2011. This review included all VBM research papers using the signed differential mapping (SDM) procedure to compare either GM concentration or GM volume to index GM differences between narcolepsy patients and normal controls.

Results People with narcolepsy had regional GM reduction in right hypothalamus, left anterior cingulate gyrus (BA 32), both sides of inferior frontal gyrus (BA 47), left medial frontal gyrus (BA 10) and left middle temporal gyrus (BA 21), which may be related to the daytime sleepiness, attention and memory abnormalities seen in this patient population.

138

以磁振神經纖維追蹤技術評估顳葉梗塞造成之偏癱合併同側小腦運動失調

陳兆煒 陳晉誼 鄧浩文

台北醫學大學-萬芳醫院神經內科

Ataxic hemiparesis syndrome caused by parietal infarction: a case evaluated by MR tractography

Jowry Tani, Chin-I Chen, Hao-Wen Teng

Department of Neurology, Wan Fang Hospital, Taipei Medical University

Background Ataxic hemiparesis, one of the classical lacunar stroke syndromes, is most commonly caused by lesions in pons, the internal capsule, or the corona radiata. Although rare, that had been reports that infarction involving posterior parietal lobe can cause ataxic hemiparesis. In the present report, we utilized diffusion tensor imaging (DTI) to study the pathway involved in an ataxic hemiparetic patient with frontoparietal cortical infarction.

Case report A 61-year-old man presented to us with right limbs weakness and ataxia. Sensory examinations were normal for light touch, pinprick, temperature, proprioception, and vibratory sensation. A brain magnetic resonance imaging (MRI) demonstrated acute infarction of left parietal cortical area and frontal cortex. DTI tractography revealed that the cerebellothalamoparietal fibers connecting the left posterior parietal lobe to the right cerebellum passed through the infarcted region.

Conclusion Tractography in the present case demonstrated a cerebellothalamoparietal tract connecting right cerebellum to the portion of left posterior parietal lobe. Ataxia of right limbs might be related to the left posterior parietal lobe infarction, and the underlying mechanism might be related to the involvement of the cerebellothalamoparietal tract. The weakness of right limbs in our case might be due to infarction of left paramedian precentral cortex.

139

紅斑性狼瘡併疑似栓塞性血小板減少紫斑症及可逆性腦炎: 病例報告及文獻回顧

郭峰嶸¹ 劉濟弘^{1*} 秦嗣騏² 李宗海¹

林口長庚紀念醫院¹ 神經內科² 放射診斷科

Reversible Encephalopathy in Systemic Lupus Erythematosus and Thrombocytopenia Mimic Thrombotic Thrombocytopenic Purpura: Case Report and Literature Review

Yeh-Jung Kuo¹, Chi-Hung Liu^{1*}, Shy-Chyi

Chin², Tsong-Hai Lee¹

¹ Department of Neurology, ² Department of Medical Imaging and Intervention, Chang Gung Memorial Hospital, Linkou Medical Center

Background Thrombotic thrombocytopenic purpura (TTP) and acute flare up of systemic lupus erythematosus (SLE) share several common features including thrombocytopenia, acute renal failure, and central nervous system (CNS) involvements.

Case report A 36-year-old male with underlying SLE experienced progressive bilateral lower leg swelling related to acute renal failure (creatinine: 4mg/dL). His hemogram showed thrombocytopenia (70000/uL), anemia (Hb7.4 g/dL) with normal fibrinogen (316 mg/dL) and prothrombin time. Biochemistry revealed normal LDH (361 U/L), direct/total bilirubin(0.2/0.5mg/dL) and haptoglobin (26.2 mg/dL). Serology studies disclosed decreased C3 (36.7mg/dL), C4 (6.31mg/dL) and elevated anti-ds DNA (333.9WHO U/mL). Intravenous methylprednisolone was given. However, headache and five times of grand mal seizure occurred without full recovery of consciousness and muscle strength. Brain magnetic resonance imaging showed diffusion restriction in the bilateral thalamus with extensive hyper-intensities in the bilateral parieto-occipital lobes, cerebellum and basal ganglion in T2-weighted sequence. Both the arterial and venous system was patent. Plasma exchange was initiated and his conscious and neurologic dysfunction recovered. However, the follow-up images remained unchanged.

Conclusion Both CNS lupus and TTP could occur simultaneously, and present seizure, reversible encephalopathy, thrombocytopenia, acute renal failure, and responsiveness to plasma exchange. However, the mortality rate was different. Microangiopathic hemolytic anemia or renal biopsy may help to define the

presence of TTP.

140

無病灶之顳葉癲癇之發作間期

SPECT :個案系列研究

蔡青芳 黃欽威

國立成功大學醫學院附設醫院神經部

Interictal SPECT in nonlesional temporal lobe epilepsy: A case series study

Ching-Fang Tsai, Chin-Wei Huang

Department of Neurology,

National Cheng Kung University Hospital

Objective Lesional temporal lobe epilepsy (TLE) with mesial temporal sclerosis usually shows consistent temporal hypoperfusion in interictal SPECT, clinical intractability and poor cognitive performance. Nevertheless, the clinical indicators associated with intractability and cognitive performance in nonlesional TLE remains incompletely understood. We aim to study the role of interictal SPECT on nonlesional TLE.

Methods We identified patients with clear TLE semiology but without a definite lesion in brain magnetic resonance image (MRI) in the Neurological Clinic in our hospital. Seizure-related demographics were studied. Functional evaluation including electroencephalography (EEG) and interictal SPECT were done. Cognitive evaluation was done using cognitive assessment screening instrument (CASI).

Results A total of 9 people with nonlesional TLE were recruited and analyzed. There were six male and three females. The age of seizure onset ranged from 11 to 37 years. More than half (5/9, 55.6%) had intractability and three of them (33.3%) had bilateral temporal spikes in EEG. Four of them (44.4%) had normal interictal SPECT. Among these four patients, two (50%) had intractability and three (75%) had normal cognitive performance. Bilateral temporal hypoperfusion in interictal SPECT correlated well with bilateral temporal spikes in EEG. Among the six patients with either uni- or bi-temporal hypoperfusion, four of them (66.7%) had correspondent EEG findings.

Conclusion Normal interictal SPECT may indicate normal cognitive performance, but still may be associated with intractability in nonlesional TLE. Most of the abnormal interictal SPECT correlated well with EEG, esp. those with bilaterality. A larger case-control study on nonlesional versus lesional TLE would be warranted.

神經感染疾病學

141

單獨以雙側顏面神經麻痺作為梅毒初期表現之症狀

丁吉新^{1,2} 王志偉³ 楊富吉¹

¹ 三軍總醫院神經內科部

² 國軍台中總醫院內科

³ 三軍總醫院放射科部

Isolated Bilateral Facial Nerve Palsy as

an Initial Manifestation of Syphilis

Chi-Hsin Ting^{1,2}, Chih-Wei Wang³, Fu-Chi Yang¹

¹ Department of Neurology, Tri-Service General Hospital, National Defense Medical Center,

² Department of Internal Medicine, Taichung Armed Forces General Hospital,

³ Department of Radiology, Tri-Service General Hospital, National Defense Medical Center

Abstract

Background Bilateral facial paralysis is a rare condition and represents a diagnostic challenge. Herein, we report the case of a 22-year-old man with bilateral facial paralysis as the sole initial manifestation of syphilis.

Case Report The patient initially presented with isolated bilateral facial nerve palsy without any other symptom. At that time, all serum and cerebrospinal fluid examinations [including the rapid plasma regain (RPR) titer] yielded were normal. Within 2 weeks, he developed rashes on the palms and soles, suggesting the possibility of syphilis. At this time, we were informed that he had a history of unprotected sexual exposure, and his serum was positive for the RPR and *Treponema pallidum* hemagglutination tests. Treatment with high dose penicillin G was effective, and he was discharged with improvement of the rashes and with only mild peripheral type facial palsy on the right side.

Conclusion This is a rare case in which a young man with syphilis initially presented with bilateral

peripheral facial palsy. Bilateral facial palsies usually reflect many etiology . The differential diagnosis includes MG, skull base metastasis, Hansen's disease, and etc. Syphilis be considered during the differential diagnosis of bilateral facial nerve palsy in young men with sexual exposure, even if the initial skin manifestation of syphilis is lacking.

142

人類疱疹病毒引致脾臟體壓部回復性
損傷併脊髓發炎與腰薦椎多神經根炎：
個案報告

王威仁 陳凱翔

台大醫院新竹分院 神經內科

Human Simplex Virus Induced Reversible Splenic Lesion, Myelitis and Lumbo-Sacral Polyradiculitis : A Case Report

Wei-Jen Wang, Kai-Hsiang Chen

Department of Neurology, National Taiwan

University Hospital Hsin-Chu Branch, Hsin-Chu,

Taiwan

Background Mild encephalitis/encephalopathy with reversible splenic lesion(MERS) is a MRI finding induced by variable condition. Most reported etiologies were CNS infection, epilepsy, and anti-epileptic drug usage or withdrawal. Others, like metabolic problems, high-altitude illness, and autoimmune disease were also reported. Here we report a 26-year-old man presented with human simplex virus (HSV) induced MERS and accompanied with meningoencephalomyelitis and

lumbosacral polyradiculitis.

Case Reports a 26-year-old man, who had fever lasting for 1 week, admitted due to acute urinary retention, disoriented consciousness, and bilateral lower limbs weakness. Neurologic exam revealed positive meningeal sign and CSF study showed leukocytosis WBC: 125 (lymphocyte: 78%), RBC: 820, xanthochromic:+ with elevated CSF-protein (233mg/dL). CSF HSV PCR was positive. There are no other autoimmune or infectious profiles identified. Brain MRI showed isolated diffusion restriction at splenium without contrast enhancement. Progressive bilateral lower limbs (MRC:3/5) and hypesthesia below T6 sensory level with decreased tendon reflex over bilateral knee and ankle jerks during admission. T-spine MRI revealed myelitis from upper T3 to L5 level with meningeal enhancement around conus medullaris. Nerve conduction study revealed absence of F-wave and H-reflex implicated lumbo-sacral polyradiculitis. We added on steroid pulse therapy (methylprednisone 1g/day) under the full course of Acyclovir treatment. Clinical symptoms improved gradually after steroid usage. Followed-up brain MRI on day 14 showed absence of the splenic lesions. The patient can walk by himself without assistance after tapering steroid.

Conclusion MERS induced by viral infection presented with cytotoxic edema usually had a benign natural course. The pathophysiology is still undetermined but probably due to outburst of immune reaction with transient neuron oxidative damage. Our patient with MERS has more extensive nervous system involvement but with a similar prognosis. The steroid pulse therapy could be the key treatment for his prognosis.

143

案例報導 : 疑似結核菌腦膜炎合併蜘蛛膜下腔出血之案例

呂潔皎 許怡婷

中國醫藥大學附設醫院¹ 神經部² 暨神經精神醫學中心

Case report: Subarachnoid and subdural hemorrhage as a complication of Suspected tuberculous meningitis

Chieh-Min Lu, Yi-Ting Hsu

Department of Neurology¹ and Center for Neuropsychiatry², China Medical University Hospital, Taichung, Taiwan

Background Meningitis are sometimes associated with intracranial hemorrhage. Among the pathogen, some lack sensitive detective parameter and hardly provide positive yields in culture, including fungus and atypical pathogen as legionella or TB. Although TB meningitis is confirmed via CSF study results, there could be false negative of pathogen survey. Here we report a patient presented with chronic meningitis complicated with skull base osteomyelitis and ventriculitis following by subarachnoid and subdural hemorrhage.

TB meningitis is suspected via image finding and clinical course, though objective CSF results for TB survey is lack.

Case Report This 73 y/o male farmer with type II diabetes mellitus suffered from insidious onset of intermittent fever and headache for 2 months following by bilateral abducens nerve palsy. Initially, he received standard ceftriaxone and vancomycin for bacteria meningitis diagnosed by CSF findings (neutrophilic predominant pleocytosis, low sugar and elevated protein content. There was no data for TB studies because the initial result suggested bacterial meningitis. However, deteriorated headache and right hypoglossal nerve palsy developed. Brainstem MRI revealed osteomyelitis in the skull base and upper cervical region with exudate within the ventricle and external ventricular drain was then performed. Nevertheless, there is limited improvement of infection picture. Reviewing the pathogen survey, both fungus and bacterial pathogen failed to yield in culture. Although tuberculosis profile including culture and PCR were negative, anti-TB meningitis therapy was used owing to the clinical course, image finding and refractory to empiric treatment. After combined usage of anti-TB formula and previous antibiotics, there was a transient clinical downhill suspected therapeutic

paradox, though this course could not confirm or refute the diagnosis of TB meningitis. However, there was dramatic conscious change on further admission day. Emergency brain image showed subarachnoid and subdural hemorrhage. Further surgical intervention was denied by family. The patient expired as an end result.

Discussion Tuberculosis meningitis is a devastating disease of the central nervous system that usually presents with prodromal phase of chronic headache and low grade fever, followed by acute onset of cranial nerve neuropathy and further sign of parenchyma involved. Infectious intracranial aneurysms and subsequent subarachnoid hemorrhage are rarely encountered complication. Due to the rarity of these lesions and variability in their evolution and clinical presentations there is no widely accepted management. Awareness of the clinical and radiologic findings along with awareness of the possible complications can help guide early treatment or surgical intervention.

144

感染人類後天免疫不全症候群病毒相關的年輕型失智症

宋兆家 吳亞榮

新光吳火獅紀念醫院神經科

HIV-associated dementia

Jau-Jia Sung, Ya-Ying Wu

Department of Neurology, Shin Kong Wu Ho-Su Memorial Hospital, Taipei

Background The prevalence of HIV infection is increasing in recent years.

About 20~30% of HIV infected patients developed HIV-associated dementia. No data existed on percentages of HIV infection in dementia patients.

Case Report A 41-year-old man, previously an English teacher, was admitted because of progressive memory decline, mild unsteady gait and urine incontinence for 4 months. His family also noted the patient became more irritable and slow in response. The neurological examination revealed poor short-term memory and bilateral lower limbs weakness with present Babinski sign. The score of mini-mental status examination was 23. CASI revealed severe memory impairment under intact attention and concentration. Mild to moderate impairment of visuospatial, constructional ability and higher function were also noted. Blood test revealed positive HIV screen with ELISA method and Western blot. Absolute CD4 count was low (35 cells/uL). CSF studies were normal. Brain MRI showed mild diffuse brain atrophy. Brain perfusion scan with Tc-99m ECD revealed hypoperfusion in bilateral temporal lobes. HIV-associated dementia was diagnosed and HARRT regimen started after infection doctor consultant.

Conclusion The population of HIV infected patient is increasing in recent

year, and the age of HIV infection become much more younger. While managing dementia of young age, HIV infection should be tested. Treatment of HIV infection should start as soon as possible for delaying the progression of HIV-associated dementia.

145

NMOSD 病患 AQP4 抗體之定量研究及其臨床應用

李照琳 陳紹原 王凱震 蔡清標
國立陽明大學附設醫院神經內科 耕莘醫院神經內科 振興醫院神經內科 台北榮總神經內科

Quantitative Measurement of AQP4 Antibodies of NMOSD Patients in Taiwan and its Clinical Implication

Chao-Lin Lee, Shao-Yuan Chen,
Kai-Chen Wang, Ching-Biao Tsai
Department of Neurology, National Yang-Ming University Hospital, I-Lan, Taiwan
Section of Hyperbaric Oxygen Medicine, Cardinal Tien Hospital, Taipei, Taiwan
Department of Neurology, Cheng Hsin General Hospital, Taipei, Taiwan
The Neurological Institute, Taipei Veterans General Hospital, Taipei, Taiwan

Background The presence of antibodies to aquaporin-4 (AQP4) has been identified as a key characteristic of neuromyelitis optica spectrum disorder (NMOSD), an autoimmune inflammatory demyelinating central nervous system (CNS) disorder. We determined the presence of AQP4 antibodies by cell-based indirect immunofluorescence assay (CIIFA) and Home-made ELISA kit respectively, and evaluated the diagnostic and prognostic relevance of AQP4 antibodies of patients with NMOSD in Taiwan.

Methods 18 serum samples from 12 NMOSD and 6 healthy patient as a comparison set from a neurology clinic were included. Home-made ELISA kit and cell-based indirect immunofluorescence assay (CIIFA) were performed.

Results The quantitative measurement of AQP4 antibodies by home-made ELISA kit correlated well with the results derived from CIIFA. The AQP4 antibodies were significantly higher in patients with long-cord lesion of NMOSD than in those with short-cord lesion of NMOSD. There is a significant difference of AQP4 antibody titers between relapse and remission groups of NMOSD.

Conclusion Quantitative measurement of AQP4 antibodies by our Home-made ELISA kit was well correlated with CIIFA and provides the possibilities of predication of the extent of spinal cord lesions and monitoring of disease progression or treatment response in NMOSD. However, the relevance of its clinical use needs to be actively investigated in a prospective study on a large scale.

146

免疫缺陷病毒感染病患使用高效抗逆轉錄病毒治療後表現進行性多發性腦白質病變

李翰道 宋崇元 張國軒
林口長庚紀念醫院 神經內科

Progressive multifocal encephalopathy unmasked by HAART in a HIV-infected patient

Han-Tao Li, Chung-Yang Sung, Kuo-Hsuan Chang

Department of Neurology, Chang-Gung Memorial Hospital and University College of Medicine, Lin-Kou Medical Center

Abstract

Background. For patients with HIV/AIDS, highly active antiretroviral therapy (HAART) is currently the only effective therapy. Here we report a case of progressive multifocal leukoencephalopathy (PML), a subacute demyelinating disease caused by infection of oligodendrocytes by the polyomavirus JC, occurs after HAART.

Case Report A 52-year-old HAART-treated HIV-1-infected male patient began to develop progressive cognitive impairment, disorientation, and right limb weakness for about two months before admission. His neurological examinations showed motor aphasia, acalculia, and ideomotor apraxia. Hemiplegia, hyperreflexia and present Babinski sign were noted on his right limbs. His brain magnetic resonance imaging (MRI) showed T2-weighted hyperintense lesions in left frontal white matter and calloseseptal area. Laboratory tests found low CD4 T-cell counts of 433 cells/ μ L and high HIV-RNA viral load of 43,292 copies/mL. The stereotatic brain biopsy showed inflammatory infiltrations, gliosis with focal demyelination, and intranuclear inclusion positive for anti-JC virus antibody, which was compatible

with PML. His neurological deficits became stable following a short-term treatment with dexamethasone and mannitol. And then his HAART with Combivir and Efavirenz was restarted.

Conclusion PML could occur in HIV-infected patients following HAART. The mechanism for the reactivation of JC virus by immune reconstitution remains elusive.

147

以全程口服類固醇 Prednisolone 合併抗結核藥物成功治療結核性腦血管炎：一病例報告

周美鵬¹ 余錫婷² 楊淵韓¹

高雄市立大同醫院 (委託財團法人私立高雄醫學大學附設中和紀念醫院經營)¹神經內科
²護理部

Successful treatment of tuberculous cerebral vasculitis with full-course oral predinsolone combined with antituberculous drugs : a case report

Mei-Chuan Chou¹, His-Ting Yu², Yang-Yuan Han¹

¹Department of Neurology

²Department of Nursing
Kaohsiung Municipal Ta-Tung Hospital

Introduction Tuberculous cerebral vasculitis is a neurological complication of tuberculous meningitis. We reported the imaging of tuberculous cerebral vasculitis and successful treatment with oral predinsolone throughout the course of antituberculous treatment.

Case report This 19 year-old woman, a college student with no remarkable medical history, was diagnosed with

tuberculous meningitis by clinical response to antituberculous treatment. The initial presentation was a 2-month history of headache, a 3-day history of fever and first generalized tonic/clonic seizure. Blood human immunodeficiency virus (HIV) test was negative. The symptoms improved dramatically after initiation of antituberculous medication on four-drug regimen. However, due to severe increased intracranial hypertension, dexamethasone was administered 5mg q 8hours intravenously with tapering dosage followed by oral prednisolone tapered gradually over 6 weeks after discharge. After treatment with antituberculous medication for 2 months, the course was complicated with tuberculous myelitis involving spinal cord at C3-5 level and T7-9 level. Pulse methylprednisolone therapy was given 1000 mg daily for 3 days with following oral prednisolone at daily dosage 60 mg with tapering 10mg per week.

In the 5th month, she presented with 2-week history of episodic dystonia involving left hand and left foot and forgetfulness. Brain FLAIR MRI revealed extensive irregular hyperintense lesions with peripheral enhancement mainly involving corpus callosum, bilateral cerebral deep white matter, subcortical white matter of right parietal and left temporal lobes, bilateral basal ganglia, midbrain, pons, and medulla which were compatible with tuberculous cerebral vasculitis with vasogenic edema.

Follow-up CSF study showed nearly normal CSF profile except mild elevation of protein (CSF protein 67 mg/dl). A seven-day course of dexamethasone was administered 5mg q 8hours intravenously with tapering dosage. Oral prednisolone at daily dosage 60 mg was prescribed later with tapering 10mg per week then with maintenance dosage at 10mg/day throughout the course of antituberculous treatment. Follow-up brain MRI after 2 months revealed mild improvement of multiple hyperintensity lesions and further improvement was noticed at full-course antituberculous treatment.

Discussion Corticosteroid has been used for tuberculous meningitis since the 1950s. While some believe corticosteroids improve outcome due to reduce inflammation of small blood vessels and therefore reduce damage from blood flow slowing to the underlying brain tissue, it is possible that steroids may harm tuberculous meningitis by suppressing the immune mechanism. While prescribing steroid, benefits to risks ratio should be considered. Steroid use in tuberculous cerebral vasculitis should not be tapered too rapidly to avoid recurrence of vasculitis. In this case, we maintained the full course of prednisolone after discharging the patient. No recurrence of vasculitis was noticed .

Conclusion Corticosteroids should be routinely used in HIV-negative people with tuberculous meningitis to reduce death and disabling residual neurological deficit amongst survivors. Full-course oral prednisolone of low dose may be helpful for patients with tuberculous cerebral vasculitis.

148

黴漿菌肺炎感染後引起的臂神經叢病變

林冠宇 彭家勳 徐昌鴻

三軍總醫院神經內科 國防醫學院

Brachial plexopathy complicating Mycoplasma pneumoniae infection in a Chinese adult

Guan-Yu Lin, Gii-Sheun Peng and Chang-Hung Hsu

Department of Neurology, Tri-Service General Hospital, National Defense Medical Center, Taipei, ROC

Background Mycoplasma pneumoniae infections are often asymptomatic but can involve multiple organ systems. A immune-mediated pathological mechanism has been suspected to be the main cause of neurological manifestations due to the presence of cross-reactive antibodies to the brain and other neurologic structures

Case Report A previously healthy, 21-year-old man presented with slowly progressive weakness and numbness of his bilateral upper limbs for one week. One month prior to the occurrence of weakness, he had flu-like symptoms lasting for fourteen days with full recovery. He did not have shoulder, scapular or neck pain. Examination

showed normal cranial nerves. The neurological examination, including deep tendon reflexes, was otherwise normal. Pinprick sensation was reduced over the palmar aspect of both fourth and fifth digits. Nerve conduction studies of bilateral upper limbs revealed normal distal latency and F wave, but slow conductive velocity, and reduced amplitude of CMAPs. Sensory nerve conduction studies demonstrated low amplitude of ulnar sensory nerve action and slowing of ulnar sensory nerve conduction velocity. Needle electromyography examination pointed out increased amplitudes, prolonged durations and polyphasic morphology. No muscles demonstrated any fasciculations or complex repetitive discharges. Specific upper limb muscles tested included the following: deltoid, triceps, biceps brachii, extensor indicis proprius, first dorsal interossei, abductor digiti minimi, and abductor pollicis brevis. Cervical paraspinal muscles were normal. These studies indicated the presence of bilateral brachial plexus neuropathies. An MRI of brachial plexus was normal without evidence of organic compression. The neural foramina of the cervical spine were patent. Serology was positive for Mycoplasma pneumoniae IgM. Other lab tests were unremarkable.

Conclusion Onset of his neurological symptoms one month after

Mycoplasma pneumoniae infection implied a causal relationship. The case is being reported for its rarity and to highlight the spectrum of extra-pulmonary complications.

149

病例报告：隐球菌与结核菌共同感染导致的脑膜炎

林奕辰¹ 鄧浩文¹

萬芳醫院神經內科 台北醫學大學

Meningitis caused by Co-infection of Cryptococcus and Tuberculosis

Yi-Chen Lin¹, Hao-Wen Teng¹

¹Department of Neurology, Wan Fang Hospital, Taipei Medical University

Background Tuberculous (TB) and cryptococcal meningitis are the two most common differential diagnoses among all cases of subacute to chronic meningitis. Here we report a case of combined TB and cryptococcal meningitis in a non-HIV patient.

Case Report A 60-year-old male orchid farmer presented with persistent headache followed by gait ataxia for totally 6 weeks. There was no fever, meningismus, blurred vision, or impaired mental status. He had no history of immunodeficiency and the serum anti-HIV titer was negative. Brain MRI revealed diffuse leptomeningeal enhancement and multiple nodular enhancing lesions with perifocal edema at bilateral cerebellar and cerebral hemispheres. CSF study showed normal pressure, lymphocyte-predominant pleocytosis, increased total protein and low glucose levels. The Indian ink and

acid fast stain, TB PCR and cytology study were negative in the CSF.

Although weakly positive in serum, the cryptococcal antigen was negative in the initial two CSF studies. There was no evidence of pulmonary or other extrapulmonary TB except for a positive adenosine deaminase reaction in serum.

After empirical anti-TB treatment including systemic corticosteroid for one month, there was substantial improvement in headache and gait ataxia. Follow-up brain MRI scan and CSF analysis showed almost complete regression of the aforementioned abnormal findings. However, the CSF profiles started to deteriorate and cryptococcal antigen in the CSF began to rise gradually since the 4th week after treatment. The fungal culture obtained from the CSF 4 weeks after anti-TB treatment, but not the initial CSF, yielded *Cryptococcus neoformans*. After antifungal treatment, there was further improvement in CSF data and fever.

Conclusion It has been proposed that reactivation of latent infection may contribute significantly to the development of cryptococcosis. Systemic corticosteroid, which has been included in the standard treatment protocol of TB meningitis in the last decade, can lead to immunocompromised state and theoretically reactivate a latent

cryptococcal infection. From our case it is emphasized that follow-up of CSF studies cannot be omitted in the treatment of subacute to chronic meningitis despite an initial response to treatment.

151

Bocavirus 腦炎在年輕男性引起重積癲癇發作之個案報告

洪煒斌 黃欽威 陳志弘

國立成功大學醫學院附設醫院神經部

Bocavirus related aseptic encephalitis induces status epilepticus in a young male: a case report.

Wei-Pin Hong, Chin-Wei Huang, Chih-Hung Chen

Department of Neurology, National Cheng Kung University Hospital.

Background Status epilepticus related to primary CNS infection in young male is often fulminant with high mortality rate. Especially in aseptic encephalitis, the pathogen is usually not able to be cultured in general hospital except for special methods or sending CSF specimen to centers for disease control for PCR.

Case Report A 21-year-old, otherwise healthy man suffered from new onset complex partial seizure with secondary generalization, and then progressed to status epilepticus. CSF studies showed pleocytosis, lymphocyte predominant, without glucose decrease and only very mildly elevated protein, which suggested aseptic encephalitis. 1 week before symptoms onset, he suffered from mild gastroenteric symptoms of viral infection,

including vomiting and diarrhea.

Acyclovir was used after knowing the result of CSF studies.

In ICU, continuous EEG monitoring showed active epileptogenic foci over bilateral temporo-occipital regions, more on right side. We have added multiple antiepileptic medications, including phenytoin, midazolam, propofol, and oral levetiracetam. However, refractory clinical and EEG epileptic activity persisted and multiple organ failure developed in such high dose antiepileptic agents. The patient passed away four days after status epilepticus. The CSF specimen sent to center for disease control for real time PCR showed bocavirus.

Conclusion Bocavirus, a DNA virus, is a new respiratory tract infectious antigen, discovered in 2005. To our knowledge, this is the first case report about bocavirus related aseptic encephalitis inducing status epilepticus in young male.

152

急性腦幹中風為 HIV 陽性者罹患神經性梅毒的起始表徵

陳明華^{1,2} 李俊泰² 徐昌鴻² 宋岳峰^{2*}

¹國軍桃園總醫院 ²國防醫學院三軍總醫院神經科部

Acute brainstem infarction as the initial presentation of neurosyphilis in a HIV-positive patient

Ming-hua Chen^{1,2}, Jiunn-Tay Lee², Chang-Hung Hsu², Yueh-Feng Sung^{2*}

¹Department of neurology, Taoyuan Armed Forces General Hospital,

²Departments of Neurology, Tri-Service General Hospital, National Defense Medical Center

Background A worldwide resurgence of neurosyphilis has occurred since the advent of the HIV epidemic. Comparing with typical course of syphilis, patients with concurrent HIV-infection may show a more rapid progression of neurosyphilis.

Case Report A 22-year-old man, having a history of hypertension with poor medical compliance for one year, presented with numbness on left side of face and body for three days. He had a history of edema in the lower legs and skin rashes on the palms and soles one month before the event, with spontaneous remission. Headache without neck stiffness and intermittent fever were noticed for one week prior to the admission. He denied having sexually transmitted diseases. The neurological examinations showed paresthesia on left side of face and body. Some faded rashes on the soles were noticed. The brain CT showed no hemorrhage. The brain MRI revealed acute ischemic infarction with water diffusion restriction over right pons. Studies for young stroke showed positive RPR (1:32), positive TPPA (>1:1280), and positive anti-HIV antibody and western blot. Cerebrospinal fluid analysis revealed lymphocytic pleocytosis, increased protein content and positive VDRL test (1:1). Neurosyphilis and HIV infection were diagnosed. The patient's CD4 count was 598 and HIV 1 RNA viral load was 51300 copies/ml. The neurological

deficits improved gradually after a two-week therapy of intravenous penicillin.

Conclusion High variety of clinical manifestations in patients with neurosyphilis and HIV co-infection should be delivered. We highlight the importance of considering the diagnosis among the young patients presenting with atypical clinical course and symptoms of stroke.

153

HIV 陰性病人感染隱球菌腦膜腦炎引起顫抖之不自主運動

陳致霖 莊介森
彰化基督教醫院 神經醫學部

Tremor associated with cryptococcal meningoencephalitis in an HIV seronegative patient: a case report

Chih-Lin Chen, Chieh-Sen Chuang
Neurological Institute, Changhua-Christian Hospital

Background Common clinical presentations of cryptococcal meningoencephalitis in HIV seronegative patients are variable. Movement disorders were infrequently observed. Several cases of hemichorea-hemiballism in AIDS patients had been reported, but tremor was rarely observed.

Case Report A 67-year-old woman was admitted because of insidious onset of bilateral hands tremor for 3 weeks prior to admission. Before admission, she had sore throat, productive cough, fever on-and-off and

poor appetite for about 6 weeks. In addition, insidious onset of bilateral hands tremor and unsteady gait were noticed. She denied weakness or numbness of bilateral limbs. The condition persisted despite taking some drugs from clinics. There was no history of exposure to chicken or pigeon. Neurologic examination showed postural and action tremor of bilateral hands, increased muscle tone in right upper limb, mild right hemiparesis, and mild unsteadiness. Laboratory data revealed elevated ESR (42 mm/hr). Thyroid hormones were within normal limits. Brain MRI demonstrated hyperintensities over the right internal capsule, bilateral external capsules, basal ganglia and bilateral deep cortical white matter on T2WI and FLAIR sequence without abnormal signal on T1WI, DWI, ADC or SWI sequence. CSF analysis showed pleocytosis, elevated protein and low glucose level, with positive finding for Indian ink stain and positive Cryptococcus antigen. Cryptococcal meningoencephalitis was highly suspected. Symptoms improved after administration of Amphotericin B and Flucytosine.

Conclusion The clinical course, laboratory studies, brain MRI, and clinical improvement after treatment establish the relation between tremor and cryptococcal infection in this case. The patient demonstrated the infrequent manifestation of tremor caused by

involvement of basal ganglion by cryptococcal infection.

154

慢性多處腦膜炎之切片診斷：中樞神經結核一案例報告

黃立楷 李薰華 胡朝榮

台北醫學大學-行政院衛生署雙和醫院神經科

Biopsy diagnosis in chronic multifocal leptomeningitis: a case report of central nervous system tuberculosis

Li-Kai Huang M.D., Hsun-Hua Lee M.D.,

Chaur-Jong Hu M.D.

Department of Neurology, Shuang Ho Hospital,

Taipei Medical University,

New Taipei City, Taiwan

Background Central nervous system tuberculosis (TB) is the most severe form of extrapulmonary TB that even current treatment does not prevent death and disability in half of the cases. Rapid diagnosis and initiation of effective antituberculous therapy are fundamental to a better outcome.

Case Report A 69-year-old man presented initially of episodic right arm numbness for 9 months. The sensory symptoms were responsive to treatment with Valproic acid 500mg HS. The brain magnetic resonance imaging (MRI) post Gd-DTPA enhancement showed multiple contrast-enhanced leptomeningeal lesions over the left frontal-parietal region. Digital subtraction angiography revealed no dural AVF but focal luminal narrowing at one of left superficial cortical veins. Progressively,

註解 [7]:

Your User Name 13/1/21 下

午 1:58

哪些?

he became demented with difficulty in walking. Three cerebrospinal fluid (CSF) studies revealed elevated protein and mild pleocytosis with dominant lymphocytes. All the TB polymerase chain reaction (TB-PCR) and acid-fast stain (AFB) tests showed negative results. Finally, leptomenigeal TB infection was proven by tissue culture from biopsy. The clinical condition improved gradually after anti-TB therapy.

Conclusion Our patient was diagnosed as definite TB meningitis by focal meningeal biopsy with positive TB culture. The significant improvement after anti-TB medication supports that the original problems have been treated. However, our attempt to confirm or exclude the diagnosis were frustrating, for negative CSF AFB, TB-PCR and TB culture for a few times until the more invasive operation was performed. This case raises the relevant implication that meningeal biopsy might be necessary for the chronic meningitis patients without definite diagnosis by non-invasive examinations.

155

神經性梅毒之特殊影像學病灶：一病例報告

馮博裕 章寶倫

林口長庚紀念醫院 神經內科

Juxtacortical lesions in Neurosyphilis :

A Case Report

Po-Yu Fong, Bao-Luen Chang

Department of Neurology, Chang Gung Memorial Hospital, Lin-Kou Medical Center

Background Syphilitic infection of the central nervous system mostly results in chronic meningeal inflammatory process and parenchymal involvement. The common neuroimaging findings of neurosyphilis include diffuse inflammation of pia and arachnoid, as well as ischemic lesions, typically lacunar or middle cerebral artery territory involved, in meningovascular syphilis; intracerebral gummata; mesial temporal lobe or disseminated frontal high-signal lesions on T2-weighted images; and ventriculomegaly.

Case report A 63-year-old, married man has HTN and Af with MVR under regular treatment. He had neuralgia over bilateral lower extremities and sensory ataxia since 2008, the neurological examinations revealed diffuse hyporeflexia. The NCV/EMG studies were unremarkable but somatosensory evoked potential study showed spinal cord lesion between cervicolumbar region. However, insidious onset of cognitive decline with incoherent speech and wording difficulty developed since January 2011. He also had two episodes of conscious loss in January and March 2011 and seizure was diagnosed. In November 2011, subacute onset of mentality change, disorientation and mild delirium were noticed. The CSF study showed mild lymphocytic pleocytosis with mild elevation of total protein and normal glucose level. The

RPR was 1:16 in CSF and 1:128 in serum. The serological TPHA was >1:1280 and HIV screening test was negative. Brain magnetic resonance imaging showed high signal lesions in juxtacortical areas over bilateral insular, frontal, temporal and parietal regions on FLAIR and T2-weighted images without T1-weighted gadolinium enhancement. Therefore, neurosyphilis was diagnosed then he received intravenous penicillin G treatment. Under one year follow up, his symptoms and signs had gradually improved and a follow-up brain MRI revealed totally improvement of the juxtacortical lesions.

Conclusion The juxtacortical lesions in neurosyphilis were rarely reported and it can mimic a demyelinating lesion (such as multiple sclerosis), Creutzfeldt-Jakob disease, HIV encephalitis, Binswanger disease, cerebral autosomal dominant arteriopathy with subcortical infarcts and leukoencephalopathy (CADASIL), and progressive multifocal leukoencephalopathy in both clinical manifestations and neuroradiologic studies .

156

以腦幹梗塞為早期臨床表現之細菌性腦膜炎

鄭秀靜 陳俊鴻 林瑞泰 賴秋蓮 陳建甫
高雄醫學大學附設中和紀念醫院 神經科

Brainstem Infarction as An Early Manifestation of Bacterial Meningitis

Hsiu-Ching Yin, Chun-Hung Chen, Ruey-Tay Lin,
Chiou-Lian Lai, Chien-Fu Chen

Department of Neurology, Kaohsiung Medical University Hospital, Kaohsiung, Taiwan

Background Vasculitis and infarcts are well-established sequelae of bacterial meningitis. However, early large-vessel involvement is rare, particularly within the brainstem. We present one case of brainstem infarction associated with bacterial meningitis.

Case Report This 31-year-old male had viral meningitis 3 years ago. The patient had been to Thailand about one week before admission. He suffered from headache, dizziness and binocular diplopia at first. Then, progressive double vision, lethargy, right side numbness(both face, trunk and face), slurred speech developed while he woke up in the morning on the next day. Brain CT showed old infarction over left basal ganglion when he arrived the emergency room(ER). Neurological examination revealed bilateral abducen nerve palsy, right trigeminal, facial nerve lesions, right hemiparesis and paraesthesia. Besides, fever was noted (39.1C) on arrival to ER. Cerebrospinal fluid (CSF) analysis revealed glucose 59 mg/dl (blood 143 mg/dl), protein 210 mg/dl, total nucleated cells of 740 (98% neutrophils, 2% monocytes). The patient was treated initially with intravenous ceftriaxone, vancomycin, and intravenous dexamethasone before culture and sensitivity results. A

magnetic resonance imaging (MRI) scan of the head 2 days after admission revealed subacute infarction with hemorrhagic transformation in the pons. Young stroke survey showed mild elevating Clotting factor VIII and ESR. There were no positive results including viral, aerobic or anaerobic bacterial culture, fungal, TB-PCR tests of CSF analysis.

Conclusion Vasculopathy of the basilar artery and its perforating arteries may lead to brainstem ischemia. It is important to aware that clinical signs of ischemia may be an early clinical manifestation of meningitis.

157

以可逆性似急性腦中風損傷之胼胝體病灶為表現的病毒性腦炎:個案報告

劉翁銘 林靜嫻
台大醫院神經部

A Reversible Stroke-Like Splenial Lesion in Viral Encephalopathy: Case Report

Weng-Ming Liu, Chin-Hsien Lin
Department of Neurology, National Taiwan University Hospital

Background An ovoid reversible lesion in the central portion of the splenium of the corpus callosum (SCC) without any accompanying lesions in MRI was uncommon but had been reported in mild encephalopathy/encephalitis patients.

Case Report

A 32 years old healthy man suffered from intermittent fever up to 39°C

accompanied with severe headache, vomiting and diarrhea 2 days before admission. CSF study showed lymphocytic leukocytosis (9), elevated protein (120mg/dL) and normal sugar (42mg/dL). PCR for HSV-1/2, TB, and influenza antigen were negative. He was diagnosed as viral meningoencephalitis and receiving Acyclovir. Decreased verbal output, myoclonus and generalized tremor were noted on 3 days after admission. Follow-up CSF study showed more elevated total protein (367mg/dL) and lymphocytic leukocytosis (Lymphocyte/Neutrophil : 40/3) but both negative in HSV-PCR and TB-PCR. Head magnetic resonance image (MRI) showed one 2.4cm focal area of limited diffusion coefficients and focal swelling near the splenium of the corpus callosum, with hyperintensity in T2-weighted imaging (T2WI) and diffusion weighted image (DWI), hypointensity in apparent diffusion coefficient (ADC) and faint hypointensity on T1-weighted imaging (T1WI), mimicking acute infarction. MRI with contrast showed obvious leptomeningeal enhancement. His consciousness remained drowsy and had agitation and occasional myoclonus. Intravenous Acyclovir and anti-tuberculosis agent (Rifampicin, Isoniazid, Pyrazinamide, Ethambutol) were used. His conscious gradually recovered without any neurologic sequelae. Follow-up CSF study 2

weeks later showed decreased total protein (162.5mg/dL) but still lymphocytic leukocytosis (Lymphocyte/Neutrophil : 99/0). Follow-up MRI 2 months later was normal without residual lesions.

Conclusion Our case confirmed with previous findings that a reversible stroke-like splenial lesion could be seen in virus related encephalopathy and regarded as a good prognosis marker. Transient intramyelinic edema or inflammatory infiltrate is the possible mechanism and further studies enrolling more related cases will be needed to confirm our finding.

158

以中風症狀表現之庫賈氏病:個案報告

鄭美雲 江星逸
林口長庚紀念醫院 神經內科

Sporadic Creutzfeldt-Jakob disease mimics a left hemisphere stroke: A case report

Mei-Yun Cheng, Hsing-I Chiang
Department of Neurology, Chang Gung Memorial Hospital, Lin-Kou Medical Center

Background Unilateral onset pyramidal signs and language dysfunction mimicking left hemisphere ischemic stroke was found in a patient with sporadic Creutzfeldt-Jakob disease (sCJD).

Case Report A 58-year-old man presented with acute onset right hemiparesis, slurred speech, and anomia. Initial brain CT showed hypodense

lesions over left hemisphere with perifocal edema and compression of left lateral ventricle. Left MCA territory infarction was the first impression according to clinical features and brain imaging. Rapid progression of behavioral changes, dementia, grimacing, myoclonia, seizures, and mutism were noticed within one month. Then, the brain MRI revealed hyperintensity over left caudate in DWI and hypointensity in ADC, and asymmetric frontal cortical lesions with left side dominance. Repeated electroencephalograms showed periodic sharp wave in left frontal region with inter-spike interval of 1 second. The cerebrospinal fluid protein 14-3-3 analysis was positive.

Conclusion The unilateral onset sCJD is not common and easily misdiagnosed as stroke initially. Rapid progressive dementia and appropriate tests, including brain MRI and electroencephalogram, may improve the diagnosis of sCJD.

159

散發性庫賈氏症病人腦波及腦部核磁共振影像之不對稱表現

謝孟倉¹ 黃涵薇¹
國立成功大學附設醫院 神經部¹

The asymmetric presentation of EEG and brain MRI in sporadic

Creutzfeldt-Jakob disease patients
Meng-Tsang Hsieh¹, Han-Wei Huang¹

Background Creutzfeldt-Jakob disease (CJD) is a rare disease with grave prognosis. Death usually occurs within one year of symptom onset. CJD used to be described as diffuse neurodegenerative disease. However, lateralization findings in magnetic resonance imaging (MRI) and electroencephalography (EEG) were reported in some patients fulfill the WHO criteria of sporadic CJD.

Objective: To ascertain the presentation of EEG and brain MRI in patients with sporadic Creutzfeldt-Jakob disease (sCJD).

Method The subjects were those who were diagnosed as probable or possible sCJD in National Cheng-Kung University Hospital during the period from 2006 to 2012. We reviewed the chart record, brain MRI, and the EEG reports to evaluate correlations among them.

Result In this retrospective research, thirteen probable or possible sCJD patients were identified. There were eight patients had bilateral bright signal intensity on MRI of diffusion-weighted imaging (DWI) of the cortex and/or basal ganglia. (Four of them were more predominant in one side). The other five patients had unilateral signal changes in MRI DWI series. The EEG showed

cortical dysfunction in all thirteen patients, seven of them were more severe in either side. There were seven patients has lateralized positive sharp wave complex (PSWC) in the initial EEG study, and three of the other six patients had PSWC in EEG eventually.

Conclusion This result indicates that characteristic abnormalities on MRI and EEG findings with asymmetric distribution are not uncommon presentation, and may be helpful for early diagnosis of sCJD.

160

Ramsay Hunt Syndrome 合併三叉神經及頸部病灶：一案例報告

李薰華 黃立楷 胡朝榮 陳致中
行政院衛生署雙和醫院神經內科

Ramsay Hunt Syndrome with Ipsilateral Cranial Nerve V and Upper Cervical Nerves Involvement: A Case Report

Hsun-Hua Lee M.D, Li-Kai Huang M.D,
Chaur-Jong Hu M.D, Chih-Chung Chen M.D
Department of Neurology, Shuang-Ho Hospital,
Taipei Medical University, New Taipei City,
Taiwan

Background Ramsay Hunt syndrome (RHS) refers to the association of unilateral peripheral facial nerve palsy and herpes zoster infection of the ear (herpes zoster oticus), with or without hearing loss. The majority of cases have manifestations limited to the involvement of cranial nerve (CN) VII and VIII. Atypical presentations of RHS with other CN or cervical nerve involvement are uncommon. Here we

report an unusual case of RHS with concurrent ipsilateral CN V, C2, and C3 nerves involvement.

Case Report A 69-year-old immunocompetent woman was hospitalized to neurologic ward due to acute left facial paralysis, painful skin eruption in left earlobe, severe dizziness and hearing impairment for 4 days. One month before hospitalization, she began to have the symptoms of intermittent fever up to 39°C, sore throat, general weakness, changes of taste and persistent tingling pain in left low face and neck. Ten days before hospitalization, she noticed painful skin redness in left lower face and neck with grouped vesicles around left upper and lower lips. On admission, we noticed vesicular skin eruptions in left earlobe, maxillary and mandibular branches of left trigeminal nerve and left C2 and C3 dermatomes. Neurologic examinations revealed peripheral type facial palsy (FNGS 2.0 Grade V) and sensorineuronal hearing loss of left side. Brain and cervical spine MRI findings are insignificant. Cerebrospinal fluid analysis showed normal cell count, sugar and protein. Despite intravenous acyclovir and steroid therapy, the recovery of facial paralysis and hearing loss is slow.

Conclusion Multiple cranial and cervical spinal nerves involvements are uncommon in Ramsay Hunt syndrome. Reported cranial nerve involvement

include CN 5,7,8,9,10,11 and 12 and cervical spinal nerve in C2,3 and 4. Possible explanations of varicella-zoster virus reactivation from multiple ganglia are anatomical proximity, selective vulnerability of blood vessels and transaxonal spread. Such extensive involvements can occur in both immunocompetent and immunocompromised subjects and carry worse prognosis.

神經免疫學

161

多發性硬化症與視神經脊髓炎細胞 激素分析的差異

王凱震 李照琳 陳紹源 楊智雯 陳錫洲
蔡清標
振興醫院 神經內科

Distinct Serum Cytokine Profiles in Neuromyelitis Optica and Multiple Sclerosis

Kai Chen, Wang, Chao-Lin, Lee, Shao-Yuan,
Chen, Chih-Wen, Yang, Shyi-Jou, Chen, and
Ching-Piao, Tsai
Department of Neurology, Cheng Hsin General
Hospital, Taipei, Taiwan

Objective Multiple sclerosis (MS) is the most common prototypic inflammatory demyelinating disease. Neuromyelitis optica (NMO) is another inflammatory demyelinating disease of the central nervous system that exhibits clinical symptoms mainly associated with optic neuritis and myelopathy. The inflammatory reaction in MS is associated with an up-regulation of a variety of Th1 or Th17-mediated cytokines. However, NMO and MS are intertwined both clinically and

pathologically, which complicates their diagnosis and treatment. The aim of this study was to evaluate the differences in serum cytokine levels in NMO and MS patients.

Methods We collected peripheral serum from patients with these central nervous system demyelinating diseases for the study. A cytometric bead array was used to assess the cytokine levels using flow cytometry.

Results We found more inflammatory (IL-2, and IFN- γ), and anti-inflammatory (IL-4, and IL-10) cytokines in NMO than in MS. The differences in the optimal cutoff points of serum cytokines, including IL-2 ≥ 5 pg/ml, can differentiate NMO from MS.

Conclusion NMO patients had an increased Th1-mediated inflammatory response, but similar Th17-mediated inflammation changes compared to MS patients. Serum cytokine studies can differentiate NMO cases from MS.

162

原發性中樞神經系統血管炎：病例報告

王寧 李靜娥

台北醫學大學 市立萬芳醫院 神經內科

Primary Central Nervous System Vasculitis : A Case Report

Ning Wang, Jing-Er Lee

Department of Neurology, Taipei Municipal Wanfang Hospital, Taipei Medical University

Background Primary central nervous vasculitis (PCNSV) is a rare form of vasculitis limited to brain and spinal cord.

We report a 35-year-old patient with stroke symptom caused by PCNSV.

Case Report A 35-year-old man without prior history of systemic disease presented to our neurologic clinic because of acute onset of isolated left hemiparesis lasting for 4 hours, and recalled that there was another episode with the same pattern 5 days ago before admission. He denied smoking history, fever or recent trauma history. However, another two episodes of recurrent left hemiparesis developed in the following months. Neurological examination was normal except mild left hemiparesis. General laboratory workup was unremarkable. Series of work-up for young stroke was conducted including anti-phospholipid antibody, lupus anticoagulant, anti-nuclear antibodies, anti-ENA antibodies, and antineutrophil cytoplasmic antibodies, and no definite abnormality was noted. The levels of homocysteine and ESR were normal. No evidence of intracardiac thrombus or shunt was found after trans-esophageal cardiac echography. CSF studies showed no signs of infection or cytoalbumin disassociation. EEG study showed no definite evidence of cortical dysfunction. The brain MRI on August 30, 2012 revealed one infarction at right internal capsule in DWI (figure 1a), and in the third episode, showed new lesions at right internal capsule, globus pallidus and left corpus callosum (figure 1b and

1d). MR angiogram on September 16, 2012 showed no definite vascular lesion. Cerebral angiography revealed abnormal arterial appearances including alternating stenosis with dilatation of multiple intracranial arteries (figure 2); CNS vasculitis was highly suspected(1,2). Steroid pulse therapy (Methylprednisolone 500 mg daily) was administered for five days and followed by prednisolone 60mg daily and there was gradual improvement in left hemiparesis. No neurological deficit developed thereafter. We tapered the amount of prednisolone with 10 mg per week for 2 weeks, and 5 mg per week for the rest.

Conclusion It is important to intensively search for the possible etiologies in young stroke, especially with relapses of sign and symptom despite of adequate and proper treatment. PCNSV, although rare, should be suspected in the context of multiple areas of infarction in different vascular territories and of different ages revealed by brain MRI. Once clinically suspected, cerebral angiography is a key diagnostic modality when biopsy is not undertaken. We presented a case of PCNSV whose neurological deficit improved after steroid treatment.

163

以陣發性嚴重疼痛為起始表現之
Guillain-Barre 症候群：病例報告
吳孟玲 葉旭霖 連立明 葉建宏 邱浩彰
新光吳火獅紀念醫院 神經科

Intermittent Severe Pain as Initial Presentation of Guillain-Barre syndrome- A Case Report

Meng-ling Wu, Hsu-Ling Yeh, Li-Ming Lien,
Chien-hung Yeh, Hou-Chang Chiu
Departments of Neurology, Shin Kong Wu
Ho-Su Memorial Hospital, Taipei

Background The typical initial presentation of Guillain-Barre syndrome (GBS) is ascending numbness, proximal weakness, and areflexia. We reported a young man who visited emergency department(ED) repeatedly for non-specific pain syndrome finally diagnosed as GBS that need ventilation support.

Case report A 44-year-old man, who had chronic headache since adolescent, was in his usual healthy status until 4 days before admission when bilateral temporal swelling pain attacked. The character of the pain was just the same as he used to have. In the following days, he experienced malaise and general soreness and pain. The pain went on and off, aching in nature, visual analogue scale 10/10, migrating among limbs joints and muscles, and he also had chest, abdomen, and back discomfort. He visited ED for 3 times because of the intractable pain. All routine blood tests including electrolyte, muscle enzyme, inflammatory profile, and autoimmune profile were normal. No definite lesion could be found through contrast enhanced computed tomography from chest to abdomen. We suspected viral

infection, hyperventilation syndrome, conversion disorder, unknown autoimmune disease, Dengue fever, and aortic dissection but there was no evidence to support any of these diagnoses. The pain responded poorly to ketorolac and morphine. He had akathisia with anxiety. On the 4th day after symptoms onset, facial asymmetry developed. Neurological examination showed left peripheral type facial palsy and hyporeflexia in knees and ankles. He also reported distal limbs paresthesia but we couldn't reveal hypoesthesia or decrease in sense of vibration. Follow up blood test showed WBC 10300 / μ L and CK 821 U/L. GBS was suspected. CSF data and nerve conduction examination showed typical change of acute inflammatory demyelinating polyradiculoneuropathy. He was admitted for pain control. Proximal muscle weakness developed on the 5th day and we started plasmapheresis. However, he became dyspnic on the 6th day. We intubated him on the 8th day and the nadir of weakness (MRC 3 in proximal and 0 in distal limbs) was on the 10th day. After 6 sessions of plasmapheresis, his muscle power improved after the 16th day but he still suffered from neuropathic pain in distal limbs when he was discharge on the 75th day.

Discussion Ropper et al (1984) first reported that 55% of GBS patient had characteristic pain early in the illness. In these patients, serum CK elevated in 77%

compared with 12.5% of whom without the characteristic pain. The mechanism of the pain is multifactorial which is possibly related to inflammation of nerve roots, irritation of the nervi nervorum, spontaneous or abnormal activity from large myelinated sensory afferents, affected small nerve fibers, mechanical factors, and immobilization.

Conclusion Pain is not rare in GBS. We should take GBS into consideration in approaching patient with clinical and laboratory unexplainable pain.

164

Anti-Yo 抗體合併附腫瘤性小腦變性： 案例報告

李卓育 陳律安
馬偕紀念醫院 神經內科

Anti-Yo Associated Paraneoplastic Cerebellar Degeneration : A Case Report

Chuo-Yu Lee, Lu-An Chen
Department of Neurology, Mackay Memorial
Hospital

Background Paraneoplastic cerebellar degeneration is a rare disorder caused by the immune-mediated remote effects of different types of malignancy. Subacute progressive cerebellar symptoms usually precede the diagnosis of the cancer.

Case Report A 44-year-old female was admitted to neurology department with a progressive ataxic gait disorder.

She had been well until two months earlier, when she noticed slurred speech. Two weeks later, she suffered from light-headedness, unsteady gait, and bilateral hands clumsiness. She tended to reach toward the wall for support as she walked. These symptoms progressed, and she gradually could not sit, stand or walk without assistance. There was no history of cognitive decline, headache, fever, nausea, vomiting, diplopia, paraesthesia, use of tobacco, alcohol, or illicit drugs. There was also no family history of movement or gait disorders. On neurological examination, she was alert, oriented, and had normal cognitive function. The extraocular movements were full, and no nystagmus was noted. Severe dysarthri was found. The remaining cranial nerves were intact. Sensory examinations were normal. Reflexes were 3+ throughout. Dysmetria and dysdiadochokinesia were demonstrated in bilateral arms, more severe on the left side. She also had wide base gait, truncal ataxia and bilateral dysmetria while performing the heel-knee-shin test. Magnetic resonance imagings (MRI) of the brain and cervical were normal. Cerebrospinal fluid (CSF) studies showed normal cell count but mild elevated protein (64mg/dL). Based on the presentation of subacute progressive cerebellar dysfunction, investigations for paraneoplastic syndrome were undertaken. Elevated serum tumor markers were found, including cancer

antigen(CA) 153=132.6 U/ml, and CA 125=2126.4 U/ml (normal range <30U/ml, <35 U/ml, respectively). Whole abdomen computed tomography (CT) scan revealed a large cystic tumor in pelvic cavity, several peritoneal masses, and three nodules over right subphrenic area. Two weeks after admission, she underwent optimal debulking operation with abdominal total hysterectomy, bilateral salpingo-oophorectomy, omentectomy, partial hepatectomy, diaphragm tumor excision, and colon tumor excision. Final pathologic diagnosis was ovarian serous carcinoma, International Federation of Gynecology and Obstetrics (FIGO) stage IIIC, with metastasis over peritoneal, omentum, liver surface, diaphragm, and hepatic flexure colon. Serum anti-Yo antibodies test by Western blotting was positive in this patient. Definite paraneoplastic cerebellar degeneration (PCD) was diagnosed according to the criteria of Graus et al. We arranged a course of plasmapheresis consisting of five exchanges over six days, and chemotherapy with carboplatin and paclitaxel. However, she did not make any significant improvement.

Conclusion Previous literature showed most patients had limited oncologic disease at the time of onset of paraneoplastic syndrome. It has been postulated that the antitumor immune response may contribute to the

small size of the tumor. However, we presented a case of advanced stage ovarian cancer with anti-Yo associated PCD and poor response to operation, chemotherapy, and plasmapheresis.

165

成人型史迪爾氏症併發腦幹腦炎：一病例報告

邱劭文 張宏旭

林口長庚紀念醫院 神經內科

Brainstem Encephalitis in Adult Onset Still's Disease: Report of A Case

Shao-Wen Chiu, Hong-Shiu Chang

Department of Neurology, Chang Gung Memorial Hospital, Lin-Kou Medical Center

Objectives We report a case of adult onset Still's disease with brainstem encephalitis.

Background Adult onset Still's disease (AOSD) is a systemic inflammatory disorder of unknown etiology, characterized with spiking fevers, evanescent rash, arthralgia, and multi-organ involvement. Neurological complications have seldom been reported. We described a 29-year-old Philippine woman of AOSD associated with brain stem encephalitis.

Case report A 29-year-old Philippine woman was admitted to our hospital due to progressive bilateral ptosis and diplopia since 2012/07/06. She initially experienced acute onset of vertigo with unsteady gait on 2012/07/01. Later, high fever up to 39°C, cough, sore throat and headache over bilateral frontal area were

noted. Papular erythematous skin rashes appeared progressively over bilateral proximal limbs, abdomen, and inguinal area. She also had arthralgia at bilateral elbows, wrists and knees.

These were followed by weakness of four limbs. After hospitalization, intermittent spiking fever persisted. On neurological examination, she had bilateral ophthalmoplegia with downbeat nystagmus. Muscle weakness predominantly affected the proximal parts of the limbs. There were also cerebellar dysfunctions including dysmetria and ataxic gait.

Laboratory tests revealed leukocytosis (WBC 19000/uL), anemia (Hb 10.1g/dL), elevated ESR (61 mm/hr), high Ferritin level (5284ng/mL), normal ANA (1:80) and RF(<10.10IU/mL). A CSF study showed normal protein concentration without pleocytosis. Brain MRI revealed a midline lesion at the midbrain mainly involving the periaqueduct area. The lesion was hypointense on T1WI, hyperintense on T2WI/FLAIR and faintly hyperintense on DWI. There was no contrast enhancement. The findings were compatible with brainstem encephalitis. AOSD was diagnosed according to Yamaguchi's criteria.

The patient was treated with pulse therapy with methylprednisolone 1 gm per day and her fever, diplopia, arthralgia and skin rashes gradually subsided.

Conclusion Our case demonstrates that AOSD should be included as one of the etiologies for unexplained brain stem encephalitis

166

案例報告：神經貝賽特氏病症—影像及病理發現

唐奇峯 蔡銘駿

中國醫藥大學附設醫院神經部

Diffuse MRI: Apparent Diffusion Coefficient and Pathologic Findings in a Case of Neuro-Behçet's Disease

Chi-Feng Tang, Ming-Jun Tsai

Department of Neurology, China Medical University Hospital, Taichung, Taiwan

Background Behçet's disease (BD) is known with inflammatory perivasculitis which may involve multiple organs, and rarely invade central nervous system. Here, we reported a case with neuro-Behçet's disease with acute onset of right cerebellar symptoms.

Case Report A 45-year-old man with a history of Behçet's disease (BD) came to our emergency department because of deteriorated ataxia for one week. BD was diagnosed one year ago with the initial presentation of repeated oral, genital ulcers and skin rashes. Uvietis with left eye total blindness were noted half a year ago. He regularly took immune modulation medication (cyclosporine 200mg, cyclophosphamide 50mg, levamisole 50mg, prednisolone 7.5mg, colchicine 1mg per day) for disease control.

One week prior to admission, he suffered from ataxia with right side deviation.

Initially there was no focal weakness, but progressive right side clumsiness was noted within 2-3 days. On neurologic examination, direct funduscopy showed only mild pale on optic disc of left eye, and dysmetria on right extremities. On the magnetic resonance imaging (MRI) study, T2-weighted images and fluid attenuated inversion recovery (FLAIR) images showed multiple hyperintensity ovoid spots in bilateral periventricular white matter of cerebrum and cerebellum without obvious enhancement, and apparent diffusion coefficient (ADC) showed round lesions with increased intensity on right cerebellum. Brain biopsy from the lesion on left frontal lobe was performed and the histologic examination found mild gliosis with abundant foamy histiocytes and no accumulation of inflammatory cells within vessels on H-E stain, favored demyelinating diseases. Pulse therapy with methylprednisolone 1000mg QD for five days was given and immune modulation therapy with Cyclosporin 100mg 1# BID; Levamisole 50mg 1#QD; Prednisolone 5mg 8# QD were maintained. The neurological deficits got gradually improved. He followed up at our OPD for two months, no further deterioration of neurologic deficits were noted. Then he got lost of follow up.

Discussion We reported a case of neuro-BD with initial manifestation as acute onset of right cerebellar symptoms. The diagnosis of BD is based on clinical manifestation. In our case, brain MRI detected multiple hyperintensity ovoid lesions on bilateral cerebrum and cerebellum on FLAIR and T2-weighted image, whereas, only one lesion on right cerebellum showed increased intensity on ADC. This lesion detected on ADC was compatible with clinical manifestations. Increased intensity in ADC suggested vasogenic edema in this brain lesion. Vasogenic edema in this brain lesion implied acute change of permeability of involved vessels which may be secondary to perivasculitis, an important pathologic marker of BD. In summary, our case showed clinical manifestation of BD with brain involvement confirmed by clinical symptoms and brain image findings, so neuro-BD was impressed. According to the McDonald Criteria 2010, at least one episode of attack and multiple cerebral and cerebellar ovoid lesions which disseminated in at least two different times in this case suggested probable MS. However, the location of biopsy was not active lesion in this case, and the differential diagnosis of neuro-BD from MS in this case still needed more clinical data including longer follow-up period. We suggested ADC sequence may contribute to detection of acute brain lesion with vasogenic edema in neuro-BD. And there still have

diagnostic dilemma in differential diagnosis of neuro-BD from MS by McDonald Criteria.

167

抗磷脂抗體與小腦失調症：臨床分析和文獻回顧

陳昶宏¹ 呂鎮中² 邱文燦³ 陳忠仁³

陳偉熹¹

高雄長庚紀念醫院 神經內科¹ 神經放射科²
風濕免疫科³

Antiphospholipid Antibody and Cerebellar Ataxia: A Clinical Analysis and Literature Review

Chang-Hung Chen¹, Chun-Chung Lui²,

Wen-Chang Chui³, Chung-Jen Chen³,

Wei-Hsi Chen¹

Departments of Neurology¹, Neuroradiology²,
and Rheumatology³, Kaohsiung Chang Gung
Memorial Hospital, and College of Medicine,
Chang Gung University, Kaohsiung, Taiwan

Objectives Antiphospholipid antibodies (APAbs) have been found to bind with and modulate signaling in cerebellar neurons in in vitro studies. We review our database and patients in literature to clarify the relation between increased APAbs and cerebellar ataxia.

Methods A total of 13 patients, collected from the Kaohsiung Chang Gung Memorial Hospital and Kaohsiung Medical University Hospital, who presented with cerebellar ataxia with increased blood APAbs, and three 3 APAb-associated cerebellar ataxia patients in literature, were reviewed. Ataxia was classified into acute, subacute and chronic based on the clinical course.

Results Acute ataxia was present in 3 patients and was exclusively due to cerebellar stroke. In the 4 subacute ataxia patients, there was no significant responsible structural change in brain. Chronic ataxia was present in 6 patients who exhibited similar findings, including symmetrically confluent and non-confluent lesions at bilateral hemispheres, periventricular lucency, central atrophy, and temporal atrophy, in variable severity. Cerebellum was spared. The preponderant APAb for acute, subacute, and chronic ataxia was lupus anticoagulant, anti-beta2-glycoprotein I antibody, and anticardiolipin antibody, respectively. Systemic cancer was found in one out of four subacute ataxia patients and in four out of six chronic ataxia patients. Removal of the cancer corrected the ataxia and increased APAb in two patients. Plasmapheresis successfully abolished ataxia in two subacute ataxia patients whereas immunosuppressive treatment reversed ataxia in three previously reported cases in literature.

Conclusion Cerebellar ataxia is not an exceptional condition associated with APAbs. A specific APAb subtype mechanism mediates ataxia through vascular and neuronal damage, with either structural destructive impairment or functional neurotoxicity. APAbs should be examined in cerebellar ataxia patients without determined cause. Plasmapheresis is a reasonable and

effective treatment for APAb-associated cerebellar ataxia.

168

高 E 型免疫球蛋白症相關之慢性脫髓鞘多發性神經炎：案例報告

郭書帆 陳律安
馬偕紀念醫院 神經內科

Chronic Inflammatory Demyelinating Polyradiculoneuropathy Associated with HyperIgEaemia: A Case Report

Shu-Fan Kuo, Lu-An Chen
Department of Neurology, Mackay Memorial Hospital

Background Chronic inflammatory demyelinating polyradiculoneuropathy (CIDP) is thought to be a heterogeneous autoimmune disease involving either cellular or humoral immune reaction. CIDP has several variant in clinical presentation and it also associated with many systemic diseases. Gammopathy, mostly IgM and IgG, is one of the common underlying diseases associated with CIDP. In rare condition, hyperIgEaemia has also been associated with CIDP.

Case Report A 74 -year-old male had past history of hyperlipidemia and hypertension. He suffered from acute distal limbs numbness, double vision and ataxic gait. Nerve conduction study (NCS) revealed demyelinating change and cerebrospinal fluid (CSF) analysis showed albuminocytologic dissociation. Acute inflammatory

demyelinating polyradiculoneuropathy (AIDP) with Miller-Fisher variant was impressed. Both symptoms and NCS improved after 3 weeks of supportive care but numbness in glove and stocking distribution persisted. Three months later, he had another episode of acute symmetric proximal four limbs weakness and impending respiratory failure. NCS and CSF showed similar findings as previous episode. Under the impression of AIDP, he received 5 sessions of plasmapheresis and both weakness and respiratory failure recovered. Concerning about relapsing-remitting course and possibility of CIDP, serial survey of underlying diseases was done including serum protein electrophoresis. No monoclonal band presented but IgE was as significantly high as 1073 IU/mL. No other autoimmune, endocrine, infectious or malignancy disease were found. 7 months after the first episode, he had another exacerbation of four limbs weakness and more prominent glove and stocking numbness. The symptoms again improved by 5 sessions of plasmapheresis. The IgE level was 1449 IU/mL, suggested the possible association between IgE titer and the clinical deterioration. Skin allergy test showed strong reaction to mite although no clinical history of allergy, parasite infection or asthma was identified. Oral prednisolone was applied for CIDP. The serial followed IgE level also decreased from 1449 to 500 IU/mL. No clinical exacerbation was noted since steroid

therapy.

Conclusions CIDP can be associated with hyperIgEaemia but the pathogenesis still remains obscure. It has been speculated that heightened IgE response contribute to the peripheral nerve inflammation through the action of mast cells.

169

以廣泛橫貫性脊髓炎為臨床症狀表現之休格蘭氏症候群：案例報告

黃勇評 陳培豪
馬偕紀念醫院 神經內科

A Longitudinally Extensive Transverse Myelitis As The Presentation Of Primary Sjögren Syndrome: A Case Report

Yung-Pin Hwang¹, Pei-Hao Chen^{1,2}

¹ Department of Neurology, Mackay Memorial Hospital

² Graduate Institute of Mechanical and Electrical Engineering, National Taipei University of Technology

Background Sjögren syndrome (SS) is a systemic autoimmune disease, usually classified as either primary or secondary. The main clinical features are xerostomia and xerophthalmia. Central nervous system involvements in primary SS are not common but include psychiatric disturbances, late-onset migrainous episodes, aseptic meningitis, meningoencephalitis, focal neurological deficits, and an acute or chronic myelopathy. We herein describe one patient who suffered from longitudinally extensive transverse myelitis (LETM) as the primary presentation of primary SS.

Case Report A 41-year-old female patient suffered from acute onset of left side face, trunk and upper limb hypesthesia with tingling sensation and pain since September 21, 2012. Accompanying symptoms included horizontal diplopia, spastic dysarthria, dysphagia and hyperreflexia. She denied previous systemic disease. Family history was contributed to her mother's rheumatic arthritis. No obvious lesion was found on her brain magnetic resonance imaging (MRI). However, Visual evoked potential (EP) showed equivocal delayed P100 response bilaterally. Somatosensory EP study showed central somatosensory conduction delay between the cauda equina to the cervical cord. MRI of the spine revealed a longitudinally extensive spinal cord lesion enhanced with gadolinium from the level of the second cervical to the fifth thoracic vertebra. Cerebrospinal fluid study demonstrated a normal white cell count of 2 cells/cmm, and an elevation of protein level of 126 mg/dL. The IgG index was normal without oligoclonal bands. She was diagnosed to have a longitudinally extensive transverse myelitis, a characteristic feature of neuromyelitis optica (NMO), but also occurring in various other autoimmune and inflammatory diseases that involve the CNS. Her NMO-IgG was negative. Further laboratory examinations showed high titers of anti-SSA antibodies. Tracing back the history, she had mild

symptoms of dry eyes and difficult swallowing during previous 3 months. Sialoscintigraphy showed mildly decreased uptake in the bilateral salivary glands and Schirmer's test was abnormal with less than 5 mm, corresponding to the criteria of primary SS. We started to treat with high-dose methylprednisolone (1000 mg) daily for 3 days and symptoms showed gradual improvement thereafter. She was able to walk without assistance after hospital discharge.

Conclusions LETM can result from a wide spectrum of different etiologies and NMO is one of the most common causes. Acute myelitis and optic neuritis are absolute diagnostic criteria of NMO. Our patient has negative NMO-IgG, providing important information to exclude NMO and to fulfill the criteria for primary SS.

170

Balo 同心圓性硬化症

楊依倩 呂明桂 蔡崇豪
中國醫藥大學附設醫院神經內科

Balo's concentric sclerosis

Yi-Chien Yang¹, Ming-Kuei Lu¹, Chon-Haw Tsai^{1,2}

¹Department of Neurology, China Medical University Hospital, Taiwan

²Graduate Institute of Neural and Cognitive Sciences, China Medical University

Background Balo's concentric sclerosis is a rare variant of multiple sclerosis. Histopathologically, it was characterized by alternating layers of myelinated and demyelinated tissue.

The current diagnostic method is based on brain MRI which demonstrates concentric bands of low- and iso-signal lamellar lesions in T1-weighted sequence. The correct diagnosis is important for both the appropriate treatment and avoiding unnecessary surgical intervention.

Case 1 A 23-year-old man presented with progressive left side numbness descending from face to lower limb within one week in November 2011. He had a history of lymphoma ten years ago and had received chemotherapy for that. Brain MRI (Fig. 1) revealed two cystic mass lesions in right parietal and frontal lobe, respectively. After brain biopsy, he was treated with intravenous dexamethasone under the impression of recurrent lymphoma. The symptoms resolved gradually during follow-up in the outpatient clinic. Eight months later, another episode of left side numbness was developed in an ascending fashion from left lower limb to the left shoulder, followed by left hemiparesis. Repeated MRI scan (Fig. 2) showed a novel cystic change in right parietal lobe with concentrically alternating bands of higher and lower signal intensity; Balo's concentric sclerosis was diagnosed. We administered methylprednisolone pulse therapy for a complete course and his symptoms were ameliorated with only mild numbness of the left leg 4 weeks later.

Case 2 A 24-year-old woman developed sudden onset of slurred speech, swallowing disturbance and right side weakness. Neurological examination revealed right visual blurring, mild dysarthria, trivial right hand weakness and relative hyperreflexia of right limbs with intact sensation. Brain MRI disclosed one concentric nodule with alternating layers of different signal intensities in the left corona radiata. She received only supportive treatment and the symptoms subsided gradually with only mild sequelae of difficulty in writing.

Discussion The clinical courses of Balo's sclerosis are variable and some may lead to a lethal outcome. The two patients in our series seemed behaving in a relatively benign trail. The characteristic MRI features usually lead to a correct diagnosis without difficulty for experienced neurologists and this is crucial to avoid unnecessary surgical intervention as performed in Case 1. Although the pathophysiology is not yet known, Balo's sclerosis usually responds to steroid well and some may even remit without medications.

171

口服 Fingolimod 用於台灣多發性硬化症患者之初步臨床觀察

楊博丞¹ 楊智超²

恩主公醫院 神經科¹; 國立台灣大學醫學院
附屬醫院 神經部²

Oral Fingolimod in Taiwanese Patients with Multiple Sclerosis. A 4 month assessment. Pao-Chen Yang¹, Chih-Chao Yang²

Department of Neurology, En Chu Kong Hospital¹; Department of Neurology, National Taiwan University Hospital², Taipei, Taiwan

Background Oral fingolimod (FTY720) has previously shown clinical efficacy in phase II/III studies of predominantly Caucasian populations with multiple sclerosis (MS). This is the first time fingolimod has been used in Taiwanese patients.

Objectives: To report 4-month physiological outcomes in Taiwanese patients with relapsing MS treated with fingolimod with the context of routine medical practice.

Methods The purpose of this observational report is to analyze short-term data on safety and effectiveness of fingolimod, in Taiwanese patients who are using fingolimod for the first time. This report explores the incidence of selected physiological related outcomes of fingolimod treatment during follow-up visits.

Results This is the report of 16 Taiwanese patients currently on fingolimod. The mean duration of exposure to fingolimod is 4 month. During first-dose monitoring, a decrease in mean pulse rate of 5bpm was observed 1 hour after the first dose of fingolimod, and reached a maximal decrease from pre-dose values of 12 bpm 5 hours after dosing. Average WBC reduction of 41%

was observed when measured at around 3 weeks, confirming drug efficacy.

Conclusions This study demonstrated the clinical safety of fingolimod for the first time in Taiwanese patients with MS, safety signals are so far consistent with the established effects of fingolimod in Caucasian patients.

172

肌無力症病人的血漿分離及類固醇脈衝合併療法

葉建宏 陳威宏 邱浩彰
新光吳火獅紀念醫院神經科

Combined plasmapheresis (PP) and intravenous methylprednisolone (IVMP) pulse therapy in myasthenia
Jiann-Horng Yeh, Wei-Hung Chen, Hou-Chang Chiu

Department of Neurology, Shin Kong Wu Ho-Su Memorial Hospital, Taipei

Background & purpose IVMP pulse therapy is efficacious in quick amelioration of muscle weakness in myasthenia gravis (MG), however, transient worsening of weakness on corticosteroids is a major concern. Plasmapheresis has been shown to be a successful therapy for patients with MG in crisis or fulminant progression. We applied a combination therapy with PP and IVMP pulse for moderate to severe MG patients.

Method From January 2011 to October 2012, 79 generalized MG patients, 53 women and 26 men, aged

13-77 years, refractory to immune therapy were treated with plasmapheresis. Four out of 79 patients were concomitantly infused with methylprednisolone (1 g/day) for 3 days after the second session of plasmapheresis. We prospectively recorded the MG score and measured acetylcholine-receptor antibody (AchRAb) concentration at baseline and after each session of plasmapheresis, and monthly after plasmapheresis for up to 3 months. We compared all these parameters between PP-IVMP group and PP alone group.

Results The MG score decreased from a mean of 9.5 at baseline to 4.8 after PP-IVMP treatment and from 10.6 to 7.0 after PP treatment alone. The mean clearance of AchRAb was 74.3% of the baseline level after PP-IVMP treatment in two seropositive patients. In the PP alone group, the clearance of AchRAb seemed to slightly lower after PP and 3 months after discharge as compared to combination therapy ($p=0.0753$ and $p=0.0567$, respectively). Transient worsening of weakness did occur in one out of 4 patients and was noted at the 3rd day of IVMP infusion with limb involvement predominantly. This worsening subsided 4 days later. No infection or gastrointestinal bleeding was reported during IVMP treatment.

Conclusion The combination therapy with PP and IVMP is safe and effective

in patients with moderate to severe MG in terms of quicker, higher, and more sustained clearance of pathogenic antibodies after treatment as compared to PP treatment alone.

173

視神經脊髓炎病人腦部核磁共振之影像特徵

廖銘鋒 張國軒 呂榮國 黃錦章 張宏旭
吳逸如 陳瓊美 朱俊哲 郭弘周 徐文俊
羅榮昇
林口長庚紀念醫院 神經內科 多發性硬化症
中心

Magnetic Resonance Imaging Characteristics amongst Patients with Neuromyelitis Optica Spectrum Disorder

Ming-Feng Liao MD, Kuo-Hsuan Chang MD PhD, Rong-Kuo Lyu MD, Ching-Chang Huang MD, Hong-Hsiu Chang MD PhD, Yih-Ru Wu MD PhD, Chiung-Mei Chen MD PhD, Chun-Che Chu MD, Hung-Chou Kuo MD, Wen-Chiun Hsu MD MSc MPhil, Long-Sun Ro, MD PhD
Multiple Sclerosis Center, Department of Neurology, Chang Gung Memorial Hospital-Linkou Medical Center and Chang Gung University College of Medicine Taipei, Taiwan

Background Neuromyelitis optica (NMO) is an inflammatory disease mainly characterized with optic neuritis (ON) and longitudinal extended spinal cord lesions (LESCLs). Recently, many studies have reported that there are also brain lesions in the NMO patients; and those findings cause the challenge to differentiate NMO patients from multiple sclerosis (MS).

Objective Characterization of the specific brain lesion features of

neuromyelitis optica spectrum disorder (NMOSD) by comparing the cranial magnetic resonance imaging (MRI) of patients with NMOSD and MS. Methods: Clinical and cranial MRI data of patients who were diagnosed as NMOSD (with the presence of anti-aquaporin 4 antibodies) or MS were retrospectively reviewed in a referral medical center in Taiwan. Results: 44 and 39 cranial MRIs were obtained from 28 patients with NMOSD and 18 patients with MS, respectively. Ependymal lining (27.3% versus 5.1%, $P=0.007$) and hypothalamus lesions (15.9% versus 2.6%, $P=0.04$) were seen more frequently in NMOSD patients than MS patients. On the other hand, brain lesions of MS patients meet the Barkhof criteria more frequently (13.6% versus 46.2%, $P=0.001$). Juxtacortical, subcortical, basal ganglion, infra-tentorium, corpus callosum and ovoid lesions were also seen in MS more frequently. In contrast to multiple sclerosis, some brain lesions of NMOSD patients (28.6%) disappeared during follow up.

Conclusions NMOSD demonstrates ependymal lining and hypothalamic lesion more frequently than MS. These findings could be helpful to identify NMOSD before the onset of spinal cord lesions.

174

紅斑狼瘡患者以快速危及生命的腦水腫為中樞神經系統的最初及唯一表現

盧彥廷 曾昱龍
高雄長庚紀念醫院 神經內科

Rapid Life-Threatening Global Cerebral Edema As The First and Only Sign of The Central Nervous System Manifestation in Patient with Systemic Lupus Erythematosus

Yan-Ting Lu, Yu-Lung Tseng
Department of Neurology, Chang Gung Memorial Hospital, Kaohsiung Medical Center

Background The major manifestations of central nervous system of systemic lupus erythematosus are boarded. The neuropsychiatric manifestations present a diagnostic and treatment challenge, but there is rare case presenting acute and life threatening global cerebral edema.

Case Report A 31-year-old woman with lupus erythematosus for 6 years had no history of neurological disease and was admitted to local hospital with frequent generalized convulsion. A head computerized tomographic scan showed no hemorrhage or infarct. She was intubated with ventilator support due to status epilepticus. On the next day, she was referred to our emergency department due to shock. The head computerized tomographic scan showed diffused cerebral edema with small intracerebral hemorrhage. Magnetic resonance imaging of the brain showed diffuse cerebral edema, transtentorial and tonsillar herniation. C3 complement dropped to 65 mg/dl and C4 was within low normal limit of 10.2. ANA(1:320 titer) and anti-ENA

screen were positive. The patient had progressive herniation and expired within hours.

Conclusion The life-threatening global cerebral edema and coma are rare CNS complication of lupus. Early survey and recognition of the neuropsychiatric presentation of SLE and aggressive treatment is required to avoid such as fetal and rare complication.

175

懷孕期發生之抗 AMPA 受體腦炎： 一病例報告

魏怡嘉¹ 劉濟弘² 林建志³ 林昆儒⁴ 黃國倫²
李宗海² 彭宗義¹ 林光麟³ 黃錦章²
¹基隆長庚神經內科 ²林口長庚²神經內科 ³小兒神經科 ⁴核子醫學科

Rapid Progression of Anti-AMPA Receptor Encephalitis during Pregnancy

Yi-Chia Wei¹, Chi-Hung Liu^{2*}, Jinn-Jim Lin³, Kun-Ju Lin⁴, Ko-Lun Huang², Tsong-Hai Lee², Tsung-I Peng¹, Kuang-Lin Lin³, Chin-Chang Huang²

¹ Department of Neurology, Chang Gung Memorial Hospital, Keelung Medical Center

² Department of Neurology, ³ Division of Pediatric neurology, ⁴ Department of Nuclear Medicine and Molecular Imaging Center, Linkou Medical Center

Background The α -Amino- 3-hydroxy-5-methyl-4-isoxazolepropionic acid (AMPA) receptor is an ionotropic glutamate receptor located in CNS. AMPA receptors major in fast excitatory transmission and play a key role in CNS plasticity by mediating long-term potentiation and long-term depression. Anti-AMPA receptor encephalitis is a rarely reported autoimmune encephalitis,

which was considered to have restricted involvement of limbic system.

Objectives To study a patient with anti-AMPA receptor encephalitis during pregnancy.

Case Report A 30-year-old primiparous pregnant woman at 11th week gestation was admitted due to headache, behavior change and recent memory impairment for 1 week. She developed fever, dysmetria, ataxia, multi-directional nystagmus, quadriparesis, conscious disturbance, myoclonic seizure, opisthotonus, and status epilepticus in the following 5 days. Status epilepticus was rapidly controlled with midazolam infusion, propofol infusion, levetiracetam, and lamotrigine.

The first brain MRI performed 1 week after onset showed hyperintensity on fluid-attenuated inversion recovery (FLAIR) sequence in the bilateral insula, mesial temporal lobes, and caudate nucleus. CSF study revealed eosinophilic pleocytosis with elevated protein. Infectious studies showed negative results of cryptococcus, tuberculosis, herpes simplex virus, *Angiostrongylus cantonensis*, herpes zoster virus, Japanese encephalitis virus, and West Nile virus. The immunoreactivity study detected anti-AMPA receptor antibodies against GluR2 in this patient. Underlying

malignancy was not found until the latest follow up.

Conclusion Anti-AMPA receptor encephalitis could be fulminant with rapid brain atrophy and extensive CNS involvement including diffuse cerebral cortex, caudate nucleus, and cerebellum. The reversibility of the atrophic brain and the association between anti-AMPA encephalitis and pregnancy need further investigation.

其他

176

致命性副甲氧基甲基安非他命濫用死亡前神經行為表現

尹莘玲^{1,2} 黃宗揚³ 陳偉熹⁴
高雄醫學大學附設醫院 臨床法醫科¹ 法務部
法醫研究所²
高雄地方法院³
高雄長庚紀念醫院 神經內科⁴

The Antemortem Neurobehavior in Fatal Paramethoxymethamphetamine Usage

Hsin-Ling Yin^{1,2}, Chung-Yang Huang³, Wei-Hsi Chen⁴
Department of Clinical Forensic Medicine¹,
Kaohsiung Medical University Hospital and
College of Medicine, Kaohsiung Medical
University, Kaohsiung, Taiwan
Institute of Forensic Medicine¹, Ministry of
Justice, Taipei, Taiwan
Kaohsiung District Local Court², Justice Yuan,
Kaohsiung, Taiwan
Department of Neurology³, Kaohsiung Chang
Gung Memorial Hospital, and College of
Medicine, Chang Gung University, Kaohsiung,
Taiwan

Objective

Paramethoxymethamphetamine (PMMA) is an emerging and prevalent psychoactive drug with a structure

analogous to amphetamine and related psychostimulants. However, the neurobehavioral effect is only studied in experimental animals and has barely been mentioned in human yet.

Methods We reported the clinical and judiciary investigation of the antemortem neurobehavioral manifestations in 8 patients who died of PMMA usage.

Results There were 2 different antemortem presentations. The first group of patients showed delirium, hypertalkativity, and incoherent speech and then turned into convulsions and death. They did not exhibit the typical hyperdopaminergic movement disorder. The second group of patients gradually fell asleep and then suffered respiratory or cardiovascular collapse. The cardiac blood PMMA level was higher in the second group than that in the first group of patients. Forensic autopsy showed variable findings, ranging from no remarkable change to significant pathological damage similar to serotonin syndrome in both groups of patients.

Conclusion PMMA seems to enhance serotoninism than dopaminergism, and exerts a concentration-related dual effect on human.

案例報告：抗 NMDA 受體腦炎

王馨霈 楊玉婉

中國醫藥大學附設醫院神經部暨神經醫學實驗室

Case report: Anti-NMDA receptor encephalitis*Hsin-Pei Wang, Yu-Wan Yang**Neuroscience Laboratory, Department of Neurology, China Medical University Hospital, Taichung, Taiwan***Background**

Anti-NMDA(N-methyl-D-aspartate) receptor encephalitis was first described in 2007 in a cohort study of 12 women presenting severe neuropsychiatric syndrome with autoantibodies targeting glutamate receptors. After first patient was diagnosed, there were increasingly documented cases. The manifestations were usually psychotic problems (bizarre behavior, hallucination, memory deficits), seizure, and dyskinesia. At the beginning of diagnosis, large proportion of patients was regarded as drug-induced psychosis. Here we report a patient with suspected anti-NMDA receptor encephalitis.

Case Report A 20-year-old female student with a history of type 2 diabetes mellitus for 5 years was admitted due to acute disturbing behavior. No prominently developmental delay was noted in this patient in the past. Her personality was submissive and introverted. However, three months ago, she had transient depression due to arguments with her coworker. Poor attention was noted by her coworker 10 days prior to this admission. She also

told her family that she felt paresthesia over bilateral lower limbs. Furthermore, her parents noticed that she became agitated and had loosening of association between speech and thoughts. Hallucinations developed later. Physical examinations revealed no prominent abnormality. Laboratory data showed hyperglycemia (HbA1c:8.8%), elevated liver enzymes (GOT/GPT:44/50IU/L), and abnormal tumor marker (CA-125: 35.5U/mL). There was some slimming drugs used recently. The 24-hours-EEG indicated generalized paroxysmal sharp wave with phase reversal at C4 and T4. No abnormality was disclosed in the brain MRI and the lumbar puncture. The autoimmune profile was normal, except weakly positive NMDA receptor antibodies. So we applied plasma exchange five times every two days. Her consciousness was recovery dramatically (from coma to clear).

Conclusion Anti-NMDA receptor encephalitis predominantly affects young women and evolves through several stages: prodromal symptoms, psychotic stage, unresponsiveness with hypoventilation, dyskinesia, and autonomic instability. This disease was rare, but it became more recognized in recent years. The treatment is significantly effective. So we should keep it in mind that young people presenting with acute psychosis in the absence of other organic problems

might have anti-NMDA receptor encephalitis.

178

肝轉移性顱內腦膜瘤

吳鈺慈 孫明輝 黃志仁
光田綜合醫院 神經內科

Intracranial Meningioma with Hepatic Metastasis: A Case report

Yu-Tzu Wu, Ming-Hui Sun, Chih-Jen Huang
Department of Neurology, Kuang-Tien General Hospital

Background Meningiomas are slow-growing intracranial/intraspinal tumours, with a wide range of histopathological variants. The more aggressive atypical and malignant types can disseminate via the venous system, lymphatics and CSF with the lungs and pleura being the most common sites of extracranial metastasis.

Case report A 71 year-old female patient who had a history of recurrent meningioma. She underwent craniotomy and tumor resection 15 year ago. Further resection was done due to tumor recurrence with invasion to skull and scalp that occur on separate occasions. Three weeks after her last craniotomy and tumor resection, she was re-admitted due to communicating hydrocephalus, a ventriculo-peritoneal (VP) shunt was inserted, which was revised 6 months after due to VP shunt malfunction. This time, she was admitted due to acute pancreatitis with concomitant calculous cholecystitis and cholangitis. Cholecystectomy was performed. Incidentally, a nodular lesion was found over

liver segment S4, a hepatectomy was done and tissue was sent for biopsy, which revealed a gross appearance of grayish white tumor. Immunohistochemically, the liver tumor showed diffuse strong expression for vimentin and focal positivity for epithelial membrane antigen, an immunophenotype typical for meningioma.

Conclusion This case demonstrate the possibility of Liver metastasis from VP shunt drainage, although the more commonly postulated venous route of spread could not be entirely excluded.

179

老人跌倒整合預防保健介入模式

李雪楨¹ 張谷州² 曹昭懿³ 洪禎雯⁴ 黃裕淨⁵
² 林桑伊⁵ 台灣防跌研究團隊
¹ 國立陽明大學物理治療暨輔助科技學系
² 高雄長庚紀念醫院神經內科腦血管科
³ 台灣大學物理治療系
⁴ 高雄長庚紀念醫院復健科
⁵ 成功大學物理治療系

Effects of a Multifactorial Fall Prevention Program on Fall Incidence and Physical Function in Community-dwelling Elderly with Risk of Fall.

Lee HC¹, Chang KC², Tsauo JY³, Hung JW⁴, Huang YC², Lin SF⁵, Taiwan fall prevention initiatives investigators
¹ Department of Physical Therapy and Assistive Technology, National Yang-Ming University, Taipei, Taiwan
² Division of Cerebrovascular Diseases, Department of Neurology, Kaohsiung Chang Gung Memorial Hospital, Kaohsiung, Taiwan
³ Department of physical therapy, National Taiwan University
⁴ Department of Rehabilitation Medicine, Kaohsiung Chang Gung Memorial Hospital, Kaohsiung, Taiwan
⁵ Department of physical therapy, National Cheng Kung University

Objective To evaluate effects of a multifactorial fall prevention program on fall incidence and physical function in community-dwelling older people.

Design Multi-center randomized controlled clinical trial

Setting Three medical centers and adjacent community health centers in Taiwan.

Participants Community-dwelling elderly who had fallen in the previous year or at risk for falls

Interventions After baseline assessment, eligible subjects were randomly allocated into the intervention group (IG) or control group (CG) stratified by Physiological Profile Assessment (PPA) fall-risk level. IG received a 3-month multifactorial intervention program including 8-week exercise training, health education, home hazards evaluation/ modification, along with medication review and ophthalmology/other specialty consultations. CG got health education brochures, referrals and recommendations without direct exercise intervention.

Main outcome measures Primary outcome was the incidence for falls within one year. Secondary outcomes were PPA battery (overall fall-risk index, vision, muscular strength, reaction time,

balance and proprioception), timed up-and-go (TUG), Taiwanese-International Physical Activity Questionnaire, EuroQoL-5D, Geriatric Depression Scale (GDS), and Fall Efficacy Scale at 3 months after randomization.

Results There were 616 participants, aged 76 ± 7 years, including low risk 25.6%, moderate risk 25.6% and marked risk 48.7%. The cumulative 1-year fall incidence was 25.2% in IG and 27.6% in CG (HR=0.90, 95% CI 0.66-1.23). IG improved more favorably than CG on overall PPA fall-risk index, reaction time, postural sway with eyes open, TUG, and GDS, especially for those with marked fall risk.

Conclusion The multifaceted fall prevention program with exercise intervention improved functional performance at 3-months for community-dwelling elders with a risk for falls, but did not reduce falls over 1-year follow-up. Fall incidence might have been decreased simultaneously in both groups by heightened awareness engendered during assessments, education, referrals, and recommendations.

180

血栓溶解治療在中央健康保險給付規定中之不確定概念

林綉紅 趙千淑 陳廷耀 張谷州 劉嘉為
陳偉熹

高雄長庚紀念醫院 神經內科系暨腦中風中心

The Uncertain Concept in Payment Regulation for Thrombolysis by the Central Health Insurance Bureau, Taiwan

Hsiu-Hung Lin, Chien-Shu Chao, Teng-Yeow Tan, Ku-Chou Chang, Chia-Wei Liou, Wei-Hsi Chen
Department of Neurology and Stroke Center, Kaohsiung Chang Gung Memorial Hospital, and College of Medicine, Chang Gung University, Kaohsiung, Taiwan

目的 由於急性缺血性腦中風並沒有特別治療之方法，故血栓溶解目前被廣泛接受。為了安全起見，中央健康保險局設定必須先通過收錄條件和排除條件才能使用。但是嚴格的收錄條件和排除條件相對地剝奪醫療消費者接受醫療的權利，也因此在世界各地發生多起對收錄條件和排除條件之認知有差異的司法訴訟。

方法 回顧我國血栓溶解劑藥品給付規定中之收錄條件和排除條件，並與其他國家之規定比較。

結果 在中央健康保險局所設定的收錄條件和排除條件中，有三項條文的內容可能對民眾和醫療提供者產生認知差異，分別為臨床嚴重程度、臨床上恢復速度和程度、及其他狀況之項目。其差異主要原因是文字解釋和規範不確定，與疾病狀況裁量範圍過於擴大。

結論 藥品給付規定之條文內容必須清楚和合理，讓醫療消費者、醫療提供者、行政管理者、法律工作者互相之間的差異減少，認知趨向一致。因此，建議部份修改這三條條文之內容，讓各方面認知更接近，減少歧見，醫療才能正常發展。

181

利用流式細胞技術來分析血液病變

邱奕賓¹ 王韋翔¹ 楊逸群² 廖奕翰² 葉伯壽¹

¹台大新竹分院神經內科

²國立交通大學應用化學系

Using Flow Cytometry to assay hematologic disorders

Yi-Pin Chiu¹, Wei-Hsiang Wang¹, Yi-Cyun Yang², Ian Liao², Bak-Sau Yip¹

¹Neurological Institute, National Taiwan University Hospital Hsin-Chu Branch,
²The Department of Applied Chemistry, National Chiao Tung University

Background Hematologic disorders include erythrocyte disorders, platelet disorders, blood cell dyscrasias, coagulation disorders, etc. These diseases play an important role in many neurologic disorders. There are several clinical methods to assay hematologic disorders, including blood cell analyzer, bone marrow aspiration and bone marrow biopsy to detect the blood cell count and morphology.

Objective The traditional method to assay hematologic disorders focus on blood cell numbers and cell morphology. Our study tried to establish a new method to assay the functions of blood cell.

Method Flow cytometry is a laser based, biophysical technology employed in cell counting, sorting, biomarker detection and protein engineering, by suspending cells in a stream of fluid and passing them by an electronic detection apparatus. It allows simultaneous multiparametric analysis of the physical and/or chemical characteristics of up to thousands of particles per second. We use the flow cytometry to assay the function of blood cell.

Result By using the new method, we can assay not only the counts and morphology of blood cells but also detail functions of blood cells.

182

原發性惡性腦膜黑色素瘤：案例報告

柯子翔 邱瑋婷 胡朝榮

台北醫學大學-行政院衛生署雙和醫院神經科

Primary Malignant Meningeal

Melanoma: A Case Report

Tzu-Hsiang Ko M.D, Wei-Ting Chiu M.D,

Chaur-Jong Hu M.D

Department of Neurology, Shuang-Ho Hospital,

Taipei Medical University, New Taipei City,

Taiwan

Background A 41-year-old man, who is diagnosed as primary malignant meningeal melanoma, presented with symptoms and signs mimicking meningitis.

Case Report A 41-year-old man without underlying diseases was initially admitted due to headache, dizziness, and vomiting for two weeks. He had been hospitalized in another hospital under the diagnosis of aseptic meningitis, but the symptoms persisted after anti-viral therapy. During the first hospital course, brain MRI revealed diffuse abnormal leptomeningeal enhancement. CSF showed mild pleocytosis only. We gave him an osmotic agent and the headache improved gradually. Left facial numbness was observed and was considered as a seizure disorder, which subsided with anti-epileptic therapy. After discharge, intermittent headache and vomiting continued. The patient subsequently developed memory impairment,

paraphasia, loss of motivation, auditory and visual hallucinations, and sleep disturbance. During the second hospital course, CSF cytology revealed increased cellularity and some mildly pleomorphic cells, otherwise unremarkable. Whole spine MRI showed leptomeningeal enhancement in the whole spine, brainstem, cerebellum, and the visualized part of brain. Open biopsy of the leptomeninges was performed and it showed malignant melanoma. There was no evidence of intraocular melanoma and skin biopsy of a nevus at right lateral upper arm showed benign intradermal nevus. There was no other lesion detected by PET examination. Therefore, primary malignant meningeal melanoma was diagnosed.

Conclusion Primary malignant meningeal melanoma is a rare disease. It may mimic the clinical presentations of subacute or chronic meningitis. Meningeal biopsy should be considered if the diagnosis is uncertain.

183

中風病患非正式照顧者之負荷程度及相關因子

洪禎雯¹ 黃裕淨² 張谷州²

¹高雄長庚紀念醫院神經內科腦血管科

²高雄長庚紀念醫院復健科

Factors Associated with Strain in Informal Caregivers of Stroke Patients

Jen-Wen Hung¹; Yu-Ching Huang², Ku-Chou Chang².

¹Department of Rehabilitation Medicine,

Kaohsiung Chang Gung Memorial Hospital, Kaohsiung, Taiwan,
²*Department of Neurology, Kaohsiung Chang Gung Memorial Hospital and Chang Gung University College of Medicine, Kaohsiung, Taiwan;*

Background Stroke is one of the most prevalent causes of adult disability and handicap. Informal caregivers play an important role in poststroke care. However, informal caregivers may experience strain, which threatens the recovery of stroke subjects. This study aimed to describe changes in strain experienced by informal caregivers from 3 to 6 months after the stroke, and identify the predicting factors.

Methods We recruited pairs of inpatients with ischemic stroke and informal caregivers from a tertiary referral hospital and interviewed them at 3 and 6 months after the stroke. Caregiver strain was evaluated using the Caregiver Strain Index (CSI), with a CSI ≥ 7 indicating considerable caregiver strain. Various factors associated with caregiver strain were analyzed using generalized estimating equations.

Results Eighty-nine stroke patients and caregivers completed the study. Considerable strain was reported in 46% and 43% of the caregivers at the 3rd and 6th month, respectively. Patient factors such as severe disabilities (Barthel Index ≤ 60), poor cognition (Mini-Mental State Examination ≤ 23), depression (Beck Depression Inventory [BDI] ≥ 10), and recurrent stroke were predictors for

caregiver strain. Caregiver factors, such as changed employment status, help from formal caregivers, and depression (BDI ≥ 10) were also associated with considerable caregiver strain.

Conclusions Nearly 50% of caregivers experienced considerable strain. Interventions aimed at reducing the caregivers' strain should focus on enhancing the functional and emotional status of stroke subjects, prevention of recurrent stroke, and efficient management of depression symptoms in caregivers.

184

全民健康保險腦中風治療效益分析

張谷州¹ 李雪楨² 黃裕淨¹ 洪禎雯³ 邱顯學^{1,4}
陳俊忠² 李宗海⁵

¹高雄長庚紀念醫院神經內科腦血管科

²國立陽明大學物理治療暨輔助科技學系

³高雄長庚紀念醫院復健科

⁴高雄長庚紀念醫院中醫針傷科

⁵林口長庚紀念醫院神經內科腦血管科

Cost-effectiveness analysis of stroke management under a universal health

Ku-Chou Chang¹, Hsuei-Chen Lee², Yu-Ching Huang¹, Jen-Wen Hung³, Hsienhsueh Elley Chiu^{1,4}, Jin-Jong Chen², Tsong-Hai Lee⁵

¹Division of Cerebrovascular Diseases, Department of Neurology, Kaohsiung Chang Gung Memorial Hospital, Kaohsiung, Taiwan

²Department of Physical Therapy and Assistive Technology, National Yang-Ming University, Taipei, Taiwan

³Department of Rehabilitation Medicine, Kaohsiung Chang Gung Memorial Hospital, Kaohsiung, Taiwan

⁴Division of Acupuncture & Traumatology, Department of Traditional Chinese Medicine, Kaohsiung Chang Gung Memorial Hospital, Kaohsiung, Taiwan

⁵Stroke Center, Department of Neurology, Linkou Chang Gung Memorial Hospital, Taoyuan, Taiwan

Objective Cost-effectiveness analysis (CEA) of stroke management was evaluated in three care models: Neurology/Rehabilitation wards (NW), Neurosurgery wards (NS), and General/miscellaneous wards (GW), under a universal health insurance system.

Methods From 1997 to 2002, subjects with first-ever acute stroke were sampled from NHI claims data of a nationally representative cohort in Taiwan, categorized as hemorrhage stroke (HS), including subarachnoid hemorrhage (SAH), and intracerebral hemorrhage (ICH); or ischemic stroke (IS), including cerebral infarction (CI), and transient ischemic attack/ unspecified stroke (TIA/unspecified); with mild-moderate and severe severity. All-cause readmissions or mortality (AE) and direct medical costs during first-year (FYMC) after stroke were explored. CEA was performed by incremental cost-effectiveness ratios.

Results 2368 first-ever stroke subjects including SAH 3.3%, ICH 17.9%, CI 49.8%, and TIA/unspecified 29.0%, were identified with AE 59.0%, 63.0%, 48.6%, and 46.8%, respectively. There were 50.8%, 13.5%, and 35.6% of stroke patients served by NW, NS and GW, with AE 44.9%, 60.6%, and 56.0%, and medical costs of US\$ 5,031, US\$ 8,235, and US \$ 4,350, respectively. NW was cost-effective for both mild-moderate and

severe IS. NS was the dominant care model in mild-moderate HS, while NW appeared to be a cost-minimization model for severe HS.

Conclusions TIA/unspecified stroke carried substantial risk of AE. NS performed better in serving mild-moderate HS, whereas NW was the optimal care model in management of IS.

185

貝爾氏麻痺增加癌症之風險：五年追蹤研究

許昭俊¹ 林恆慶²

¹ 台北醫學大學附設醫院 神經科

² 台北醫學大學 醫務管理學系

Increased Risk of Cancer Following Bell's Palsy: A Five-year Follow-up Study

Jau-Jiuan Sheu¹, Heng-Ching Lin²

¹ Department of Neurology, Taipei Medical University Hospital

² School of Health Care Administration, Taipei Medical University

Background and Purpose The etiology of Bell's palsy is usually unclear. The most commonly proposed pathomechanism involves the reactivation of latent herpes simplex virus type I and varicella-zoster virus, which is associated with immunosuppressed states. The risk of cancer is also elevated in immunosuppressed patients. The purpose of this study was to investigate the risk for cancer during a 5-year follow-up period after diagnosis of Bell's palsy by using a population-based dataset in Taiwan.

Methods This study drew a study cohort and a comparison cohort from the “Longitudinal Health Insurance Database 2000” released by the Taiwan National Health Research Institute. A total of 2,618 patients with Bell’s palsy were included as the study cohort and 13,090 patients without Bell’s palsy were included as comparison cohort. Each patient was individually tracked for 5 years from their index ambulatory visit to identify those in whom cancer diagnosed. Cox proportional hazards regression was performed to compare the 5-year risk of subsequent cancer between the study and comparison cohorts.

Results We found that the incidence of cancer was 1.55 (95 % CI 1.35–1.78) per 100 person-years for patients with Bell’s palsy and 1.09 (95 % CI 1.02–1.18) per 100 person-years for comparison patients. The hazard ratio (HR) for cancer during the 5-year follow-up period for patients with Bell’s palsy was 1.43 times that for comparison patients (95 % CI 1.22–1.73), adjusting for urbanization, monthly income, geographic region, and diabetes. In analysis by cancer location, we detected increased risk of oral cancer, gastrointestinal cancer, and cancer at other sites between patients with Bell’s palsy and comparison patients.

Conclusion Our study found that Bell’s palsy was significantly associated with an increased risk of subsequent cancer during a 5-year follow-up period.

Because the increased cancer risk in the follow-up years may be indicative of the presence of an occult malignancy at the time of Bell’s palsy diagnosis, our findings may warrant increased screening for occult malignancies among patients with Bell’s palsy.

186

使用動態模型及最適化方法尋找萊希尼亨症候群的治療目標酵素

許凱程
許凱程腦神經內科診所

Detection of enzyme targets by dynamic modeling and optimization: Application to Lesch–Nyhan syndrome

Hsu Kai-Cheng
Hsu Kai-Cheng Neurology Clinic

Motivation Mathematical modeling and optimization have been used in detection of target enzyme in human metabolic disorders. This method integrates available biomedical data and builds a dynamic model of human metabolic system. Target enzymes for treatment are discovered through optimization method. Lesch–Nyhan syndrome is an inherited disorder with several neurological symptoms. It is caused by a deficiency of the enzyme hypoxanthine-guanine phosphoribosyltransferase (HGPRT) involving in uric acid metabolism. We introduce the fuzzy optimization method to find the potential enzymes for drugs design in this metabolic disorder.

Results An existing GMA-system model of human uric acid metabolism was used. Lesh-Nyhan syndrome was defined in the model. The fuzzy optimization method was used to normalize the concentration of uric acid. In addition, the normalization of other metabolites in the model was also considered with multiple objectives optimization. The fuzzy optimization method detected several potential enzymes for treatment. The purpose of this work is to provide a method to save time and cost of drugs development.

187

在台灣健保申報資料中找出慢性腎臟病人：一個驗證研究

陳志弘¹, 楊高雅慧², 謝鎮陽^{2,3}

¹成大醫院腦中風中心暨神經部

²成大醫學院臨藥所

³台南新樓醫院腦中風中心暨神經內科

Identification of Patients with Chronic Kidney Disease from National Health Insurance Claims Data in Taiwan: a Validation Study

Chih-Hung Chen¹, Yea-Huei Kao Yang², Cheng-Yang Hsieh^{2,3}

¹Stroke Center and Department of Neurology, National Cheng Kung University Hospital

²Institute of Clinical Pharmacy and Pharmaceutical Sciences, National Cheng Kung University

³Stroke Center and Department of Neurology, Sin Lau Hospital, Tainan, Taiwan

Objective To validate several claims-based approaches for the identification of patients with chronic kidney disease (CKD) by using diagnosis codes from National Health Insurance (NHI) claims data in Taiwan.

Background National Health Insurance Research Database, derived from claims data of NHI, might provide an efficient source for outcomes research in patients with CKD. However, in the absence of laboratory data, one would need to identify patients with CKD from diagnosis codes associated with health care claims. The validity of this approach to identify patients with CKD has not been sufficiently studied in Taiwan.

Methods From stroke registry database of a single medical center, we obtained the first serum creatinine measurement of 1,317 elderly NHI beneficiaries upon hospitalization for acute ischemic stroke and calculated each patient's estimated glomerular filtration rate (eGFR). We then searched all other discharge diagnosis in the claims data for the presence of a diagnosis code for diabetic nephropathy, hypertensive nephropathy, chronic renal insufficiency, and miscellaneous other renal diseases. Using the gold standard of an eGFR less than 60 mL/min/1.73 m² for definition of CKD, we calculated the sensitivity, specificity, and positive and negative predictive values for each of these diagnoses and combinations of these diagnoses.

Results The sensitivity of individual diagnosis algorithms ranged from 1.6%

for diabetic nephropathy to 5.3% for miscellaneous causes. Besides, the “miscellaneous” group had a comparable specificity (97.4%) with all other individual diagnosis algorithms (all >99%). Using combinations of these algorithms failed to improve the sensitivity. Positive predictive values generally were high (88.5% to 100.0%), but negative predictive values were low (46.6% to 47.8%).

Conclusion High positive predictive values indicate that NHI claims data can be used to accurately identify patients with CKD for study. However, the utility of such databases for comparison of patients with CKD versus lesser degrees of CKD is limited.

188

衛生署核准適應症外使用司法判決-由癲通案件看法律演變和醫界因應

陳偉熹¹ 陳志銘²
高雄長庚紀念醫院¹神經內科²高雄地方法院

Judiciary Decrees in Off-label Use - Legal Change and Professional Response from Carbamazepine Cases

Wei-Hsi Chen¹, Jih-Ming Chen²
Department of Neurology¹, Kaohsiung Chang Gung Memorial Hospital, and College of Medicine, Chang Gung University, Kaohsiung, Taiwan

Kaohsiung District Local Court². Justice Yuan, Kaohsiung, Taiwan

目的 雖然在我國之法律條文中並沒有將衛生署核准適應症外使用定義或列舉，然而衛生署核准適應症外使用產生之傷害，被認為是侵害他人之人格權，故可以循刑法或民法請求賠償。其侵害他人之權利，主要可以分為違反告知義務和違反注意義務。

知義務和違反注意義務。

方法 以癲通為例，藉由最高法院刑事判決 101 年度台上字第 2637 號和先前相關判決之結果，探討我國司法對衛生署核准適應症外使用之法律演變，和建議醫界因應方向。

結果 在本判決中，關於衛生署核准適應症外使用，對醫療行為違反告知義務和違反注意義務之認知，已經產生重要的影響，預期將改變往後相關之判決。本案件由 2002 年開始偵查，至 2004 正式起訴，在各級法院中歷經多次上訴和重審。本案件被認為有過失是基於醫師並沒有對病人清楚告知癲通之副作用，而不認為有過失是基於癲通之使用被認為符合合理使用且副作用無法注意。在本判決中，法官將告知義務和注意義務完全切割，認為縱然違反告知義務，病人之死亡為是否違反注意義務，故過失必須基於往後是否有違反注意義務。

結論 由本案件之判決結果，改變以往司法只重告知義務，卻忽略病人傷害之事實應為注意義務是否有違反所致。醫界在往後之訴訟中，必須將重點放在違反注意義務之上，而非只爭論是否有違反告知義務。

189

以胸壁疼痛為初始表現之胸椎原發性惡性黑細胞癌

陳瑋芬¹周志和²
新樓醫院 神經內科¹奇美醫院神經內科

Chest wall pain as the initial manifestation in a patient with primary melanoma in the thoracic spine

Wei fen Chen¹, Chih-Ho Chou²

¹ Department of neurology, SinLau Hospital The Presbyterian Church in Taiwan

² Department of neurology, Chi Mei Medical Center

Background Primary spinal melanomas, which predominately affect the middle or lower thoracic spine, are extremely rare. Melanoma occurs most commonly in white populations and is rare in Asian populations.

Case Report A 44 year-old male presented with left lower chest wall pain for several months. He considered that was contributed to a minor muscle strain injury. Acute onset of lower abdominal numbness and bilateral leg weakness has been noted for 10 days and intermittent numbness over bilateral inguinal regions on cough or exertion. The sphincter was intact. Spinal magnetic resonance imaging (MRI) revealed a space-occupying lesion at the T8-9 level. A standard posterior midline approach was used under the impression that the subacute subdural hematoma was caused by a hidden vascular anomaly or a rare pigmented tumor. A dark black-colored and hard intradural mass was found, and gross removal was performed. This was confirmed as a melanoma by immunohistochemistry. Dermatologic and ophthalmologic examinations did not reveal any other focus of primary melanoma. Histopathological investigation confirmed malignant melanoma. No hypermetabolic lesions were noted on whole-body FDG-PET. The patient was discharged with

improvement of motor weakness. Subsequent radiotherapy was administered.

Conclusion Image studies are indicated for all cases with back pain and chest wall pain that is unresponsive to a few weeks of conservative treatment. Malignancy must always be considered in the differential diagnosis.

190

原發部位不明的轉移癌以右外展神經麻痺為臨床表現:一病例報告

郭蔭庭

亞東紀念醫院 內科部 神經內科

Metastasis of unknown origin presented as right abducens nerve palsy: A Case Report

Yam-Ting Kwok

Division of Neurology, Department of Internal Medicine, Far Eastern Memorial Hospital

Background Abducens nerve palsy may be a presentation of metastasis or even paraneoplastic syndrome but is rarely caused by unknown origin with negative neuroimaging findings and CSF studies.

Case Report A 56-year-old woman with a past history of chronic headache under control for more than 5 years has suffered from progressive right temporal headache for two months and toothache and swelling on the right face for two weeks. Sudden onset of double vision was present at any time as she was gazing to the right in recent

one week. There was no fever, recent common cold or body weight change. Neurological examination was essentially normal with isocoric reactive pupils except impaired abduction of right eye in favor of right abducens nerve palsy. CSF studies including cell counts and cytology were normal. Laboratory data showed no evidence of diabetes mellitus or thyroid dysfunction but anemia, thrombocytosis, elevated C-reactive protein, CEA, CA-199, and CA-125. CTA of head revealed no hyperdense intracranial hemorrhagic events, but mild brain cortical atrophy with suspicious osteolytic lesion causing bony destruction at C5 left pedicle and lamina in favor of bony metastases. Mild dilatation of distal BA but no aneurysmal sac was detected in Willis circle. MRI of brain showed mild brain atrophy. No definite evidence of space-occupying lesion or abnormal enhancement within brain parenchyma. Whole body bone scan revealed degenerative change or suspicious bone metastases in cervical spines and thoracolumbar spines with right mastoiditis or otitis. Abdominal echogram revealed multiple hepatic tumors, probably metastatic tumor. CT scan of chest and liver triphase CT scan showed multiple metastases at both lobes of liver and left aspect of lower C spines and suspected bilateral lung metastases. PES showed gastritis. Colonoscopy revealed colonic ulcers but no evidence of malignancy. Mammographic finding was negative. The consultation of dentist

was also arranged, Needle liver biopsy revealed metastatic adenocarcinoma from lower gastrointestinal tract. Therefore, under the impression of metastasis of unknown origin (MUO) with multiple livers and spines involvement, the patient received linear accelerator teletherapy.

Conclusion Malignancy, especially associated with metastasis, should be always kept in mind in patient with sudden onset of focal neurological deficit.

191

罕見肝癌轉移至海綿竇

曾為世 宋岳峰

國軍左營總醫院潛水醫學部, 三軍總醫院神經內科

A rare case of cavernous sinus metastasis from hepatocellular carcinoma

*Wei-Shih Tseng and Yueh-Feng Sung
Department of Diving Medicine, Zuoying
Armed Forces General Hospital, Kaohsiung,
Department of Neurology, Tri-Service General
Hospital, Taipei.*

Background Metastasis to the cavernous sinus (CS) from hepatocellular carcinoma (HCC) is extremely rare. To our knowledge, there are only four such cases reported in the literature. We report a case of acute painful ophthalmoplegia (PO) of right abducens nerve secondary to cavernous sinus metastasis in a 48-year-old Taiwanese male with HCC, which progressed to total ophthalmoplegia of right eyeball movement rapidly.

Case Report A 48-year-old Taiwanese man with hepatitis B virus (HBV)-related HCC presented to the Emergency Department (ED) with a 5-day history of gradual onset right-sided inner-orbital pain and double vision. After hospitalization, steroid was administered for suspected Tolosa-Hunt syndrome (THS). However, there was no improvement of his PO after a two-day course of steroid therapy. Magnetic resonance imaging (MRI) of his brain with contrast was performed and detected a mass in the right CS. Metastasis to the CS from HCC was highly suspected. After discussion with the patient, conservative and opioid therapy was started for PO. Ten days after admission, the patient developed right total ophthalmoplegia with ptosis. He declined palliative radiotherapy treatment and received hospice care.

Conclusion Painful ophthalmoplegia involves various etiologic factors in a wide spectrum, from inflammation to malignancies. Clinicians may wish to consider the potential in other malignancies except for the most common primary sites of metastasis to the CS in a patient without any history of cancer who presents with painful ophthalmoplegia.

192

以眼眶尖端症候群為初始表現的轉移性神經內分泌腫瘤

黃彥瑜 許維志
台北新光吳火獅紀念醫院

Metastatic Neuroendocrine tumor with initial presentation of Orbital Apex Syndrome

Yen-Yu Huang, Wei-Chih Hsu
Department of Neurology, Shin-Kong WHS Memorial Hospital

Background Neuroendocrine tumors are relative slow growing tumor, usually arise from gastrointestinal tract or bronchopulmonary sources. We described a rare case of high grade neuroendocrine tumor of unknown primary site with initial presentation of progressive ptosis and vision loss as orbital apex syndrome.

Case Report A 64-year-old man was previously healthy and denied any regular medication. He was admitted for progressive ptosis and insidious dull pain over left eye and temporal region for 1 month. He also felt general malaise and poor appetite recently, and the body weight loss was 5 kilograms within 1 month. There was no fever, rhinorrhea, nose stuffy, tinnitus, diplopia or diurnal change of ptosis. Neurologic examination showed left ptosis, mild swelling palpebrae without erythematous change, sluggish light reflex, and no EOM limitation or visual acuity change on the day of admission. The symptom progressed rapidly within 1 week that his left eye could only perceive light, and had limitations in vertical gaze. Orbital apex syndrome was suspected by above neurological deficits. Brain MRI showed a soft tissue lesion in

cavernous sinus with extension to orbital apex, and enlarged left optic nerve. Theoretically, high dose steroids may be tried in this patient, who had no malignancy history. After discussion with patient and family members, transnasal cavernous sinus biopsy showed high-grade malignant tumor with neuroendocrine differentiation. PET showed increased uptake at left orbital area, spine, rib cage and liver. Echo-guided liver biopsy revealed the same pathological characteristics. The primary site of tumor was unclear.

Conclusion Nonfunctional neuroendocrine tumors with orbital metastasis are rare, and the diagnosis was difficult in the absence of a previous cancer history. The pathologic evidence is crucial for the diagnosis. Immunohistochemistry study may help in indentifying a neuroendocrine origin. Therapeutic steroid trial has been regarded as the first line management in patients with orbital apex mass of unknown nature. However, this strategy may delay the diagnosis of our patient. We recommend that tissue proof may be considered firstly if the risk is not high and technique support is sufficient.

193

等距量尺中文腦中風衝擊量表之發展與應用：不同嚴重度腦中風預後復原趨勢之比較

黃裕淨¹ 張谷州^{1,2,3,4} 洪碧霞⁵ 洪禎雯⁶ 李雪楨⁷

¹ 高雄長庚紀念醫院神經內科系腦血管科
² 長庚大學醫學系

³ 高雄長庚紀念醫院出院準備服務中心
⁴ 育英醫護管理專科學校老人服務事業管理科
⁵ 國立臺南大學測驗統計研究所
⁶ 高雄長庚紀念醫院復健科
⁷ 國立陽明大學物理治療暨輔助科技學系

Rasch Analysis on the Mandarin Version of Stroke Impact Scale: Exploration of Prognosis of Stroke Patients Categorized by Initial Severity

Yu-Ching Huang¹, Ku-Chou Chang^{1,2,3,4}, Pi-Hsia Hung⁵, Jen-Wen Hung⁶, Hsuei-Chen Lee⁷.

¹ Division of Cerebrovascular Diseases, Department of Neurology, Kaohsiung Chang Gung Memorial Hospital, Kaohsiung, Taiwan;

² Department of Neurology, College of Medicine, Chang Gung University, Taoyuan, Taiwan;

³ Discharge Planning Service Center, Kaohsiung Chang Gung Memorial Hospital, Kaohsiung, Taiwan;

⁴ Department of Senior Citizen Service Management, Yuh-Ing Junior College, Kaohsiung, Taiwan;

⁵ Program of Measurement and Statistics, Department of Education, National University of Tainan, Taiwan;

⁶ Department of Rehabilitation, College of Medicine, Chang Gung University, Taoyuan, Taiwan;

⁷ Department of Physical Therapy and Assistive Technology, National Yang-Ming University, Taipei, Taiwan

Introduction Stroke is the leading cause of adult disability and impacts the quality of life due to changes in life style. This study developed a mandarin version of Stroke Impact Scale (M-SIS). Validation was done on the reliability, validity, and hierarchical order of items for the strength measure and item map. M-SIS was applied in stroke patients categorized by stroke severity to explore the flux of quality of life (QoL) at six months after stroke.

Methods SIS 3.0 with 59 items in 8 domains was used as the prototype to

develop the M-SIS by pretests in 25 stroke patients, including 10 mild stroke patients, 10 moderate, and 5 severe stroke patients. M-SIS was applied in 218 stroke patients, including 94 mild stroke patients, 64 moderate and 60 severe stroke patients. Rasch analysis was performed to evaluate psychometric characteristics of the M-SIS with fit statistic and person or item separation index. Descriptive analysis was used to evaluate the flux of QoL. Hierarchical linear modeling was used to explore the change of the slope of three evaluations: 2 weeks within admission, 3 months and 6 months after stroke.

Results First measurement was done at 13.4 days after admission for with the following demographics: mean age 68 years, 57.8% female, 88.1% education level less than 6 years, 35.8% illiterate with average Barthel index of 44.3. The reliability and validity were fairly acceptable with internal consistency of coefficient 0.89. The physical contents of M-SIS correlated with NIHSS by coefficient 0.80 ($p < 0.05$), while the correlation of psychological contents was lower than expected. As the unidimensionality remained, no reduction from the 59 was done. Six months after stroke, the improvement of QoL of mild and moderate stroke patients was better than severe stroke patients.

Discussion Generally, M-SIS was a valid and reliable tool for measurement

of QoL after stroke. The hierarchical order of items for the strength measure and item map of M-SIS from this study might be referenced as one of the outcome measures after stroke.

194

單純的非創傷性外展神經麻痺

楊自強 童偉輝 王馨範 陳崇文 連啟勳
陳淑儀 許弘毅
童綜合醫院 神經內科

Isolated nontraumatic abducens nerve palsy

Chi-Chiang Yang, Wai-Fai Tung, Hsin-Fan Wang, Chung-Wen Chen, Chi-Hsun Lien, Shu-Yi Chen, Hung-Yi Hsu
Department of Neurology Tungs' Taichung MetroHarbor Hospital

Background Abducens nerve palsy (ANP) is the most common isolated palsy due to the long peripheral course of the nerve. The abducens nucleus is located in the caudal pons at the level of the facial colliculus. In the vicinity of the abducens nerve nucleus are facial nerve loop and pontine gaze center, so nuclear lesion of the abducens nerve is extremely rare. Abducens nerve exits the brainstem at the border of the pons and medullary pyramids. Upon exiting the brainstem it climbs superiorly along the ventral surface of the pons. On its way to the cavernous sinus it passes at the apex of the petrous portion of the temporal bone. In the cavernous sinus it passes medially to the internal carotid artery, and laterally to oculomotor, trochlear and 1st and 2nd branches of the trigeminal nerve to enter the orbit

through the superior orbital fissure. The injury of the abducens nerve can occur anywhere along this long course, so differential diagnosis of ANP occasionally demands thorough investigation to find the proper cause.

Case Report Patient is a 69-year-old man who complained of intermittent headache without vomiting but with double vision since a couple months ago. The frequency and intensity of headache increased gradually. There was no apparent fever noted throughout the course. Patient has a history of hypertension with treatment at a local clinic. He has no history of diabetes mellitus. After admission, the neurological examination showed left abducens nerve palsy only. The magnetic resonance imaging (MRI) with gadolinium showed abnormal signal enhancement at the left sphenoid sinus in T1- weighted and T2- weighted images. Endoscopic sinus surgery (ESS) was done by the Otolaryngologist. The pathologic diagnosis was chronic paranasal sinusitis. The patient was discharged with improvement and stable condition although the left abducens palsy improved only partially.

Conclusion The incidence of ANP is 11.3/10000, with a peak in the seventh decade of life. Broadly, the causes of sixth nerve palsy have been studied before, namely in the population based study by Patel et al. The leading cause

was undetermined (26%), followed by hypertension alone (19%), coexistent hypertension and diabetes (12%), trauma (12%), multiple sclerosis (7%), neoplasm (5%), diabetes alone (4%), stroke (4%), post-neurosurgery (3%), aneurysm (2%) and others 8%. The role of ESS for prolonged abducens palsy resulting from isolated sphenoid sinus disease (ISSD) is still unclear. However, some published report pointed out that ESS is a safe and effective treatment for ISSD with abducens palsy.

195

缺血性腦中風病人之家屬拒絕或接受血栓溶解治療:倫理和法律探討

趙千淑 林綉紅 陳廷耀 張谷州 劉嘉為
陳偉熹

高雄長庚紀念醫院 神經內科系暨腦中風中心

Accept of Refusal of Thrombolysis by Family of Ischemic Stroke Patients: Ethical and Legal Issue

Chien-Shu Chao, Hsiu-Hung Lin, Teng-Yeow Tan, Ku-Chou Chang, Chia-Wei Liou, Wei-Hsi Chen

Department of Neurology and Stroke Center, Kaohsiung Chang Gung Memorial Hospital, and College of Medicine, Chang Gung University, Kaohsiung, Taiwan

Objective Thrombolysis is currently the golden standard for acute ischemic stroke. In clinical practice, patients may not be able to express their own will due to neurological disability. Family may take the responsibility for making decision. However, ethic and legal issue arise in this situation as the autonomy of patient is neglected.

Methods To review the ethical and legal issue for the autonomy of patient when family makes the decision for accept or refusal of thrombolysis instead of patient oneself.

Results Dispute has been encountered in both accept and refusal of thrombolysis by family instead of patient. In cases who received thrombolysis, family might challenge the physician with an underestimation of risk evaluated when adverse event occurred. On the other hand, family argued for a failure of administration of thrombolysis when neurological deterioration ensued afterwards. Both patient and family would plead for malpractice in these situation.

Conclusion In Taiwan, even competent elderly frequently hesitates for making decision that is finally made by adult son or daughter who is in scenario. The principle of autonomy and the principle of beneficence factually conflicts with each other or custom in the real word. Since the time window is narrow in thrombolysis, it is impossible to follow the rule as in the Hospice and Palliative Care Act. Therefore, it is necessary for engaging the inform-consent practice in our society.

196

短期安寧教學於預防醫學生耗竭之效果

賴明亮¹ 方俊凱² 李佩怡³

¹ 成功大學附設醫院神經內科

² 台北馬偕醫院 精神科

³ 國立台灣師範大學教育心理與輔導學系

The Effects of Short Palliative Course in Prevention of the Burnout among Medical Students.

Ming-Liang Lai¹, Chun-Kai Fan², Pei-Yi Lee³

¹ Department of Neurology, National Cheng Kung University, Tainan

² Department of Psychiatry, Ma Kay General Hospital, Taipei

³ Department of Educational Psychology, National Normal University, Taipei

Background Burnout is frequently encountered in the medical personnels, especially those in hospice service. Previous studies revealed that 4% to 18% medical students admitted that they had difficulties in adjustment during their learning period. Among them, after individual interview, 26% need psychiatric supports. (Saslow 1956) At Taiwan, one study revealed that suicide idea developed in 5.9% of medical students. (Lue et al 2006) The purpose of this study is to evaluate the present status of burnout in medical students and to find out whether a short term palliative course during the neurological rotation might helpful in the prevention of burnout in medical students.

Methods The burnout status was evaluated by the MBI-HSS Score proposed by the Maslach et al. The test has three subtests: exhaustion, depersonalization and diminished personal accomplishment. The intervention was a three-time course of lecture and discussion given in four weeks among the 6th grade medical

students: one hour with the topic of introduction, one hour of legal aspects, and one hour of ethic consideration in palliative medicine.

The sixth grade medical students in academic year 2010 and 2011 at Medical School, National Cheng Kung University joined this study. The project was approved by medical center IRB and every student signed the consent after detail explanation.

Results The medical students in two academic years did not differ in their score before the neurological rotation either in the total score or in the individual score of MBI. The results of all students were pooled to be compared with the scores before intervention. There were no difference in individual scores and total score. However, when compared with the second year (after neurological rotation plus hospice course), there was a significant improvement in individual score of exhaustion (23 ± 2.4 vs 25 ± 2.3 $p=0.030$). Yet the other two individual scores and total score of MBI did not differ.

Conclusion Short term course of hospice introduction during neurological rotation did improve the threshold of medical students to the prevention of burnout in the aspect of exhaustion. Whether this result is related to many life-threatening disease in neurological clinics should wait for further evaluation.

197

台灣的猝睡症盛行率以及發生率

謝正芳 徐崇堯

高雄醫學大學附設中和紀念醫院 神經內科

Narcolepsy Prevalence and Incidence in Taiwan

Cheng-Fang Hsieh, Chung-Yao Hsu

Department of Neurology, Kaohsiung Medical University Hospital, Kaohsiung, Taiwan

Background There are no nationwide surveys of narcolepsy in prevalence and incidence in Taiwan.

Objective To investigate the prevalence and incidence of narcolepsy in Taiwan

Methods We used National Health Research Institutes (NHRI) database to investigate the prevalence and incidence of narcolepsy in Taiwan. We defined patients to have probable narcolepsy if they had a diagnosis of narcolepsy (ICD-9CM code 347). We defined patients to have definitive narcolepsy if they had a diagnosis of narcolepsy and also applied for Modafinil (Provigil®).

Results Probable narcolepsy prevalence and incidence increased from 2007 to 2009. The prevalence of probable narcolepsy was 0.18, 0.23 and 0.38 per 10,000 persons per year in 2007, 2008 and 2009 respectively. The incidence of probable narcolepsy was 1.21, 1.52, and 2.54 per 100,000 persons per year in 2007, 2008 and 2009 respectively. Definitive narcolepsy prevalence increased from

2007 to 2009 but the incidence was nearly stationary. The prevalence of definitive narcolepsy was 0.06, 0.09 and 0.11 per 10,000 persons per year in 2007, 2008 and 2009 respectively. The incidence of definitive narcolepsy was 0.3, 0.3, and 0.2 per 100,000 persons per year in 2007, 2008 and 2009 respectively.

Conclusion Our survey showed that the prevalence of narcolepsy in Taiwan was not as high as that in Hong-Kong Chinese. Underdiagnoses or geographical difference may be the possible reasons.

198

醫療鑑定與醫療糾紛案件判決結果的相關性研究—台北經驗

羅揚清¹ 羅雪舫² 林蓓珍³ 張景翔⁴
¹台北榮民總醫院神經醫學中心神經內科專科醫師
²法務部司法官訓練所 學習司法官
³立暘律師事務所執業律師
⁴臺灣板橋地方法院法官

A Correlation Study on Medicine Authentication and Medical Controversy - Taipei Experience

Lo Yang-Ching, Lo Hsueh-Fang, Lin Pei-Chen, Chang Ching-Hsiang
 Neurological Institute, Taipei - Veterans General Hospital; Judges and Prosecutors Training Institute, Ministry of Justice; Li-Yang Law Office, Taiwan Banciao District Court

目標 近年醫療糾紛事件頻傳，在媒體渲染報導下，導致醫病關係緊張，亦使醫事人員對於法院所為醫糾案件判決結果有所質疑；然而，是否違反醫療常規及注意義務，法院係委託由醫事審議委員會(以下簡稱醫審會)鑑定；醫審會之鑑定報告與法院判決結果是否相關，及醫審會審議及決定過程中，醫、病雙方

之參與程度，均值思考。茲以台北地區醫糾刑事案件為素材，研究醫審會鑑定報告與判決結果之相關性。

方法 進入司法院網站法學資料檢索系統(網址：<http://jirs.judicial.gov.tw/Index.htm>)，點選「查詢裁判書」，勾選「刑事」類別，時間限定為民國88年1月1日至101年12月10日，以「醫事審議」為檢索詞，搜尋士林、台北及板橋等三地方法院之判決書，並排除以下條件之判決書：不受理判決、判決理由無交代醫審會鑑定報告內容者、案由欄非「業務過失傷害」或「業務過失致死」。其次，若一判決中有兩名以上被告獲得不同判決結果，則當兩件計算，並分別檢視醫審會分別鑑定各被告之報告結果。最末，將有罪及無罪判決分別與醫審會鑑定報告(分為「有疏失」、「無疏失或無因果關係」及「無法判斷或僅提供醫療知識」三種)，以統計軟體SPSS 19版作卡方檢定(Chi-square test)以檢視兩者是否相關。

結果 整理得94件判決，列表如下：

醫審會鑑定報告	判決有罪 (%)	判決無罪 (%)
認有疏失	18 (58%)	14 (22%)
認無疏失 / 無因果關係	7 (23%)	47 (75%)
無法判斷 / 僅提供醫療知識	6 (19%)	2 (3%)
總件數	31	63

P<0.05，醫審會鑑定報告與法院判決

結果有相關。其中醫審會鑑定報告認無疏失或無因果關係的部分，共有 4 件被挑別處置過程有瑕疵。

結論 醫審會鑑定報告為台北、士林、板橋等三地院審理醫療糾紛之重要參考。因此，在鑑定過程中，應考慮讓醫事人員作充分陳述，包含當下環境、人力調度、資源供給、病患狀況或特殊體質問題；又，經醫審會鑑定後，認醫方有疏失，法院非必然以刑責相繩，仍須由法院判斷該疏失與病患之損害，是否具法律上之相當因果關係。希冀本研究能促進醫療鑑定過程更加細緻化，建立醫、法、病三方之溝通平台，並開創三贏之未來。

199

以棋盤狀圖形於視覺障礙兒童進行知覺訓練的知覺可塑性之探討

蘇裕欽¹ 蔡麗婷² 徐榮隆^{3,4,5} 吳建德²

¹慈濟綜合醫院台北院區神經內科

²台灣大學職能治療所

³新光醫院神經內科

⁴台灣大學醫學工程學研究所

⁵臺北醫學大學醫學資訊研究所

Perceptual Plasticity of Checkered Pattern Perceptual Learning Program in Children with Visual Impairment

Yuh-Chin Su¹, Li-Ting Tsai², Jung-Lung Hsu^{3,4,5}, Chien-Te Wu²

¹Department of Neurology, Buddhist Tzu Chi Hospital, Taipei.

²School of Occupational Therapy, College of Medicine, National Taiwan University.

³Department of Neurology, Shin Kong Wu Ho-Su Memorial Hospital.

⁴Institute of Biomedical Engineering, National Taiwan University.

⁵Graduate Institute of Biomedical Informatics, Taipei Medical University, Taipei, Taiwan

研究目的 本研究以棋盤狀圖形為主要視覺刺激，探討視障兒童視覺知覺訓練之療效。

背景 視覺障礙影響兒童多方面的發展，因此早期的視覺訓練是兒童視覺復健領域重要的議題。然而目前對於視障兒童之視覺訓練仍少有具體和有效的治療策略，使得這類兒童無法於視覺發展關鍵期獲得適當刺激。

方法 使用電腦化視覺訓練軟體，依據視障兒童的視覺功能，調整棋盤狀圖案的大小、閃爍頻率和對比，進行 8 次、每週 2 次、每次 1 小時的視知覺訓練。兒童需持續注視黑白棋盤，當其他有趣的視覺目標物出現時，需按鍵做反應。同時會有聽覺回饋，以增加兒童之注意力。療效評估工具包括 Lea Symbols Visual Acuity Test、Tellar Visual Acuity Cards、功能性視覺問卷和 256 高頻道腦波儀。

結果 6 名(平均年齡 3.7 歲)視覺路徑前段或後段受損之視障兒童參與本研究，其中 4 位完成完整腦波檢查。視障兒童在視覺訓練 4 週後的平均視力，從 0.22 進步到 0.38 (p-value <0.05)。功能性視覺問卷顯示，兒童訓練前後有功能上顯著的差異 (p-value <0.05)。腦波檢查顯示，P100 波形及延遲時間亦有明顯改善。根據此研究結果，以棋盤狀圖案為主的電腦化視覺訓練軟體，不論在行為及電生理檢查上，均顯示可顯著改善視障兒童的視覺功能。

200

Wernicke 氏腦病變併中樞神經性過度換氣：一病例報告

蘇裕翔 許永居

嘉義基督教醫院 神經科

Central neurogenic hyperventilation in Wernicke's encephalopathy: A case report

Yu-Hsiang Su, Yung-Chu Hsu
Division of Neurology, Department of Internal
Medicine, Chia-Yi Christian Hospital

Background Most reported cases of central neurogenic hyperventilation result from pontine astrocytoma or lymphoma. We reported a case of Wernicke's encephalopathy presenting as central neurogenic hyperventilation.

Case Report A 54-year-old man came to our emergent department due to acute onset of tachypnea, double vision, and generalized numbness after waking up. He used to drink daily for many years and his body mass index was only 18. He also had cirrhosis without any treatment. He was clear, oriented, and afebrile. Neurological examination demonstrated bilateral partial ptosis, symmetric pupil size and intact light reflex, and there was no obvious dysconjugation and nystagmus, but he subjectively complained of persistent bi-ocular diplopia. There was no facial palsy, tongue deviation, or limbs weakness. His deep tendon reflexes were symmetrically increased. He also had bilateral dysmetria and symmetric distal limbs paresthesia on pinprick. The initial blood gas showed severe respiratory alkalosis. Because of persistent hyperventilation and respiratory alkalosis, he underwent intubation. Nutritional supplement including intravenous thiamine was soon administered. Cerebrospinal fluid study

showed neither pleocytosis nor increased protein. Brain MRI with gadolinium enhancement showed symmetric bilateral hyperintense lesions at periaqueductal areas of midbrain, dorsal pons, medulla and mammillary bodies on T2WI and FLAIR, which highly suggested Wernicke's encephalopathy. Five days later, he received extubation with alert consciousness, and all his symptoms including dyspnea, diplopia, and ataxia got completely recovered.

Conclusion Our patient emphasizes that Wernicke's encephalopathy involving periaqueductal brainstem could also cause central neurogenic hyperventilation.

201

數學學習能力障礙以 SPECT 檢測雙側顳葉灌注不足來表現

林祐薇¹ 蔡景仁²

¹ 楊錦標神經科診所

² 成功大學附設醫院神經科

Mathematical learning disability with mild bi-temporal hypoperfusion in SPECT study

Yu-Wei Lin¹ Jin-Jen Tsai²

¹ Dr. Yang's Neurology Clinic

² Department of Neurology, National
Chen-Kung University Hospital

Background Mathematical learning disability is one of the learning disabilities of human beings. Previous studies showed that the causes are variable, from inherited to acquired type (ex. Gerstmann syndrome). We here describe a patient with solitary

mathematical learning disability had mild bi-temporal hypoperfusion by SPECT study.

Case Report A 27-year old postgraduate male student was suggested to visit neurology OPD by his teacher because of "poor performance in mathematics". According to his mother and his teacher, the patient had "calculation disability" since childhood. He failed in almost all mathematic examination. His daily activities were normal, and he had no problems in learning other subjects. Actually, he got high score in biology, and was able to major in Immunology in NCKU. He was also good in learning drawing, and his teacher said he's excellent in using colors. We arranged series of PE, NE, serum biochemistry profiles, thyroid profiles, autoimmune profiles, CSF studies, and brain MRI studies, while all findings were normal. The neuropsychological assessment (including CASI, WAIS, WMS tests) suggested impairment in "processing speed", "auditory immediate recall", "auditory reception delayed score", and "working memory"; but excellent in "visual immediate recall" and "visual delayed memory". The HMPAO SPECT study revealed "relatively hypoperfusion over bilateral frontal and temporal areas".

Conclusion Bi-temporal lobes dysfunction can present as solitary mathematical learning disability without

other cognitive impairment. Deficits in "Auditory immediate recall", "Working memory", and "Speed of processing" contribute to math cognition disorders in this patient. Excellent visual memory and drawing ability may be the compensation consequence