

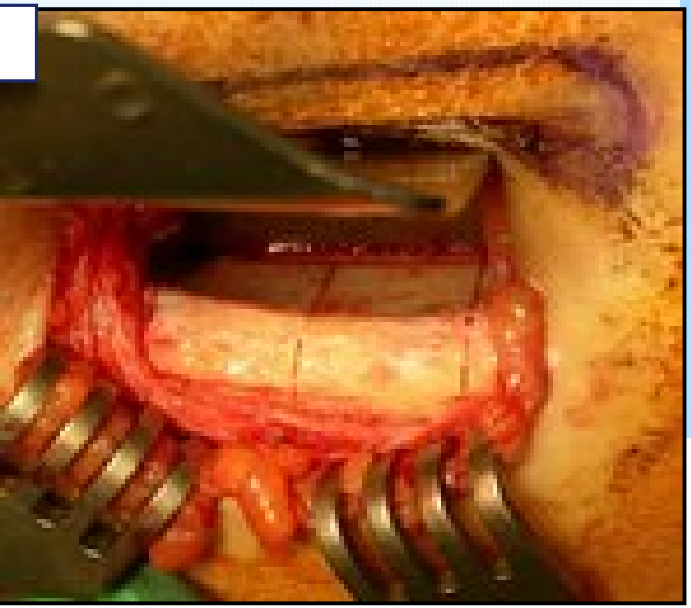
All patients accepted the bone  
 orir  
 tie  
 on.  
 ellous bone from the iliac bone,  
 y-bone reconstruction.  
 medical history was reviewed. In  
 en to exclude patients with iliac  
 ore undergoing alveolar bone  
 radiographic guide to be used  
 (CT) scan. The CT scan allows  
 of bone blocks needed for jaw-



Your complimentary  
 use period has ended.  
 Thank you for using  
 PDF Complete.

[Click Here to upgrade to  
 Unlimited Pages and Expanded Features](#)

**or site (Figure 1 a-f)**



was made 2 cm lateral to the  
 behind the anterior superior iliac  
 us branch of the iliohypogastric  
 nerve. (b) Microsaws were used  
 e of bone blocks from the donor

**recipient site (Figure 2a-f )**

dentist implant surgery was carried  
 after reconstructive surgery, and  
 been implanted in the recipient  
 record, we showed the treatment  
 images small bone graft volume  
 graft was still distinguishable, and  
 immobilizing the bone block was  
 ilium bone block.

