

Successful Intervention With Rotablation in PAOD with CTO of Infra-geniculate Artery

Department of Medicine, Section of Cardiology,
China Medical University Hospital, Taiwan
Chung-Ho Hsu, Ping-Han Lo, Kuan-Cheng Chang,
Jui-Sung Hung

2012/4/26

Chung Ho Hsu

CMUH



History

- 77 y/o woman
- HTN, DM, ESRD on regular dialysis, PAOD
- Poorly healed right leg wound for 6 months, ABI 0.72, right leg pulse Fem 2 pop 2 PTA 0 PDA 0



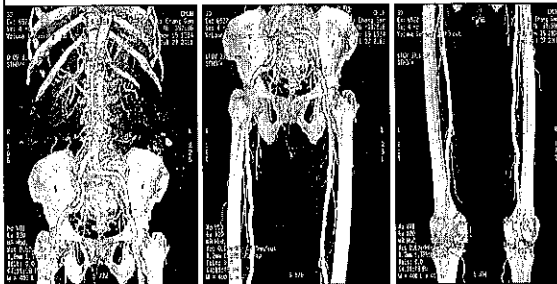
2012/4/26

Chung Ho Hsu

CMUH



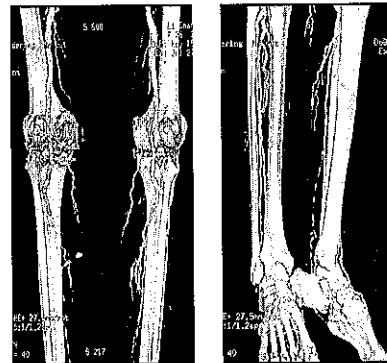
Leg CTA



2012/4/26

Chung Ho Hsu

CMUH




2012/4/26

CMUH



Ultrasound




RCFA: 100 cm/s RSFA: 100 cm/s RPOP: 61 cm/s

2012/4/26

CMUH



Ultrasound



RPTA: 0 cm/s

R PDA: trace flow

2012/4/26


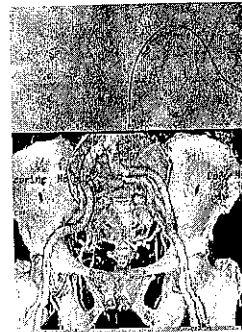
CMUH



1st PTA

2012/4/26


CMUH



6Fr Cook Crossover sheath, .035" Roadrunner wire

2012/4/26

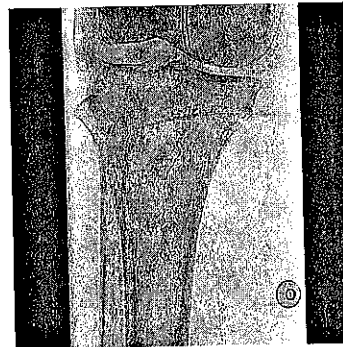
CMUH



Miracle 6 gram wire 2.0/80 Amphiron deep 2.0/20 Sprinter

2012/4/26

CMUH



2012/4/26

CMUH

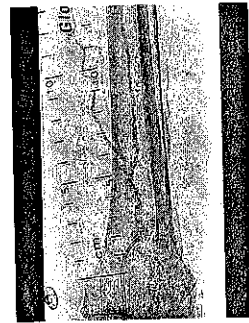



2nd PTA

Antegrade Approach

2012/4/26

CMUH

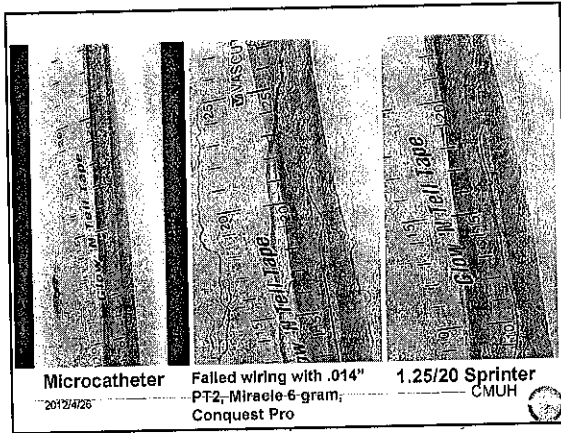


6 Fr Sheath Antegradely 6 Fr RESS Guiding Catheter

2012/4/26

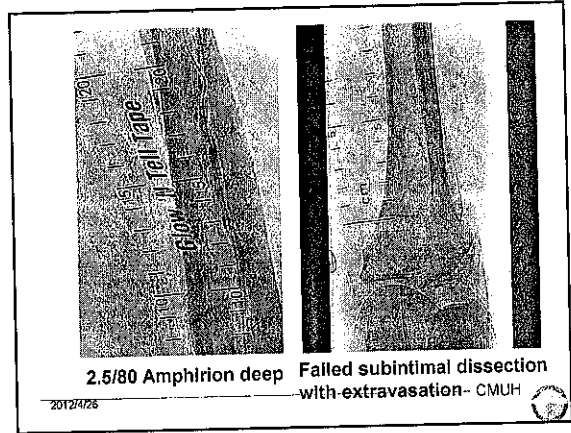
CMUH






Microcatheter Failed wiring with .014" 1.25/20 Sprinter
 PT2, Miracle 6 gram, Conquest Pro CMUH

2012/4/26



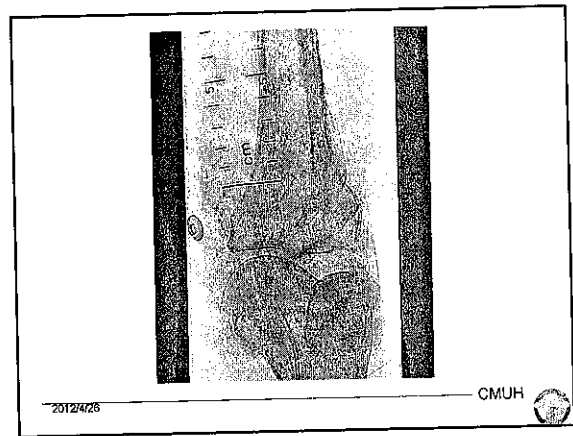
2.5/80 Amphirion deep Failed subintimal dissection
 with extravasation- CMUH

2012/4/26



2.0/150-Amphirion-deep Failed wiring— CMUH

2012/4/26



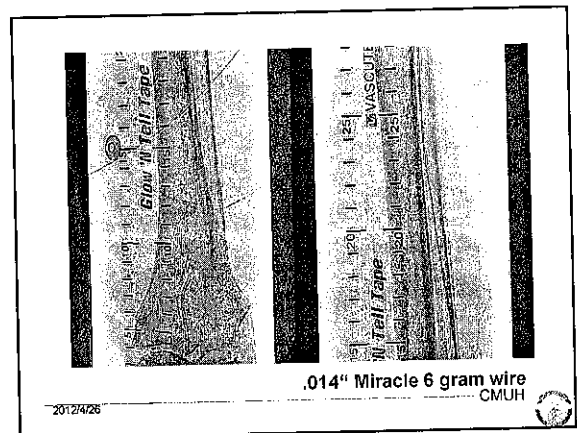
CMUH

2012/4/26

We never give up.....
3rd PTA

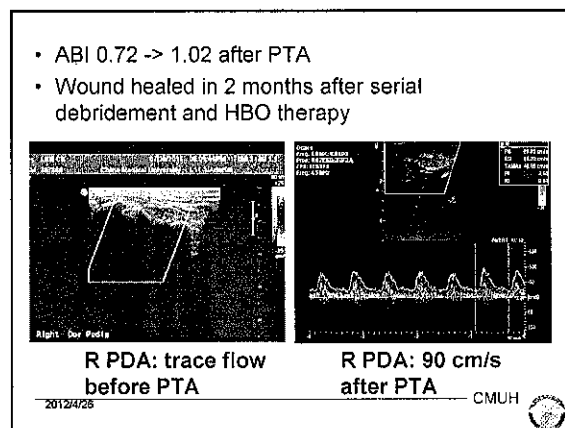
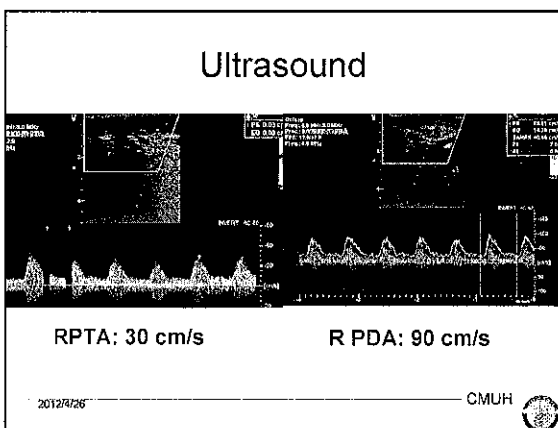

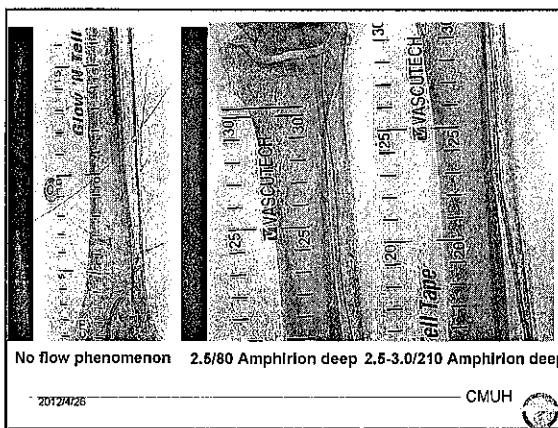

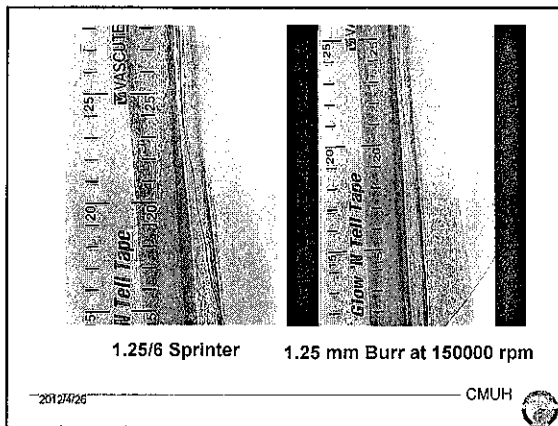
2012/4/26

CMUH



.014" Miracle 6 gram wire
 CMUH

2012/4/26



Conclusion

- Revascularization is mandatory for critical limb ischemia
- Standard treatments include balloon angioplasty and stent assisted angioplasty
- However, when undilatable or uncrossable calcified lesion was encountered, rotablation would be one of the way to solve this problem.

CMUH



Thanks for your attention

2012/4/26

CMUH

