



ELSEVIER

Available online at www.sciencedirect.com

SciVerse ScienceDirect

Journal of the Chinese Medical Association 75 (2012) 190–193

www.jcma-online.com

Case Report

Persistent cloaca presenting with a perineal cyst: Prenatal ultrasound and magnetic resonance imaging findings

Chih-Ping Chen^{a,b,c,d,e,f,*}, Tung-Yao Chang^g, Chin-Yuan Hsu^a, Yu-Peng Liu^{h,i}, Fuu-Jen Tsai^{d,j},
Pei-Chen Wu^a, Wayseen Wang^{b,k}

^aDepartment of Obstetrics and Gynecology, Mackay Memorial Hospital, Taipei, Taiwan, ROC

^bDepartment of Medical Research, Mackay Memorial Hospital, Taipei, Taiwan, ROC

^cDepartment of Biotechnology, Asia University, Taichung, Taiwan, ROC

^dSchool of Chinese Medicine, College of Chinese Medicine, China Medical University, Taichung, Taiwan, ROC

^eInstitute of Clinical and Community Health Nursing, National Yang-Ming University, Taipei, Taiwan, ROC

^fDepartment of Medicine, Mackay Medical College, New Taipei City, Taiwan, ROC

^gTaiji Fetal Medicine Center, Taipei, Taiwan, ROC

^hDepartment of Radiology, Mackay Memorial Hospital Hsinchu Branch, Hsinchu, Taiwan, ROC

ⁱMackay Medicine, Nursing and Management College, Taipei, Taiwan, ROC

^jDepartments of Medical Genetics, and Medical Research, China Medical University Hospital, Taichung, Taiwan, ROC

^kDepartment of Bioengineering, Tatung University, Taipei, Taiwan, ROC

Received March 11, 2011; accepted May 23, 2011

Abstract

A 40-year-old, primigravid woman presented at 23 weeks of gestation for evaluation of an extra-abdominal echogenic cystic mass of the fetus. Amniocentesis revealed a karyotype of 46,XX. Prenatal ultrasound showed a two-vessel umbilical cord, hydrocolpos, and distended bladder, urethra, and colon, and a perineal cystic mass. The kidneys and amniotic fluid amount were normal. Fetal magnetic resonance imaging revealed ascites, hydrocolpos, distended urinary bladder and colon, high rectum, and a perineal cyst. The fetus postnatally manifested persistent cloaca. The perineum was distended and smooth, without patent anal, vaginal, and urethral openings. The external genitalia were ambiguous with no labia majora, labia minora, or clitoris. The perineal cyst had a very small single orifice. We suggest that cloacal anomalies be considered in any female fetus with hydrocolpos, distended bladder and colon, ascites, and a perineal cyst.

Copyright © 2012 Elsevier Taiwan LLC and the Chinese Medical Association. All rights reserved.

Keywords: MRI; perineal cyst; persistent cloaca; prenatal diagnosis; ultrasound

1. Introduction

A persistent cloaca results from a failure of the normal development of the urorectal septum that divides the cloaca into urogenital sinus and anorectal canal.¹ In patients with a persistent cloaca, the urethra, vaginal, and intestinal tracts converge into a common outflow structure of cloaca.¹ Persistent cloaca

has been classified into the urethral type and the vaginal type.² In the urethral type of persistent cloaca, the perineal opening is continuous with the urethra, whereas in the vaginal type, the perineal opening is continuous with the vagina.² In this report, we present the prenatal ultrasound and magnetic resonance imaging (MRI) findings of persistent cloaca with a perineal cyst.

2. Case report

A 40-year-old, primigravid woman presented at 23 weeks of gestation for evaluation of an extra-abdominal echogenic

* Corresponding author. Dr. Chih-Ping Chen, Department of Obstetrics and Gynecology, Mackay Memorial Hospital, 92, Section 2, Chung-Shan North Road, Taipei 104, Taiwan, ROC.

E-mail address: cpc_mmh@yahoo.com (C.-P. Chen).

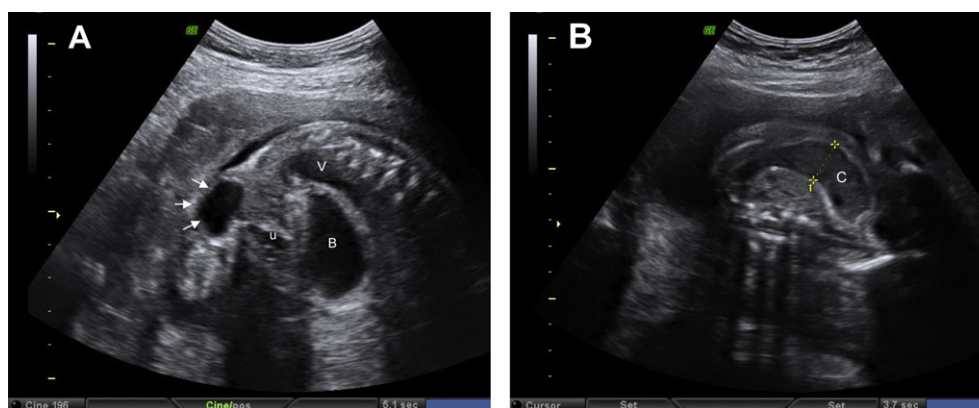


Fig. 1. Prenatal ultrasound at 23 weeks of gestation shows (A) dilated bladder, vagina, and urethra, and cystic distal cloacal channel (arrows), and (B) a dilated distal colon. B = bladder; C = colon; U = urethra; V = vagina.

cystic mass of the fetus. The woman and her husband were healthy and nonconsanguineous, and there was no family history of congenital anomaly. She did not undergo any assisted reproductive technology for this pregnancy. Amniocentesis performed in the second trimester revealed a karyotype of 46,XX. Prenatal ultrasound showed a two-vessel umbilical cord, hydrocolpos, distended bladder, urethra, and colon, and a perineal cystic mass (Fig. 1). The kidneys and amniotic fluid amount were normal. At 24 weeks of gestation, ultrafast MRI revealed ascites, hydrocolpos, distended urinary bladder and colon, high rectum with the distal end at the bladder base, and a perineal cyst (Fig. 2). A diagnosis of persistent cloaca was made. The parents elected to terminate the pregnancy, and a macrosomic fetus weighing 1006 g (>99th centile) was delivered with ambiguous external genitalia, an imperforate anus, and a 2 × 2 cm perineal cystic mass. The perineum was distended and smooth without patent anal, vaginal, and urethral openings. The external genitalia were ambiguous with no labia majora, labia minora, or clitoris. The perineal cyst had a very small single orifice (Fig. 3). An autopsy was not granted by the parents.

3. Discussion

Persistent cloaca, cloacal malformation, or cloacal dysgenesis sequence, is a rare congenital anomaly that typically affects females and has an incidence of 1:50,000.¹ Persistent cloaca accounts for about 10% of all anorectal malformations in females.³ In birds and reptiles, persistent cloaca is normal. However, in humans, persistent cloaca is a complex malformation with a wide spectrum of severities and can be associated with vertebral, pulmonary, cardiac, and genitourinary tract abnormalities.⁴ In human embryos, the cloaca is a transient structure and is divided by 6 weeks of gestation, resulting in a urogenital sinus anteriorly and a separate hindgut posteriorly.⁴

Warne et al⁵ suggested that cloacal anomalies be considered prenatally in any female fetus with bilateral hydronephrosis, a poorly visualized bladder, and a cystic lesion arising from the pelvis. However, prenatal diagnosis of persistent cloaca is not

always easy. Prenatal diagnosis of anorectal malformations has been estimated to be 8.2–15.9%.^{6,7} In a study of 95 cases of persistent cloaca with prenatal ultrasound reports, Bischoff et al⁸ found that only six cases (6.3%) were correctly diagnosed. In 95 ultrasound reports with 270 described abnormalities, they found that the frequencies of observed abnormalities were as follows: abdominal/pelvic cystic mass (39/95 = 41.1%), hydronephrosis (36/95 = 37.9%), oligohydramnios (23/95 = 24.2%), distended bowel/bowel obstruction (19/95 = 20%), ascites (15/95 = 15.8%), two-vessel cord (14/95 = 14.7%), dilated bladder (14/95 = 14.7%), dilated ureter (14/95 = 14.7%), polyhydramnios (10/95 = 10.5%), echogenic bowel (8/95 = 8.4%), multicystic kidneys (8/95 = 8.4%), hydrop fetalis (7/95 = 7.4%), hydrocolpos (4/95 = 4.2%), absent kidney (3/95 = 3.2%), abnormal spine (3/95 = 3.2%), and anorectal atresia (3/95 = 3.2%). In this report, we present the prenatal ultrasound and MRI findings of a very unusual perineal cyst associated with persistent cloaca, hydrocolpos, distended bladder, urethra, and colon, high rectum, two-vessel cord, ambiguous external genitalia, and imperforate anus. Sahinoglu et al⁹ first described the prenatal findings of a perineal cyst associated with cloacal dysgenesis sequence. The perineal cyst is the malformed distal portion of the cloacal channel due to the obstruction at the external orifice. The present case was likely to have a common channel longer than 3 cm. Peña et al¹⁰ suggested that the length of the common channel is an important determinant of urinary continence and the extent of surgical repair. In a review of 339 patients with cloacal malformations, Peña et al¹⁰ found that patients with a common channel longer than 3 cm required complex operations, with an average number of 18 operations and a 28% possibility of urinary continence, whereas patients with a common channel shorter than 3 cm required simple operations, with an average number of nine operations and a 72% possibility of urinary continence.

Prenatal ultrasound diagnosis of cloacal anomalies is difficult because of highly variable image features. Fetal MRI has the advantage of facilitating the diagnosis of persistent cloaca by defining the anatomy of the cloaca, urogenital organs, and intestinal tracts, and has been recognized as a useful complementary tool to ultrasound.^{11–19} In this case, distal colon

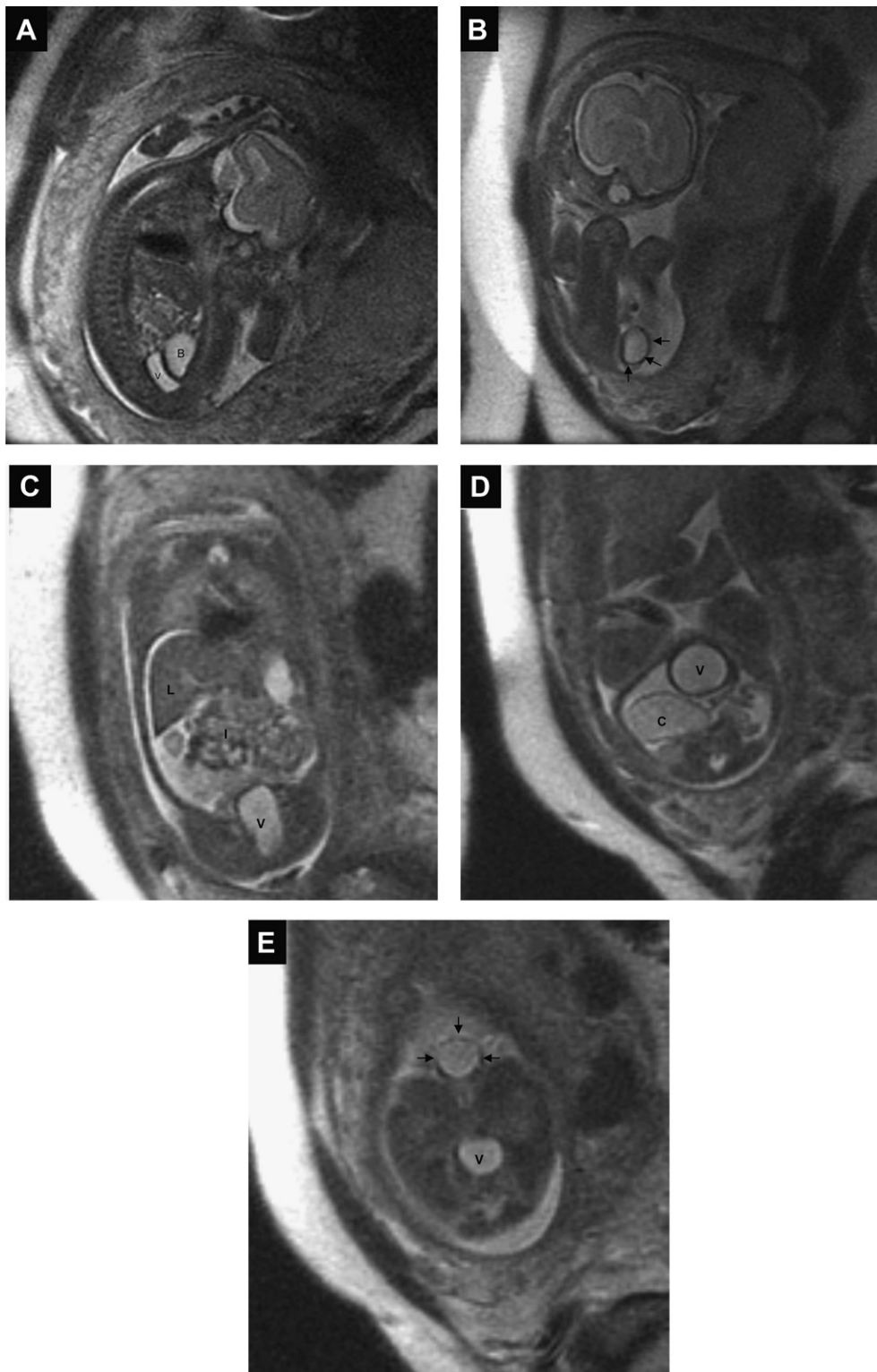


Fig. 2. Fetal magnetic resonance imaging at 24 weeks of gestation shows (A) dilated bladder and vagina (sagittal scan), (B) a perineal cyst (arrows) (coronal scan), (C) ascites and a dilated vagina (coronal scan), (D) dilated distal colon and vagina (axial scan), and (E) dilated vagina and a perineal cyst (arrows) (axial scan). B = bladder; C = colon; I = intestines; L = liver; V = vagina.

dilation, pelvic cystic masses, and a perineal cyst were evident on fetal MRI and ultrasound. The MRI findings in this presentation are in accordance with the conclusion suggested by Subramanian,¹⁵ that the rectal sign of distal colon dilation

caused by retained meconium on fetal MRI is an important imaging marker of cloacal anomalies. We suggest that cloacal anomalies be considered in any female fetus with distended bladder, vagina, and colon, ascites, and a perineal cyst.

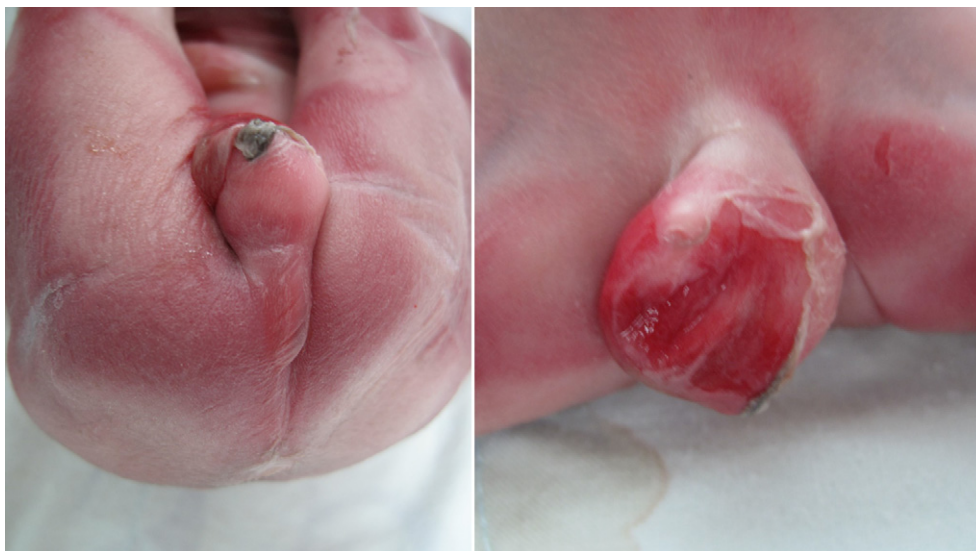

Fig. 3. An imperforate anus and a perineal cyst at birth.

Acknowledgments

This work was supported by research grants NSC-97-2314-B-195-006-MY3 and NSC-99-2628-B-195-001-MY3 from the National Science Council, and MMH-E-100-04 from Mackay Memorial Hospital, Taipei, Taiwan.

References

- Petrikovsky BM, Walzak Jr MP, D'Addario PF. Fetal cloacal anomalies: prenatal sonographic findings and differential diagnosis. *Obstet Gynecol* 1988;**72**:464–9.
- Jaramillo D, Lebowitz RL, Hendren WH. The cloacal malformation: radiologic findings and imaging recommendations. *Radiology* 1990;**177**:441–8.
- Peña A. The surgical management of persistent cloaca: results in 54 patients treated with a posterior sagittal approach. *J Pediatr Surg* 1989;**24**:590–8.
- Warne SA, Hiorns MP, Curry J, Mushtaq I. Understanding cloacal anomalies. *Arch Dis Child* 2011. doi:10.1136/adc.2009.175034.
- Warne S, Chitty LS, Wilcox DT. Prenatal diagnosis of cloacal anomalies. *BJU Int* 2002;**89**:78–81.
- Stoll C, Lembik Y, Dott B, Roth MP. Evaluation of prenatal diagnosis of congenital gastro-intestinal atresias. *Eur J Epidemiol* 1996;**12**:611–6.
- Brantberg A, Blaas HG, Haugen SE, Isaksen CV, Eik-Nes SH. Imperforate anus: a relatively common anomaly rarely diagnosed prenatally. *Ultrasound Obstet Gynecol* 2006;**28**:904–10.
- Bischoff A, Levitt MA, Lim FY, Guimarães C, Peña A. Prenatal diagnosis of cloacal malformations. *Pediatr Surg Int* 2010;**26**:1071–5.
- Sahinoglu Z, Mulayim B, Ozden S, Etker S, Celayir A, Ozkan F, et al. The prenatal diagnosis of cloacal dysgenesis sequence in six cases: can the termination of pregnancy always be the first choice? *Prenat Diagn* 2004;**24**:10–6.
- Peña A, Levitt MA, Hong A, Midulla P. Surgical management of cloacal malformations: a review of 339 patients. *J Pediatr Surg* 2004;**39**:470–9.
- Hayashi S, Sago H, Kashima K, Kitano Y, Kuroda T, Honna T, et al. Prenatal diagnosis of fetal hydrometrocolpos secondary to a cloacal anomaly by magnetic resonance imaging. *Ultrasound Obstet Gynecol* 2005;**26**:577–9.
- Cienciosi A, Mancini F, Busacchi P, Carletti A, de Aloysio D, Battaglia C. Increased amniotic fluid volume associated with cloacal and renal anomalies. *J Ultrasound Med* 2006;**25**:1085–90.
- Shono T, Taguchi T, Suita S, Nakanami N, Nakano H. Prenatal ultrasonographic and magnetic resonance imaging findings of congenital cloacal anomalies associated with meconium peritonitis. *J Pediatr Surg* 2007;**42**:681–4.
- Hung YH, Tsai CC, Ou CY, Cheng BH, Yu PC, Hsu TY. Late prenatal diagnosis of hydrometrocolpos secondary to a cloacal anomaly by abdominal ultrasonography with complementary magnetic resonance imaging. *Taiwan J Obstet Gynecol* 2008;**47**:79–83.
- Subramanian S. Importance of rectal signal on fetal magnetic resonance imaging in patients having hydrometrocolpos. *Taiwan J Obstet Gynecol* 2008;**47**:375.
- Liu YP, Chen CP. Fetal MRI of hydrometrocolpos with septate vagina and uterus didelphys as well as massive urinary ascites due to cloacal malformation. *Pediatr Radiol* 2009;**39**:877.
- Chen CP, Liu YP, Chang TY, Tsai FJ, Chen CY, Wu PC, et al. Prenatal diagnosis of persistent cloaca with hydrometrocolpos and ascites by magnetic resonance imaging in one fetus of a dizygotic twin pregnancy. *Taiwan J Obstet Gynecol* 2010;**49**:385–6.
- Gupta P, Kumar S, Sharma R, Gadodia A. Case report: antenatal MRI diagnosis of cloacal dysgenesis syndrome. *Indian J Radiol Imaging* 2010;**20**:143–6.
- Calvo-Garcia MA, Kline-Fath BM, Levitt MA, Lim FY, Linam LE, Patel MN, et al. Fetal MRI clues to diagnose cloacal malformations. *Pediatr Radiol* 2011;**41**:1117–8.