

# Infectious Alopecia in a Dog Breeder After Renal Transplantation

Cheng-Hsu Chen<sup>1,3,4</sup>, Mei-Chin Wen<sup>2</sup>, Chi-Hung Cheng<sup>1,3,5</sup>, Ming-Ju Wu<sup>1,5,6</sup>, Tung-Min Yu<sup>1</sup>,  
Ya-Wen Chuang<sup>1</sup>, Kuo-Hsiung Shu<sup>1,5\*</sup>

<sup>1</sup>Division of Nephrology, Department of Internal Medicine, and <sup>2</sup>Department of Pathology, Taichung Veterans General Hospital, <sup>3</sup>Department of Biotechnology, Hung Kuang University, <sup>4</sup>Department of Life Science, Tunghai University, <sup>5</sup>School of Medicine, Chung-Shan Medical University, Taichung, and <sup>6</sup>National Yang-Ming University School of Medicine, Taipei, Taiwan, R.O.C.

Tinea capitis rarely occurs in renal transplant recipients. We report this living-related renal transplant patient receiving cyclosporine-based therapy who initially presented with severe exfoliation of the scalp with yellowish-white scales and marked hair loss. The lesions extended to the frontal area and both cheeks, resulting in several skin ulcers with perifocal erythematous inflammatory changes, and palpable cervical lymph nodes. A biopsy of a skin lesion revealed fungal infection and culture yielded *Microsporum canis*. The patient mentioned an outbreak of ringworm in her breeding dogs during this period. After adequate treatment of the patient and her infected animals with griseofulvin and disinfection of the environment, her skin lesions resolved dramatically, with regrowth of hair. [*J Chin Med Assoc* 2008;71(9):477–480]

**Key Words:** *Microsporum canis*, renal transplant, tinea capitis, tinea faciei, zoophilic dermatophyte

## Introduction

Renal transplant recipients receiving immunosuppressive agents are at increased risk of developing malignancies, cardiovascular diseases and opportunistic infections,<sup>1,2</sup> but infectious alopecia caused by tinea capitis (TC) rarely occurs. Fungal infection is a major cause of infectious alopecia. Zoophilic dermatophytes are fungal organisms that primarily infect animals and can be transmitted to humans. *Microsporum canis* is the predominant pathogen that affects animals worldwide. It rarely infects human beings, but when it does, it will cause localized or widespread pustules or abscesses over the scalp with progressive hair loss which may extend to the face (tinea faciei) and can occur in association with cervical lymphadenopathy, frequently called “Kerion of Celci”.

We report a case of TC caused by *M. canis* infection in a renal transplant recipient who is a dog breeder. The lesion was successfully treated with griseofulvin for 8 weeks without any complications.

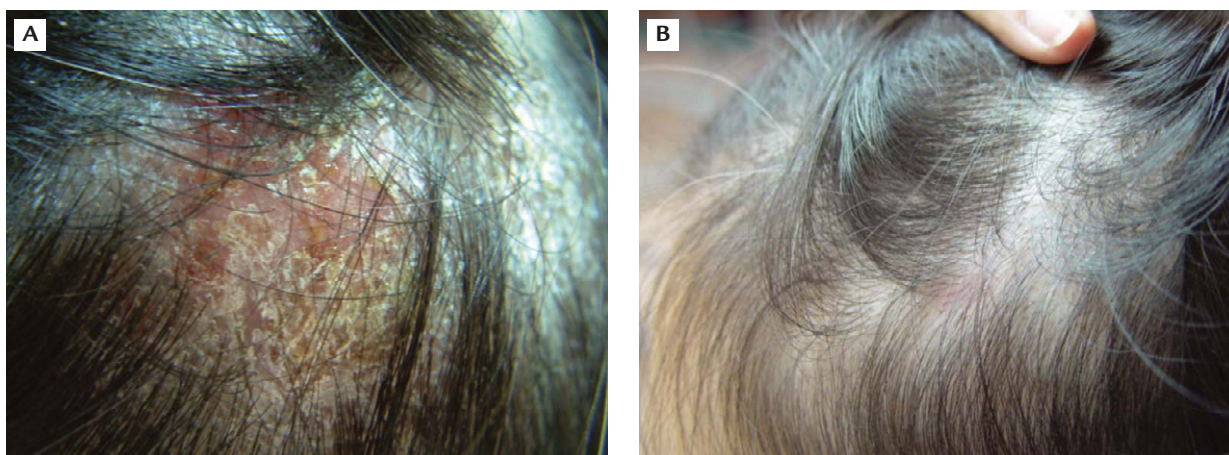
## Case Report

This 48-year-old female patient with a history of end-stage renal disease due to IgA nephropathy received a living-related renal transplantation from her mother in February 2001. She received cyclosporine 150 mg/day and mycophenolate mofetil 1 g/day but no corticosteroid. She did not experience any allograft rejection episodes, and her renal function was maintained at around 0.9 mg/dL. In February 2006, she complained of severe exfoliation of the scalp with marked hair loss on clothes and pillows, comb, and room floors. Topical ketoconazole (2%) shampoo (Nizoral shampoo<sup>®</sup>) was suggested, but symptoms deteriorated and resulted in several patches with yellowish-white scales over the whole scalp (Figure 1A). The lesions even extended to the frontal area and both cheeks, and there were several skin ulcers with perifocal erythematous inflammatory changes (Figure 2A), and palpable cervical lymph nodes. A complete blood count and liver function tests were normal. Direct examination with potassium

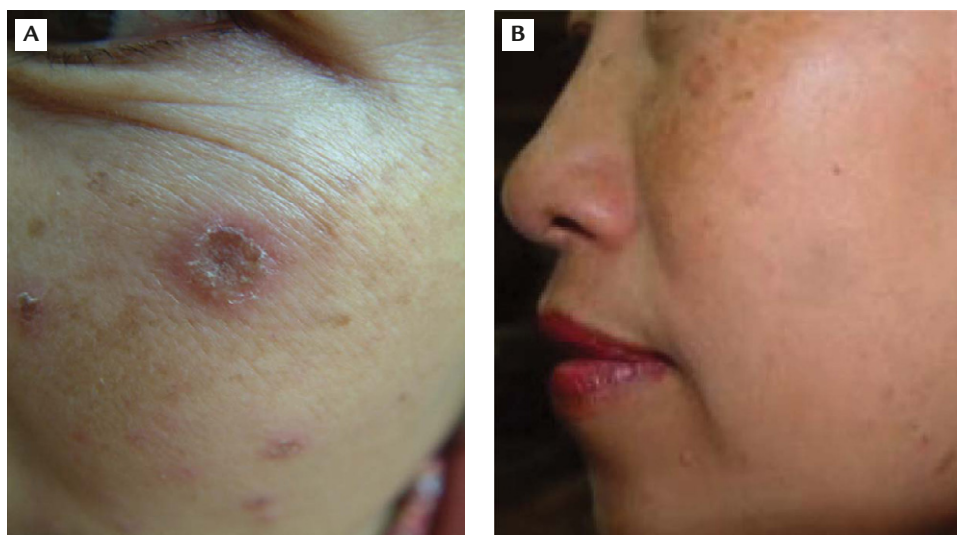


ELSEVIER

\*Correspondence to: Dr Kuo-Hsiung Shu, Division of Nephrology, Department of Internal Medicine, Taichung Veterans General Hospital, 160, Section 3, Chung-Kang Road, Taichung 407, Taiwan, R.O.C.  
E-mail: khshu@vghtc.gov.tw • Received: December 31, 2007 • Accepted: April 30, 2008



**Figure 1.** (A) Several patches with yellowish-white scales over the whole scalp were associated with marked hair loss. (B) Hair regrew after a 2-month complete therapy course with griseofulvin, although there was some focal permanent hair loss due to cicatricial changes of the scalp.



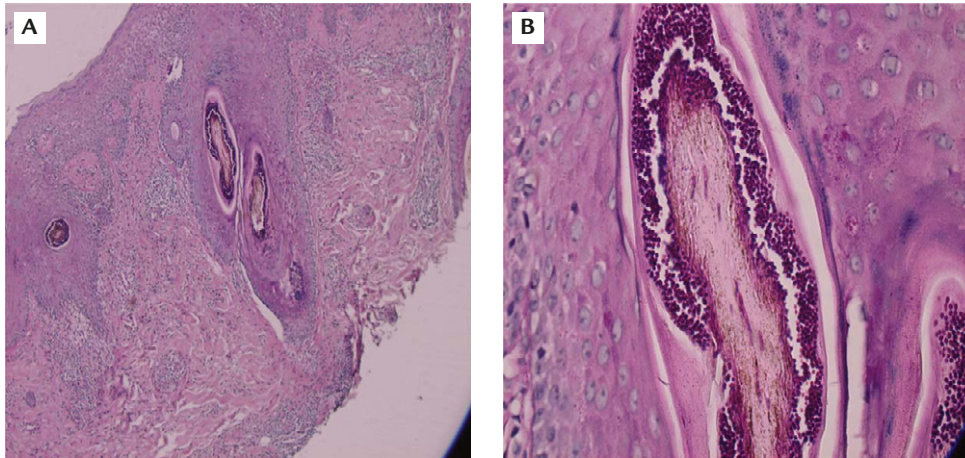
**Figure 2.** (A) Several skin ulcers can be seen with perifocal erythematous inflammatory changes over the frontal area and both cheeks. (B) Complete recovery of the skin ulcers.

hydroxide (KOH) was positive. Microscopic examination of the scalp biopsy disclosed numerous arthrospores within hair follicles causing an ectothrix infection, and the perifocal region, dermis, and epidermis were all infiltrated with a dense number of inflammatory cells consisting of a mixture of neutrophils, lymphocytes, histiocytes, plasma cells, and eosinophils (Figure 3A). The fungal elements were found mainly within the follicles and absent in the dermis (Figure 3B). The fungal culture of the specimen yielded *M. canis*. The patient received treatment with griseofulvin 1 g/day and topical ketoconazole shampoo. An outbreak of ringworm had occurred in her breeding dogs during the period of her onset of skin lesions. All the infected dogs were isolated and treated by a veterinarian. The whole environment

was disinfected to prevent reinfection. The skin ulcers and scaling of the scalp dramatically improved within 2 weeks and subsequently resolved, with hair regrowth 8 weeks later (Figures 1B and 2B), while fungal culture became negative. However, there was some cicatricial alopecia.

## Discussion

Dermatophytes are usually restricted to the nonliving cornified layer of the epidermis because of their inability to penetrate viable tissue of an immunocompetent host. The organisms colonize and obtain nutrients from the keratin tissues to cause infections of the skin,



**Figure 3.** (A) Numerous arthrospores (arrows) were found within the hair follicles causing an ectothrix infection, and the perifollicular region, dermis, and epidermis were all infiltrated with a dense number of inflammatory cells consisting of a mixture of neutrophils, lymphocytes, histiocytes, plasma cells, and eosinophils (PAS stain, original magnification 100 $\times$ ). (B) The fungal elements (arrows) were found primarily within the follicles and absent in the dermis in the scalp biopsy (PAS stain, original magnification 600 $\times$ ).

hair and nails. The chronic use of immunosuppressive agents impairs cell-mediated immunity within the skin. The epidermal Langerhans cells responsible for major defense against dermatophytes may be suppressed in such a situation. The defective or lack of cell-mediated immunity and persistent presence of pathogenic fungi in the host environment will predispose to invasion of the host by dermatophytes and elicit infection.

In the past 40 years, public health has improved significantly in Taiwan, and only sporadic cases of TC are reported. In the most recent report, *T. tonsurans* was the most common cause of TC in southern Taiwan;<sup>3</sup> it causes more than 95% of these infections in the United States.<sup>4</sup> Since *M. canis* is almost always reported in solid organ transplant patients, HIV-positive patients and autoimmune patients, it is believed that the infection is due to abnormal susceptibility of the host with depressed immune status, rather than to the virulence of the fungus.<sup>5</sup> There are 2 possible mechanisms whereby zoophilic dermatophytes cause more severe infection in humans than other anthropophilic species. Firstly, high levels of hydrolytic enzymes (keratinases) secreted by these organisms cause increased invasion.<sup>6</sup> Secondly, *M. canis* does not respond well to topical antifungal agents, which permits infections to persist. The low prevalence and atypical presentation of TC in adults require a high index of clinical awareness for diagnosis. Although we suggested topical antifungal shampoo to treat the scaling of the scalp initially, this patient remained exposed to the infected dogs and environment for 2 months. The lesions may extend to the face (tinea faciei) in association with “Kerion of Celci”. The destroyed hair follicles and replacement with scar tissue may cause permanent hair loss, and cicatricial alopecia

is inevitable. A delay in diagnosis sometimes leads to severe scarring and inappropriate invasive therapies, such as surgical excision of presumed abscesses or pseudotumor.<sup>7</sup>

Griseofulvin is a first-line, well-tolerated antifungal therapy. Following oral ingestion, it reaches the skin and hair and is deposited primarily in keratin precursor cells, rendering these cells resistant to fungal infections. Only 17% of TC patients are treated with griseofulvin for more than 6 weeks; the short duration of oral antifungal use implies poor compliance due to inconvenient dosage and duration.<sup>8</sup> Other clinical data suggest the intermittent use of itraconazole or terbinafine for treatment without any side effects or recurrence in immunocompromised patients,<sup>9</sup> and can improve patient quality of life and reduce interaction between antifungal drugs and immunosuppressive agents. Itraconazole showed favorable clinical and mycological responses following 1–4 weeks of therapy, but the curative rates were lower when the causative organism was *M. canis*.<sup>10</sup>

Our patient was treated with griseofulvin 1 g/day for 8 weeks. Meanwhile, the environment was thoroughly disinfected and the patient kept away from the infected animals. Her graft function remained stable. There was no appreciable drug interaction between griseofulvin and cyclosporine. In summary, this case highlights the possibility of a zoophilic dermatophyte in renal transplant patients who have intimate contact with infected animals. Early diagnosis followed by appropriate treatment, isolation and treatment of the infected animals and disinfection of the environment are cornerstones for successful management of this rare complication.

## References

1. Shu KH, Wu MJ, Chen CH, Cheng CH, Lian JD. Outcome of kidney transplantation using organs from executed prisoners: is it justified beyond the ethical issue? *J Chin Med Assoc* 2007;70:193-9.
2. Kao YL, Yang CR, Chen CH. Urinary excretion on a renal transplant recipient with multifocal urothelial cancers and prostatic adenocarcinoma. *J Chin Med Assoc* 2004;67:422-4.
3. Chao SC, Hsu MM. *Trichophyton tonsurans* infection in Tainan area. *J Formos Med Assoc* 1994;93:697-701.
4. Foster KW, Ghannoum MA, Elewski BE. Epidemiologic surveillance of cutaneous fungal infection in the United States from 1999 to 2002. *J Am Acad Dermatol* 2004;50:748-52.
5. Piraccini BM, Morelli R, Stinchi C, Tosti A. Proximal subungual onychomycosis due to *Microsporum canis*. *Br J Dermatol* 1996;134:175-7.
6. Odom R. Pathophysiology of dermatophyte infections. *J Am Acad Dermatol* 1993;28:2-7.
7. Awasthi A, Nada R, Gupta S, Sakhuja V, Joshi K. An unusual cause of skin "tumours" in a renal transplant recipient. *Eur J Dermatol* 2005;15:401-3.
8. Suh DC, Friedlander SF, Raut M, Chang J, Vo L, Shin HC, Tavakkol A. Tinea capitis in the United States: diagnosis, treatment, and costs. *J Am Acad Dermatol* 2006;55:1111-2.
9. Romano C, Paccagnini E, Pelliccia L. Case report. Onychomycosis due to *Microsporum canis*. *Mycoses* 2001;44:119-20.
10. Ginter-Hanselmayer G, Smolle J, Gupta A. Itraconazole in the treatment of tinea capitis caused by *Microsporum canis*: experience in a large cohort. *Pediatr Dermatol* 2004;21:499-502.