

# Gustatory changes in patients with chronic otitis media, before and after middle-ear surgery

C-C HUANG<sup>1</sup>, C-D LIN<sup>1</sup>, C-Y WANG<sup>1</sup>, J-H CHEN<sup>2</sup>, Y-T SHIAO<sup>2</sup>, M-H TSAI<sup>1</sup>

<sup>1</sup>Department of Otolaryngology, China Medical University Hospital and <sup>2</sup>Biostatistics Center, China Medical University, Taiwan

## Abstract

**Objective:** We investigated gustatory changes in patients with chronic otitis media, before and after middle-ear surgery.

**Methods:** This prospective study included 38 patients with unilateral chronic otitis media. We used taste testing solutions to evaluate each patient's taste function. Intra-operative assessments of the chorda tympani nerve were also compared and analysed.

**Results:** Patients with chronic otitis media had significantly worse ipsilateral perception of sour, bitter and salty tastes. In patients with good intra-operative preservation of the chorda tympani nerve, there was significant improvement in gustatory function one month post-operatively, compared with the pre-operative baseline. In patients who sustained intra-operative chorda tympani nerve injury, one month post-operative gustatory function was the same as the pre-operative baseline.

**Conclusion:** Middle-ear surgery for chronic otitis media not only treats the ear but also improves gustatory function in the majority of patients. In patients with intra-operative injury to the chorda tympani nerve, post-operative taste decline is only temporary.

**Key words:** Taste; Otitis Media; Hypogeusia; Ear, Middle; Chorda Tympani Nerve; Tympanoplasty

## Introduction

The chorda tympani nerve carries taste fibres to the anterior two-thirds of the tongue on the ipsilateral side. Surgeons are often required to handle or manipulate this nerve during middle-ear surgery, and as a result iatrogenic or pathological nerve injury is difficult to completely avoid.<sup>1</sup> Patients with chronic middle-ear inflammation can also experience a decline in gustatory function due to the disease itself.

Little is known about changes in gustatory function in patients who undergo surgical extirpation of diseased middle-ear tissue, as studies in this field are lacking.

The objective of our study was to investigate taste changes in patients with chronic otitis media, both before and after middle-ear surgery. Such information may be of great benefit to surgeons when explaining operations to patients, and when forecasting outcomes should complications develop.

## Materials and methods

This was a prospective study that included patients with unilateral chronic otitis media with and without cholesteatoma who received middle-ear surgery for the first

time at the China Medical University Hospital, Taiwan (a tertiary referral centre).

We excluded patients with the following conditions: pregnancy, dysosmia, a history of salivary gland surgery or head and neck radiotherapy, active upper airway inflammatory disorders, craniofacial abnormality, cognition barrier, and those unable to give consent by themselves.

Diagnosis was made based on intra-operative findings, computed tomography mastoid scans and histopathology results.

Each patient underwent detailed history-taking, a systemic and otorhinolaryngological physical examination, and gustatory testing, before their operation.

Four kinds of taste testing solutions were prepared, with three degrees of concentration, as follows: sour (citric acid at 0.01, 0.05 and 0.25 g/ml), bitter (quinine hydrochloride at 0.0001, 0.0005 and 0.0025 g/ml), sweet (sucrose at 0.01, 0.05 and 0.25 g/ml) and salty (sodium chloride at 0.005, 0.025 and 0.125 g/ml). The lowest concentration of each taste type could be identified correctly by more than half of the healthy subjects, and the highest concentrations could be identified correctly by all of the subjects.<sup>2,3</sup>

Every patient who participated in this study provided informed consent. The study design was approved by the institutional review board of the hospital (approval number DMR99-IRB-092).

Patients participating in this study were prohibited from taking food or drink, except for water, for one hour before participating in the gustatory test. They were instructed to gargle and rinse their mouth with clean water and to swallow their first mouthful of saliva just before starting the test.

We tested the four taste testing solutions (sour, bitter, sweet and salty) on the anterior tongue bilaterally. The test was conducted randomly with regards to the type of taste, but always proceeding from a low to high concentration and from the affected side to the healthy side. The testing site of each tongue was touched lightly for 3 seconds with cotton sticks that had been soaked in the taste testing solution. We requested examinees to maintain an open mouth and to protrude their tongue, reducing upper jaw contamination which may cause identification error. Patients were instructed to rinse their mouth after each test solution. We also provided identification cards to patients so that they could indicate whether they had experienced a sour, bitter, sweet or salty taste, or were unsure. Finally, we recorded a score to indicate when each patient had recognised a taste testing solution correctly. Scores for successful identification were as follows: 1 for the lowest concentration of taste solution, 2 for the intermediate concentration, 3 for the highest concentration, and 4 for inability to identify the taste.

All patients underwent gustatory testing four times: before the operation and two days, one week and one month after the operation.

The patients' gustatory test results and intra-operative findings (focusing on the state of the chorda

tympani nerve) were compared and analysed. The cumulative logit model was used to analyse the association between the degree of taste and the surgical intervention at different time points. The statistical significance level was set at 0.05. Statistical analysis was performed using the SAS version 9.2 software package.

## Results

Thirty-eight patients with unilateral chronic otitis media were recruited, comprising 10 males and 28 females, with a mean age of 47.5 years.

There were eight patients with cholesteatoma and 30 without. Nine patients had a stretched chorda tympani nerve and four had a severed chorda tympani nerve, as observed during middle-ear surgery. Two cases with nerve division were due to variable anatomy, while a further two cases were because the nerves were embedded in granulation or cholesteatoma and had to be sacrificed (Table I).

Table II shows results for comparing taste test scores on the affected versus healthy sides of the tongue, for patients with and without cholesteatoma, before surgery. An odds ratio was calculated to express the ratio of the mean taste scores for the healthy versus affected tongue side. An odds ratio of 1 indicated that the taste sensitivity of the affected side was equal to that of the healthy side, an odds ratio greater than 1 meant that the taste sensitivity of the affected side was better, and an odds ratio lower than 1 meant that the taste sensitivity of the affected side was worse.

In the overall analysis, we noted that patients with chronic otitis media had significantly worse taste sensitivity for sour, bitter and salty tastes on the affected side. The *p* value for the differences in sweet taste lay on the boundary of significance ( $\alpha = 0.05$ ) (Table II). In addition, we found no significant difference between gustatory reductions on the affected side, comparing chronic otitis media patients with and without cholesteatoma. However, there was a potential bias in our results owing to the varying locations of cholesteatoma and the limited number of chronic otitis media cases with cholesteatoma.

TABLE I  
CHARACTERISTICS OF PATIENTS WITH CHRONIC OTITIS MEDIA

Characteristic	Result
Age (mean $\pm$ SD; yr)	47.5 $\pm$ 12.6
Gender (pts; n (%))	
– Female	28 (73.68)
– Male	10 (26.32)
Diagnosis (pts; n (%))	
– COM with chol	8 (21.05)
– COM without chol	30 (78.95)
Diseased side (pts; n (%))	
– Left	15 (39.47)
– Right	23 (60.53)
Intra-op CTN condition (pts; n (%))	
– Normal	27 (71.05)
– Oedema or embedded in granln	11 (28.95)
Degree of CTN injury (pts; n (%))	
– Minimal	25 (65.79)
– Moderate (stretch)	9 (23.68)
– Severe (division)	4 (10.53)

SD = standard deviation; yr = years; pt = patients; COM = chronic otitis media; chol = cholesteatoma; CTN = chorda tympani nerve; granln = granulation

TABLE II  
TASTE DIFFERENCES: AFFECTED VS HEALTHY TONGUE SIDE\*

Taste type	COM – chol		COM + chol		Total	
	OR	<i>p</i>	OR	<i>p</i>	OR	<i>p</i>
Sour	0.59	0.0186	0.33	0.0275	0.53	0.0023
Bitter	0.5	0.0004	0.62	0.2879	0.53	0.0003
Sweet	0.82	0.3813	0.31	0.0145	0.66	0.0529
Salty	0.59	0.0622	0.61	0.3133	0.61	0.04

\*Before surgery. COM = chronic otitis media; chol = cholesteatoma; OR = odds ratio (comparing affected with healthy side); (COM–chol) = COM without cholesteatoma and (COM+chol) = COM with cholesteatoma

One week after surgery, the gustatory test demonstrated no remarkable change in taste perception, except for sweet taste perception, which appeared to be better than before the operation (odds ratio (OR) = 4.17,  $p = 0.0032$ ). At one month after surgery, sweet (OR = 6.67,  $p = 0.0009$ ), salty (OR = 2.54,  $p = 0.0421$ ) and sour (OR = 4.61,  $p = 0.0041$ ) taste perceptions were significantly better than before the operation (Figure 1).

Figure 2 shows the taste alterations in patients with minimal nerve injury intra-operatively. One month after surgery, these patients' sweet (OR = 6.77,  $p = 0.0009$ ), sour (OR = 3.74,  $p = 0.0101$ ) and salty (OR = 2.65,  $p = 0.0495$ ) taste perceptions were better than before the operation (Figure 2).

Figure 3 demonstrates the taste alterations in patients with moderate nerve injury (i.e. stretched nerve) observed intra-operatively. One month after surgery, none of the taste tests showed any significant difference, compared with results before the operation (Figure 3).

Figure 4 shows the taste alterations in patients with severe nerve injury (i.e. nerve division) observed intra-operatively. Most taste tests showed a tendency towards deterioration after chorda tympani nerve division. However, statistical analysis showed a statistically significant change only in salty taste perception one week after the operation (OR = 0.08,  $p = 0.0395$ ). One month after surgery, none of the taste tests performed in patients with severe nerve injury showed any statistically significant difference, compared with results before the operation (Figure 4).

**Discussion**

The presence of ipsilateral altered taste function in patients with chronic inflammatory middle-ear disorders has been well documented previously, using pathology reviews and electrogustometry.<sup>4,5</sup> Other studies have reported that patients with non-

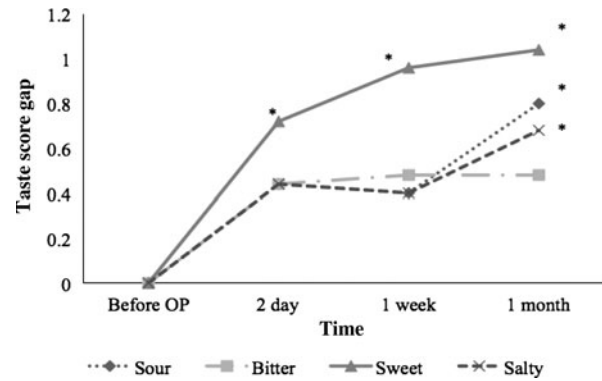


FIG. 2

Mean taste score gap, comparing pre- versus post-operative gustatory test scores in patients with chronic otitis media undergoing middle-ear surgery (OP) involving minimal chorda tympani nerve injury.

inflammatory middle-ear disease showed post-operative chorda tympani nerve related symptoms more frequently than did those with inflammatory disease.<sup>1,6,7</sup> Although taste decline may be present in patients with middle-ear inflammatory disorder pre-operatively, most of these patients have no subjective symptoms.<sup>8</sup> Interestingly, Saito *et al.* reported that only 39 per cent of patients with a severely damaged chorda tympani nerve complained of post-operative taste alteration, even though all patients' electrogustometry results indicated no taste response whatsoever.<sup>9</sup> Therefore, objective electrophysiological findings and subjective taste perception are not completely identical.

Currently, taste is often evaluated by objective electrogustometry and subjective questionnaire feedback. Taste changes before and after middle-ear surgery are strongly associated with patient satisfaction and quality of life. In our study, we employed gradient-concentration taste testing using convenient, hygienic, disposable materials in order to evaluate the taste function

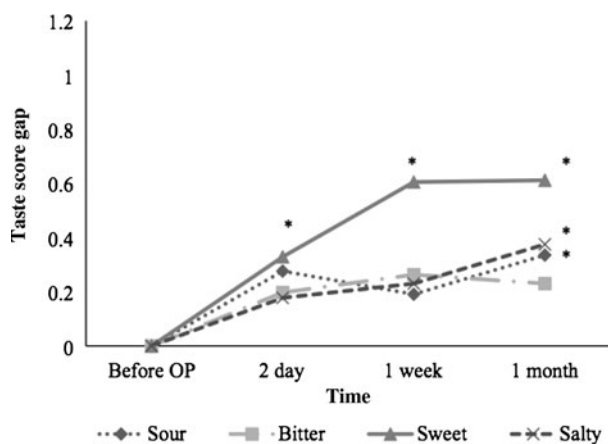


FIG. 1

Mean taste score gap, comparing pre- versus post-operative gustatory test scores in patients with chronic otitis media undergoing middle-ear surgery (OP). A greater taste score gap indicates better taste perception than before surgery.

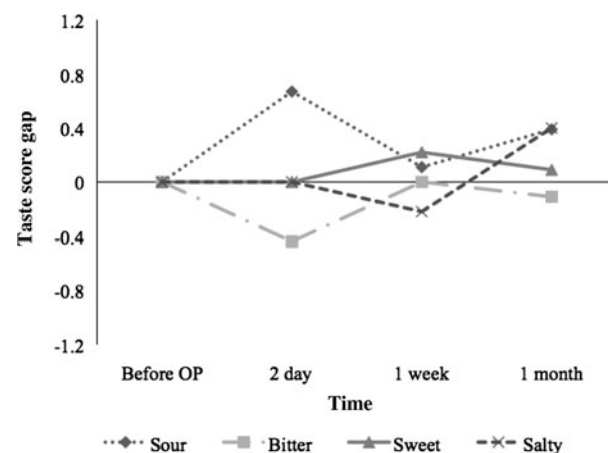


FIG. 3

Mean taste score gap, comparing pre- versus post-operative gustatory test scores in patients with chronic otitis media undergoing middle-ear surgery (OP) involving moderate chorda tympani nerve injury (i.e. stretch).

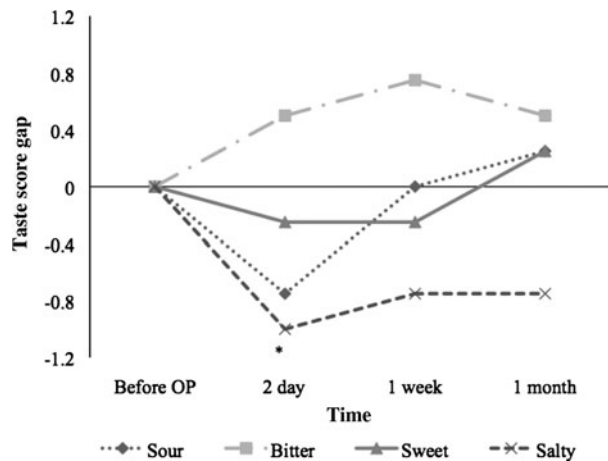


FIG. 4

Mean taste score gap, comparing pre- versus post-operative gustatory test scores in patients with chronic otitis media undergoing middle-ear surgery (OP) involving severe chorda tympani nerve injury (i.e. division).

of patients with chronic otitis media before and after surgery. According to our extensive Medline and Embase literature search, the current study represents the first reported assessment of taste changes in patients with chronic otitis media undergoing middle-ear surgery, using a gustatory test. Our taste test method, although still subjective, was far more precise than asking about patients' experiences when eating, as we were able to localise testing to various parts of the tongue, as well as to examine individual taste types.

Landis *et al.* proposed that patients with chronic middle-ear inflammatory disease have a difference between taste function on the healthy side versus the diseased side, and that differences in sweet and salty tastes are the most prominent.<sup>8</sup> Goyal *et al.* noted that, in patients with chronic otitis media without cholesteatoma, the most prominent taste difference between the healthy and diseased sides concerned bitter taste perception.<sup>3</sup> Our findings were consistent with those of Goyal *et al.*

Lauerma and Paalassalo reported that dietary habits changed in patients who had undergone middle-ear surgery, with increased salt consumption being the most apparent change.<sup>10</sup> We found that patients with chorda tympani nerve division showed a marked decline in ipsilateral salty taste perception within the first week of surgery.

Nowadays, many experts would agree that the incidence of subjective taste disorder after severe chorda tympani nerve injury is low, although the data are not consistent.<sup>9,11</sup> Our understanding of nerve healing physiology would suggest that complete recovery of nerve function a short time after division is highly unlikely. However, surprisingly, our patients with intra-operative chorda tympani nerve division showed no statistically significant differences in taste perception, comparing gustatory test results before and one month after surgery. The possible explanations for

this finding are as follows: (1) release of glossopharyngeal nerve inhibition following chorda tympani nerve damage;<sup>2,12</sup> (2) cross-innervation from the contralateral chorda tympani nerve;<sup>9,13</sup> and (3) the fact that taste perception involves the entire mouth and involves complex neural networks including the VIIth, IXth and Xth cranial nerves, and that the influence of a single unilateral chorda tympani nerve is relatively unremarkable.<sup>14</sup>

- **Middle-ear chronic inflammation interferes with ipsilateral taste function**
- **Middle-ear surgery addresses ear pathology but also improves gustatory function**
- **In patients with intra-operative chorda tympani nerve injury, post-operative taste impairment is usually only temporary**

Cain and colleagues' animal study confirmed that the volume of ipsilateral fungiform taste buds shrank in the first two weeks after chorda tympani nerve division but had recovered four weeks after nerve division, with no statistically significant difference from controls.<sup>15</sup> In addition, a stable nerve response was detected electrophysiologically four weeks after nerve injury.<sup>15</sup> Nin and colleagues' study revealed that 83.3 per cent of patients with taste disorders following unilateral chorda tympani nerve section had completely recovered one year after the trauma.<sup>16</sup> Furthermore, Siato *et al.* found that if the chorda tympani nerve had been severed, nerve repair promoted better recovery as assessed by electrogustometry.<sup>9</sup>

## Conclusion

Middle-ear chronic inflammation interferes with ipsilateral taste function. Middle-ear surgery addresses ear pathology but also improves gustatory function. In patients with intra-operative chorda tympani nerve injury, post-operative taste decline is usually only temporary.

## Acknowledgements

This research was supported in part by research grants from the National Science Council (grant number NSC 98-2314-B-039-024-MY3) and the China Medical University Hospital (grant numbers DMR 97-064 and DMR 98-029).

## References

- 1 Sakagami M. Taste disturbance and its recovery after middle ear surgery. *Chem Senses* 2005;**30**(suppl 1):i220-1
- 2 Kveton JF, Bartoshuk LM. The effect of unilateral chorda tympani damage on taste. *Laryngoscope* 1994;**104**:25-9
- 3 Goyal A, Singh PP, Dash G. Chorda tympani in chronic inflammatory middle ear disease. *Otolaryngol Head Neck Surg* 2009;**140**:682-6
- 4 Sano M, Ito K, Suzukawa K, Kaga K, Yamasoba T. Influence of chronic middle ear diseases on gustatory function: an electrogustometric study. *Otol Neurotol* 2006;**28**:44-7

- 5 Gedikli O, Dođru H, Aydin G, Tüz M, Uygur K, Sari A. Histopathological changes of chorda tympani in chronic otitis media. *Laryngoscope* 2001;**111**:724–7
- 6 Clark MP, O'Malley S. Chorda tympani nerve function after middle ear surgery. *Otol Neurotol* 2007;**28**:335–40
- 7 Sakagami M, Sone M, Tsuji K, Fukazawa K, Mishiro Y. Rate of recovery of taste function after preservation of chorda tympani nerve in middle ear surgery with special reference to type of disease. *Ann Otol Rhinol Laryngol* 2003;**112**:52–7
- 8 Landis BN, Beutner D, Frasnelli J, Hüttenbrink KB, Hummel T. Gustatory function in chronic inflammatory middle ear diseases. *Laryngoscope* 2005;**115**:1124–7
- 9 Saito T, Manabe Y, Shibamori Y, Yamagishi T, Igawa H, Tokuriki M *et al.* Long-term follow-up results of electrogustometry and subjective taste disorder after middle ear surgery. *Laryngoscope* 2001;**111**:2064–70
- 10 Lauerma H, Paalassalo P. The need for excessive dietary sodium chloride following tympanoplasty. *J Laryngol Otol* 1995;**109**:324–5
- 11 Michael P, Raut V. Chorda tympani injury: operative findings and postoperative symptoms. *Otolaryngol Head Neck Surg* 2007;**136**:978–81
- 12 Lehman CD, Bartoshuk LM, Catalanotto FC, Kveton JF, Lowlicht RA. Effect of anesthesia of the chorda tympani nerve on taste perception in humans. *Physiol Behav* 1995;**57**:943–51
- 13 Tomita H, Ikeda M, Okuda Y. Basis and practice of clinical taste examinations. *Auris Nasus Larynx* 1986;**13**(suppl 1):S1–15
- 14 Gopalan P, Kumar M, Gupta D, Phillipps JJ. A study of chorda tympani nerve injury and related symptoms following middle-ear surgery. *J Laryngol Otol* 2005;**119**:189–92
- 15 Cain P, Frank ME, Barry MA. Recovery of chorda tympani nerve function following injury. *Exp Neurol* 1996;**141**:337–46
- 16 Nin T, Sakagami M, Sone-Okunaka M, Muto T, Mishiro Y, Fukazawa K. Taste function after section of chorda tympani nerve in middle ear surgery. *Auris Nasus Larynx* 2006;**33**:13–17

Address for correspondence:

Dr Chia-Der Lin,  
Department of Otolaryngology,  
China Medical University Hospital,  
2 Yuh-Der Road,  
Taichung City, Taiwan 40447

Fax: +886 4 2205 2121

E-mail: esophagus@pchome.com.tw

---

Dr C-D Lin takes responsibility for the integrity of the content of the paper

Competing interests: None declared

---