

FETAL ATRIAL FLUTTER: A CASE REPORT AND EXPERIENCE OF SOTALOL TREATMENT

Tsui-Hua Wu, Li-Chia Huang, Ming Ho, Chien-Chung Lee, Tsan-Hung Chiu*, Yao-Ching Hung
Department of Obstetrics and Gynecology, China Medical University Hospital, Taichung, Taiwan.

SUMMARY

Objective: Fetal tachyarrhythmia may cause fetal hydrops and lead to fetal morbidity and mortality. Supraventricular tachycardia and atrial flutter have been the most diagnosed. We present a case of fetal atrial flutter diagnosed during the second trimester treated with digoxin and sotalol and delivered at term.

Case Report: A 30-year-old primigravid woman was diagnosed with fetal atrial flutter at the gestational age of 25 weeks with atrial rates of 480–520 bpm and ventricular rates of 200–250 bpm. Initially, she was treated with digoxin then with a combination of digoxin and sotalol. The fetal heart beat slowed after sotalol treatment but did not return to sinus rhythm. The fetus was delivered vaginally. Neonatal echocardiography showed a small apical ventricular septal defect and small patent ductus arteriosus. Electrocardiography also revealed atrial flutter with occasional atrial fibrillation.

Conclusion: The efficacy of antiarrhythmic drug therapy for fetal atrial flutter has not been well established. In our case, we used sotalol combined with digoxin and the fetal heart beat slowed after therapy. Sotalol may be considered the drug of choice for fetal atrial flutter. If the fetal atrial flutter is resistant to these therapies, a combination of other congenital cardiac diseases or organic abnormalities should be considered. [*Taiwanese J Obstet Gynecol* 2006;45(1):79–82]

Key Words: fetal atrial flutter, sotalol, digoxin

Introduction

Fetal atrial flutter (AF) is one of the most common fetal tachyarrhythmias. The condition may be associated with congestive heart failure, fetal hydrops, neurologic morbidity, and intrauterine death. Transplacental therapy with digoxin is the most common medical treatment [1]. The efficacy of second-line drugs for fetal AF reported in other studies has varied [1–3]. Sotalol is a β -blocking agent with additional class III antiarrhythmic properties and has been reported to have high rates of success in fetuses with AF [4,5]. Here, we present a case of fetal AF.

Case Report

A 30-year-old woman, gravida 1, para 0, without antecedent obstetric or medical problems, came to our hospital because of fetal tachyarrhythmia noted at 25 weeks' gestation. She had been prescribed 1 oral digoxin 0.25 mg twice daily (bid) at another hospital. Due to the side effects of digoxin (nausea, vomiting, etc.) and persistent fetal tachyarrhythmia, she gave up on the therapy and referred herself to our hospital at 27 weeks' gestation. Maternal thyroid function and auto-immune disease surveys were within normal limits. Fetal AF was diagnosed using M-mode echocardiography and revealed atrial rates of approximately 480–520 beats per minute (bpm) and ventricular rates of approximately 200–250 bpm with occasional satisfactory atrioventricular block leading to ventricular rates of 120 bpm (Figure 1). No structural anomalies were noted on ultrasonography.

We started treatment with oral digoxin 0.25 mg three times daily (tid) and kept within the recommended

*Correspondence to: Dr. Tsan-Hung Chiu, Department of Obstetrics and Gynecology, China Medical University Hospital, 2 Yuh-Der Road, Taichung 404, Taiwan.
 E-mail: D3861@www.cmuh.org.tw
 Received: May 12, 2005
 Revised: September 13, 2005
 Accepted: October 11, 2005




Figure 1. Fetal atrial flutter before treatment, with atrial rates of 500 bpm and ventricular rates of 231 bpm.

plasma digoxin therapeutic range. The fetal tachyarrhythmia persisted during 2 weeks of digoxin therapy. We added sotalol 80 mg bid to the digoxin, as recommended by a cardiologist. The fetal ventricular rates gradually decreased when the sotalol dosage was increased to 160 mg bid with digoxin at 0.75 mg/day. After maintaining the dosage of the two drugs for 3 weeks, large variations in the fetal heart beat, from 220 to 100 bpm, were observed. During therapy, the fetal heart beat decreased to a ventricular rate of approximately 80–160 bpm and the atrial rate to approximately 210 bpm (Figure 2). The dose was then tapered according to the medical response. During the last 2 weeks of therapy, we only used 0.25 mg/day digoxin, which kept the ventricular rhythm at approximately 100–160 bpm. No congestive heart failure in the fetus was found during therapy, according to a series of echocardiography films.

Labor was induced after the pregnancy had progressed to 37-4/7 weeks. A female baby weighing 3,000 g was born via vaginal delivery. After birth, a complete electrocardiogram (ECG) showed AF with occasional fibrillation (Figure 3). Echocardiography

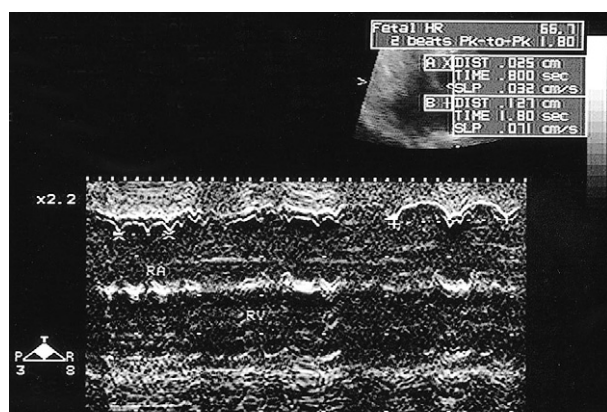


Figure 2. Fetal atrial flutter after sotalol/digoxin combined treatment, with ventricular rates of about 67–150 bpm.

revealed a small apical muscular ventricular septal defect, a small patent ductus arteriosus, a moderate degree of pulmonary artery hypertension, mild-to-moderate tricuspid regurgitation, and arrhythmogenic dilation of cardiomyopathy. Brain ultrasonography showed no structural anomalies. Amiodarone 5–8 µg/kg/min was used at first to control the tachyarrhythmia, while heparin was used to prevent thrombus formation. The ventricular rate had slowed but did not convert to sinus rhythm. Cardioversion by direct current was attempted but failed. Esmolol was ineffective. The combination of digoxin, inderal, and amiodarone taken orally controlled ventricular rates to approximately 60–160 bpm and atrial rates to approximately 300 bpm; oral aspirin was included to prevent thrombus formation. The infant was taken home after the therapy was changed to oral medication. Pediatricians recommended follow-up of electrophysical studies for the infant. At 1 month, the infant showed no neurologic sequelae.

Discussion

Fetal AF is defined as a rapid regular atrial rate of 300–600 bpm with identical or slower ventricular heart rate. The condition may be associated with congestive heart failure, hydrops, neurologic morbidity, or intrauterine death. Therefore, prenatal intervention is necessary. The aim of intensive treatment is to convert to a sinus rhythm with adequate ventricular rate, to prevent or reverse congestive cardiac failure, and to avoid preterm delivery.

Digoxin is one of the most commonly used drugs to control fetal tachyarrhythmia. The dosage scheme starts at 0.25 mg tid and increases to a maximum of 0.5 mg tid. The dose is adjusted to achieve a maternal serum concentration in the therapeutic range of 0.8–2.0 ng/mL. A retrospective study by Simpson and Sharland included 127 fetuses with tachyarrhythmias [6], of which 105 had supraventricular tachycardia (SVT) and 22 had AF. Fifty-two fetuses were hydropic and 75 were non-hydropic. Digoxin monotherapy converted most (62%) non-hydropic fetuses but the response rate in hydropic fetuses was 20%. The authors concluded that non-hydropic fetuses with tachyarrhythmias have a good prognosis with transplacental treatment. In our patient, digoxin was used initially at 0.25 mg tid, keeping the maternal serum concentration within the therapeutic range. However, the fetal tachyarrhythmia did not respond. In addition, maternal side effects almost caused the patient to discontinue therapy. Thus, we asked for another medication to be used in the treatment.

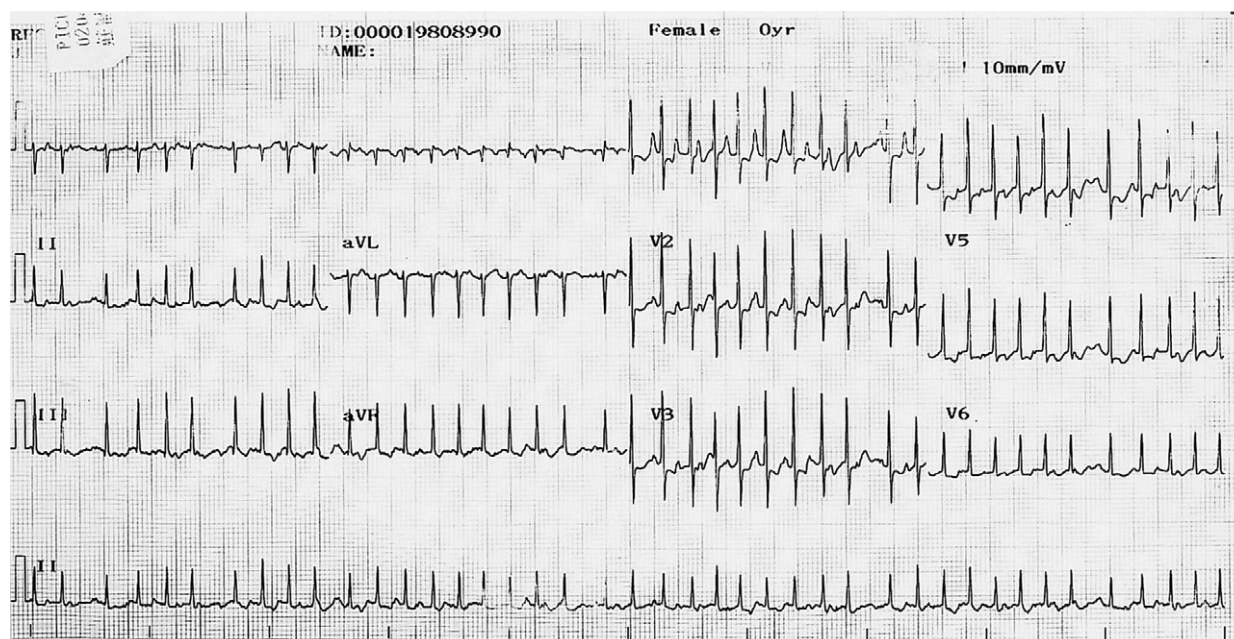


Figure 3. Electrocardiogram of the neonate after birth prior to treatment shows atrial flutter with occasional atrial fibrillation.

Sotalol is a potent β -blocking agent with additional class III antiarrhythmic properties and has mild or no negative inotropic effects. Class III agents prolong action potential in the tissue, i.e. the QT interval. Sotalol is contraindicated in patients with a baseline QT interval greater than 450 msec, bronchial asthma or chronic obstructive pulmonary disease, and creatinine clearance of less than 40 mL/min. During sotalol treatment, QT intervals need to be monitored by ECG, as do renal function, and serum potassium and magnesium levels [7,8]. Sotalol is eliminated through the kidneys so the dose needs to be adjusted according to creatinine clearance in patients with renal impairment. Sotalol can transfer across the placenta rapidly and completely. The initial suggested dosage scheme is 80 mg bid, after which the dose is increased stepwise to a maximum of 160 mg tid [4]. Oudijk et al described fetal dysrhythmia patients treated with sotalol [5]. Their retrospective study included 10 fetuses with AF, 10 with SVT, and one with ventricular tachycardia. Sotalol treatment successfully established a sinus rhythm in eight fetuses with AF and six fetuses with SVT. The mortality rate was 19%; three had SVT and one had AF. The authors concluded that sotalol should be considered the drug of choice to treat fetal AF due to the high success rate. In our case, fetal AF had a poor response to digoxin treatment and poor maternal tolerance (gastrointestinal discomfort). Therefore, we added sotalol to the treatment. We started the dose at 80 mg bid. The fetal ventricular rhythm had improved by the time the dose reached 160 mg tid. We believe that sotalol is an effective treatment for fetal AF and should be considered the best drug.

Lisowski et al conducted a similar study involving 44 fetuses with AF [9]. Among 20 hydropic fetuses, 10 received single-drug therapy (digoxin or sotalol), seven received multi-drug therapy, and three received no treatment. Of 24 non-hydropic fetuses, 13 received a single drug (digoxin or sotalol), five received multiple drugs (digoxin, procainamide, quinidine, flecainide, propafenone, sotalol), and six were delivered immediately. The authors concluded that digoxin failed to prevent recurrence at the time of delivery in 25% of patients, whereas no recurrence of AF was reported with sotalol, suggesting that the class III agent may be the best future therapy.

Flecainide is a very effective drug in the treatment of fetal SVT but concerns about possible pro-arrhythmic effects have limited its use. Amiodarone has been prescribed in preference to other drugs, but it is not frequently used due to its poor tolerability. Verapamil is contraindicated as it may increase mortality rates [1].

In our case, although fetal sinus rhythm was not reached after combined sotalol and digoxin treatment, we delivered the infant at term, as suggested in the study by Jaeggi et al [2]. They reported a retrospective study of 49 fetuses with tachyarrhythmia, 15 of which (30.6%) had AF. Eleven of these were treated with maternal digoxin after which five converted to sinus rhythm; four fetuses received no medication. Seven neonates exhibited AF at birth but rhythm was controlled within the first 2 days of life. The authors concluded that most fetuses with therapy-resistant AF and the absence of 1:1 atrioventricular conduction do not experience

congestive heart failure, so do not need to be delivered prematurely.

Several studies state that after delivery, fetal AF can be controlled by medication or by direct current cardioversion [2,3]. When sinus rhythm has been established, recurrence of AF is rare. However, in our case, the neonate had persistent AF even during postnatal treatment. Despite no obvious anatomic deformities on cardiography, atrial fibrillation was still noted. Therefore, we concluded that the failure of intrauterine therapy might be due to a combination of other tachyarrhythmia patterns in the fetus.

References

1. Oudijk MA, Ruskamp JM, Ambachtsheer BE, Ververs TF, Stoutenbeek P, Visser GH, Meijboom EJ. Drug treatment of fetal tachycardias. *Paediatric Drugs* 2002;4:49-63.
2. Jaeggi E, Fouron JC, Drblik SP. Fetal atrial flutter: diagnosis, clinical features, treatment and outcome. *J Pediatr* 1998;132:335-9.
3. Krapp M, Kohl T, Simpson JM, Sharland GK, Katalinic A, Gembruch U. Review of diagnosis, treatment, and outcome of fetal atrial flutter compared with supraventricular tachycardia. *Heart* 2003;89:913-7.
4. Oudijk MA, Ruskamp JM, Ververs FF, Ambachtsheer EB, Stoutenbeek P, Visser GH, Meijboom EJ. Treatment of fetal tachycardia with sotalol: transplacental pharmacokinetics and pharmacodynamics. *J Am Coll Cardiol* 2003;42:765-70.
5. Oudijk MA, Michon MM, Kleinman CS, Kapusta L, Stoutenbeek P, Visser GH, Meijboom EJ. Sotalol in the treatment of fetal dysrhythmias. *Circulation* 2000;101:2721-6.
6. Simpson JM, Sharland GK. Fetal tachycardias: management and outcome of 127 consecutive cases. *Heart* 1998;79:576-81.
7. Singh GKI. Management of fetal tachyarrhythmias. *Curr Treat Options Cardiovasc Med* 2004;6:399-406.
8. Fauci AS, Braunwald E, Isselbacher KJ, et al. *Harrison's Principles of Internal Medicine*, 14th edition. New York: McGraw-Hill, 1998:1266t.
9. Lisowski LA, Verheijen PM, Benatar AA, et al. Atrial flutter in the perinatal age group: diagnosis, management and outcome. *J Am Coll Cardiol* 2000;35:771-7.