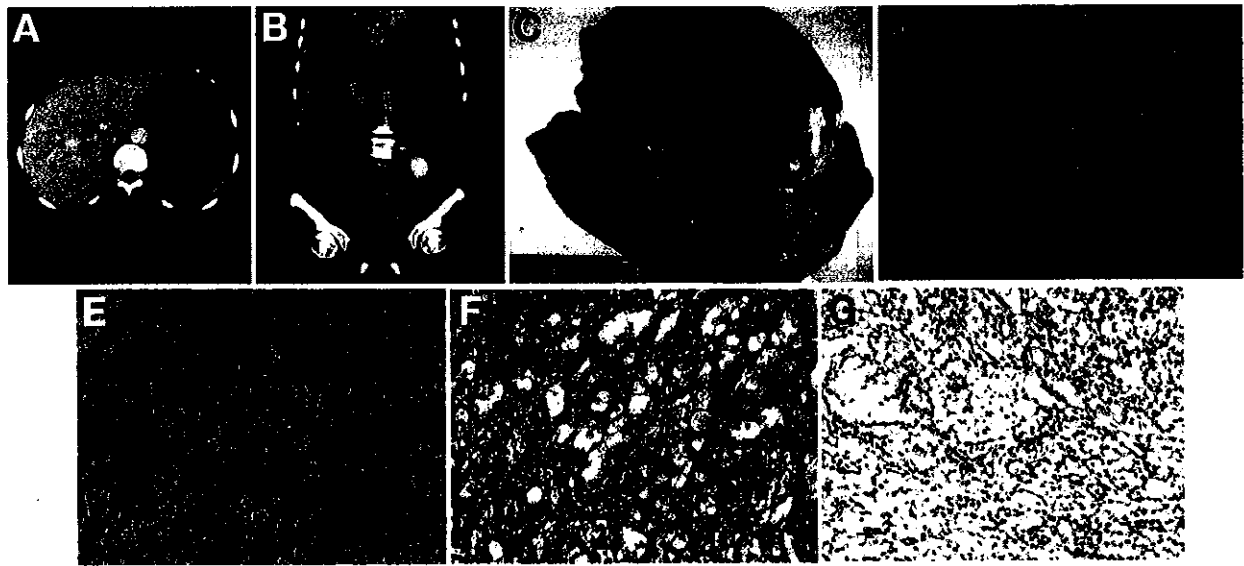


Image of the Month

Unusual Abdominal Tumor: Peritoneal Mesothelioma

PEI-YUAN SU,* YANG-YUAN CHEN,† and HSU-HENG YEN*

*Changhua Christian Hospital, Changhua, Taiwan; and †China Medical University Hospital, Taiwan, ROC



A 66-year-old woman presented to emergency department with dry cough for 1 month and low-grade fever for 2 weeks' duration. She had no remarkable medical history. On examination, the abdomen was flat with a palpable mass in the upper abdomen. An abdominal ultrasound identified a huge mass at left upper abdomen. Abdominal computed tomography (CT) showed a large mass (10 × 10 cm) in the left upper abdomen (Figure A). A serology survey including alpha-fetoprotein, carcinoembryonic antigen, and carbohydrate antigen 19-9 was within normal range. Surgical resection was suggested, but the patient decided to receive herbal therapy. Three months later, a follow-up abdominal CT showed progressive enlarging mass with intratumoral hemorrhage (Figure B). She received exploratory laparotomy (Figure C). A diagnosis of mixed sarcomatoid (Figure D) and epithelioid (Figure E) peritoneal mesothelioma (Figures F, G) with liver, stomach, and spleen involvement was made.

Mesotheliomas are tumors mainly arising from pleural cavity, and few are arising from peritoneum. It usually runs a rapid fatal course¹ and occurs most in the 5th-7th decades of life. The most common clinical presentation of peritoneal mesothelioma is abdominal pain with increasing abdominal girth.² The main risk factor is asbestos exposure, but only 58% of cases of peritoneal mesothelioma have an exposure history of asbestos.³ The most common CT appearance is a large mass or multiple small peritoneal masses in the abdominal cavity without ascites.⁴ Diagnosis is primarily made on the basis of immunohistochemistry that yields positive staining of calretinin, Wilms' tumor-1

antigen, mesothelin, and antimesothelial cell antibody-1.⁵ Cytoreductive surgery should be the first choice of treatment.⁶

References

1. de Pangher-Manzini V. Malignant peritoneal mesothelioma. *Tumori* 2005;91:1-5.
2. Acherman YI, Welch LS, Bromley CM, et al. Clinical presentation of peritoneal mesothelioma. *Tumori* 2003;89:269-273.
3. Boffetta P. Epidemiology of peritoneal mesothelioma: a review. *Ann Oncol* 2007;18:985-990.
4. Busch JM, Kruskal JB, Wu B. Best cases from the AFIP-malignant peritoneal mesothelioma. *Radiographics* 2002;22:1511-1515.
5. Nelson G. Immunohistochemical diagnosis of epithelioid mesothelioma. *Arch Pathol Lab Med* 2005;129:1407-1414.
6. Feldman AL, Libutti SK, Pingpank JF, et al. Analysis of factors associated with outcome in patients with malignant peritoneal mesothelioma undergoing surgical debulking and intraperitoneal chemotherapy. *J Clin Oncol* 2003;21:4560-4567.

Acknowledgements

The authors thank Dr Chih-Jung Chen from the Department of Pathology, Changhua Christian Hospital for pathological diagnosis of this case.

Conflicts of Interest

The authors disclose no conflicts.

© 2011 by the AGA Institute

1542-3565/\$36.00

doi:10.1016/j.cgh.2011.01.006