

Carbon Tetrachloride-induced Hepatotoxicity and its Amelioration by *Agaricus blazei* Murrill Extract in a Mouse Model

JIN-BIOU CHANG^{1,2,*}, MING-FANG WU^{3,*}, YI-YUAN YANG⁴, SY-JYE LEU⁵, YUNG-LIANG CHEN⁶, CHUN-SHU YU⁷, CHIEH-CHIH YU⁷, SHU-JEN CHANG⁷, HSU-FENG LU^{6,8,9} and JING-GUNG CHUNG^{10,11}

¹Department of Pathology, National Defense Medical Center, Division of Clinical Pathology, Tri-Service General Hospital, Taipei, Taiwan, R.O.C.;

²Department of Medical Laboratory Science and Biotechnology, Chung Hwa University of Medical Technology, Tainan, Taiwan, R.O.C.;

³Animal Medicine Center, College of Medicine, National Taiwan University, Taipei, Taiwan, R.O.C.;

⁴School of Medical Laboratory Science and Biotechnology, Taipei Medical University, Taipei, Taiwan, R.O.C.;

⁵Department of Microbiology and Immunology, School of Medicine, Taipei Medical University, Taipei, Taiwan, R.O.C.;

⁶Department of Medical Laboratory Science and Biotechnology, Yuanpei University, Hsinchu, Taiwan, R.O.C.;

⁷School of Pharmacy, China Medical University, Taichung, Taiwan, R.O.C.;

⁸Department of Clinical Pathology, Cheng Hsin General Hospital, Taipei, Taiwan, R.O.C.;

⁹Department of Restaurant, Hotel and Institutional Management, Fu-Jen Catholic University, New Taipei, Taiwan, R.O.C.;

¹⁰Department of Biological Science and Technology, China Medical University, Taichung, Taiwan, R.O.C.;

¹¹Department of Biotechnology, Asia University, Taichung, Taiwan, R.O.C.

Abstract. This study was conducted to evaluate the hepatoprotective effect of *Agaricus blazei* Murrill extract (ABM) against experimentally induced carbon tetrachloride (CCl₄) toxicity in male BALB/c mice. The experiments included a normal group (no induction by CCl₄), CCl₄-induction group (with hepatotoxicity by CCl₄ and without treatment) and experimental groups with low dose (200 mg) or high dose (2,000 mg) of ABM extract (per kilogram mouse weight). All groups other than the normal group were treated with intraperitoneal injections of CCl₄ twice a week. Mice

were tube-fed with experimental ABM extracts or double-distilled water, accordingly, on the remaining four days each week. The whole experimental protocol lasted 8 weeks; blood and liver samples were collected for biochemical and tissue histochemical analysis. Only administration of a high dose of ABM to treatment groups resulted in a significant abrogation of CCl₄-induced increase of serum aspartate aminotransferase (AST) and alanine transaminase (ALT). Post-treatment with ABM also did not significantly reverse the alterations of glutathione peroxidase (GSHPx) and catalase. Both high- and low-dose ABM treatment reduced hepatic necrosis and fibrosis caused by CCl₄ in comparison with the CCl₄ control group in the histochemical analyses. Our results suggest that the ABM extract affects the levels of ALT and AST in mice.

*These Authors contributed equally to this study.

Correspondence to: Jing-Gung Chung, Department of Biological Science and Technology, China Medical University, No. 91, Hsueh-Shih Road, Taichung 404, Taiwan, R.O.C. Tel: +886 4220533662500, Fax: +886 422053764, e-mail: jgchung@mail.cmu.edu.tw and Hsu-Feng Lu, Department of Clinical Pathology, Cheng-Hsin General Hospital, Taipei, Taiwan, R.O.C. No.45, Cheng Hsin St., Pai-Tou, Taipei, Taiwan, R.O.C. Tel: +886 228264400 ext. 5850, Fax: +886 228264517, e-mail: ch1835@chgh.org.tw

Key Words: *Agaricus blazei* Murrill extract, carbon tetrachloride, CCl₄, BALB/c mice, antioxidant enzyme activities.

Mushrooms, primarily basidiomycetous fungi, are a popular and valuable food, low in calories and high in minerals, essential amino acids, vitamins and fiber (1); some produce substances having potential medical effects, and are called medicinal mushrooms. Among the mushroom species of *Basidiomycetes*, *Agaricus blazei* Murrill (ABM), a species native to Brazil, where it is generally known as 'sun mushroom', has received attention in folk medicine due to

its use in the remedies of ailments (2). This esculent mushroom is often consumed as food and tea in different parts of the world, especially on account of its reported medicinal properties (3). It has traditionally been used for the prevention of a range of diseases, including cancer, hepatitis, atherosclerosis, hypercholesterolemia, diabetes and dermatitis (4). Because of its alleged health effects, the mushroom was brought to Japan in the mid 1960s and subjected to biomedical research. In Japan, researchers demonstrated immunostimulation and anticancer effects of ABM extracts experimentally (5), and due to the increased consumption of this mushroom in recent years, considerable effort has been made to investigate these putative effects, with interesting, but still insufficient, clinical studies. Experimental studies increased commercial interest for ABM, especially in Japan, stimulating not only the production, but also the registration of brands with new popular names. This makes it difficult for the public to identify pure ABM strains. ABM was found to be rich in immune-modulating substances, such as β -glucans (6, 7) and proteoglycans (8), and it had anti-infection (9, 10) and antitumor (7, 8) effects in mice. To our knowledge, there are only few published data documenting the antioxidative (11) and hepatoprotective (12) effects of ABM. The purpose of this study was to examine and compare the biological activities of an ABM extract in rats and mice with chronic CCl_4 -induced liver injury, to evaluate the therapeutic effects of ABM, to probe for potential mechanisms of these effects and to determine whether therapeutic effect occurred in a dose-dependent manner or not.

Materials and Methods

Reagents. Carbon tetrachloride (CCl_4), olive oil and other reagents were purchased from Sigma-Aldrich Corp. (St. Louis, MO, USA). Diagnostic kits for assaying alanine aminotransferase (ALT) and aspartate aminotransferase (AST) were purchased from Arkray, Inc. (Kyoto, Japan). Other assay kits were obtained from Cayman Chemical Company (Ann Arbor, MI, USA).

Preparation of ABM extract. Powdered ABM was obtained from S. Canaan Biotechnology Development Co. (Taipei, Taiwan, ROC) and 22.5, 90 or 900 mg were separately suspended in 6 ml distilled water at 60°C for 10 min, then cooled to room temperature.

Animals and experimental protocols. Specific pathogen-free male BALB/c mice of similar age (6 weeks) and weight (20-25 g) were obtained from and housed at the Animal Medicine Center, College of Medicine, National Taiwan University animal holding facility, with 12 h light cycle at 20±2°C and humidity of 75±15%, in a filtered laminar air flow-controlled room for acclimatization. The experimental animals were individually earmarked, housed 5 animals per cage, and provided food and water *ad libitum*. These mice were used for the chronic CCl_4 -induced liver injury model in all experiments. All animal procedures had been reviewed and approved by the law and regulations for animal experiments of

National Science Council of the Republic of China, which are in agreement with the Helsinki declaration, and they were approved by the local Animal Board under the Minister of Agriculture in Taiwan.

In vivo studies for ABM extract as liver injury therapy. Animals were fasted overnight prior to dose administration and randomly assigned to each of the four experimental groups. Mice in group A (n=10) were administered double-distilled water; mice in group B mice (n=10) were administered 40% CCl_4 /olive oil (1 ml/kg body weight per day, *i.p.* twice per week) for 8 weeks to induce chronic chemical liver injury as a negative control. Group C was treated with 40% CCl_4 /olive oil (1 ml/kg body weight per day, *i.p.* twice per week) and was further subdivided into two different dose-groups of ABM extract treatment (200 mg/kg or 2000 mg/kg, *p.o.*, 4 days per week) for 8 weeks (n=10 for each dose group). *Via* orbital bleeding at the end of treatment, blood samples were collected (0.2 ml with 10 U/ml heparin), allowed to clot, centrifuged (1500 rpm, 10 min, room temperature) and the serum then stored at -20°C until analysis. At the end of the experiments at week 8, livers were excised immediately after the animals were sacrificed under anesthesia by CO_2 . Livers were weighed and utilized for the following biochemical and histology assessments described below.

Serum biomarker activity analysis. Serum samples were prepared at the end of the eighth week and analyzed using ALT and AST diagnostic kits, following the manufacturer's protocols. Biochemical analysis of serum ALT and AST activities was performed using standard assay kits (Boehringer Mannheim Corp., Germany). The concentration in samples was measured using a Hitachi 717 (Tokyo, Japan) biochemical instrument (13).

Glutathione peroxidase (GSHPx) assay. Livers of mice were homogenized with cold GSHPx buffer (50 mM Tris-HCl containing 5 mM EDTA and 1 mM dithiothreitol (DTT), pH 7.5). GSHPx activity was measured by a GSHPx assay kit (14). The reaction was initiated mixing glutathione, glutathione reductase, NADPH and the conversion of NADPH to NADP was assessed with a spectrophotometer at 340 nm for 5 min. The specific activity was measured as nanomoles of NADPH oxidized to NADP per minute per milligram protein as described elsewhere (14, 15).

Catalase assays. Liver tissues of mice were homogenized in cold buffer (50 mM potassium phosphate and 1 mM EDTA, pH 7.0). The supernatant was collected after centrifugation and hydrogen peroxide added as exogenous substrate. The activity of catalase was measured using a catalase assay kit (Cayman Chemical Company) as reported previously (16). Changes in the absorbance at 540 nm were monitored according to the manufacturer's protocol.

Histopathological assessment of tissues. Processing of tissue samples for histological assessment followed established procedures. In brief, the tissue samples were rinsed with 0.9% saline solution and fixed in 10% formalin. Then diagonal sections of the liver were obtained and processed (Leica TP1020, Japan) as follows in: (i) 10% neutral buffered formalin for 1 h, twice; (ii) 70% alcohol for 1.5 h; (iii) 80% alcohol for 1.5 h; (iv) 90% alcohol for 1.5 h; (v) absolute alcohol for 1.5 h, twice; (vi) xylene for 1.5 h, twice; (vii) molten wax at 65°C for 2.5 h, two changes. The processed tissues were embedded in paraffin and sectioned at 4 μm thickness, placed on frosted glass slides and dried on a hot plate 70°C for 30 min. The

Table I. Effects of *Agaricus blazei* Murrill (ABM) extract on serum aspartate aminotransferase (AST), alanine transaminase (ALT), catalase and glutathione peroxidase (GPx) in CCl₄-treated mice. CCl₄-treated mice were treated with vehicle solution (olive oil) or ABM for 8 weeks. Animals were treated with double-distilled water without CCl₄ as the control group. Serum AST, ALT, catalase and GPx levels were determined as described in the Materials and Methods.

	AST (IU/l)	ALT (IU/l) (nmol/min/mg protein)	Catalase activity (nmol/min/mg protein)	GPx activity
Normal control	340±121	76±27	10.14±3.70	57.63±9.81
CCl ₄ -induction	1137±664 ^a	785±404 ^a	13.19±5.65	49.57±12.20
200 mg/kg ABM	1030±692 ^a	764±548 ^a	15.67±9.09	45.02±14.73
2000 mg/kg ABM	591±234 ^b	454±137 ^b	9.38±4.07	46.11±8.66

^aSignificantly different from normal control group ($p<0.05$). ^bSignificantly different from CCl₄-induction group ($p<0.05$). No other apparent differences were significant.

Table II. CCl₄-Induced histopathological alterations in livers of mice were compared (except for two mice which died in the CCl₄ control group).

Groups	Total	Level of cavitation				Level of fibrosis			
		I	II	III	IV	I	II	III	IV
Normal control	10	0	0	0	0	0	0	0	0
CCl ₄ treatment	8	3	4	1	0	2	4	2	0
200 mg/kg ABM	10	5	4	1	0	4	4	2	0
2000 mg/kg ABM	10	7	3	0	0	5	5	0	0

tissues were stained using hematoxylin and eosin (H&E) stain. The sections were dewaxed in two changes of xylene (3 min each), hydrated in two changes of 100% ethanol, followed by 90% ethanol and 70% ethanol, for 3 min each, rinsed with water (3 min) and stained. The stained tissues were dehydrated with 70% ethanol followed by 90% ethanol, placed in two changes of 100% ethanol for 3 min each and cleaned with two changes of xylene (3 min each). Liver pathology was rated on four levels based on Ruwart *et al.* (17): None (I), no detectable pathological alteration; focal (II), focal and local alteration; multifocal (III), multiple focal alterations; diffuse (IV) represents broad diffuse alteration. Stage assessment of hepatic fibrosis was previously described (18, 19): I, fibrosis only occurring in the portal area; II, portal area fibrosis extends to the hepatic lobule but focal fibrosis does not link these; III, the portal fibrosis extends into the hepatic lobule, a clear pseudo-lobule is formed and bile duct hyperplasia occurs.

Statistical analysis. The experimental results are expressed as the means±SEM and are accompanied by the number of observations. Data were assessed by analysis of variance (ANOVA) and Student's *t*-test. If the analysis indicated significant differences among the group means, then each group was compared by the Newman-Keuls method.

Results

The changes in toxicity associated with the administration of ABM were assessed at the biochemical, histopathological and antioxidant enzyme activity levels. The serum concentrations of the biochemical markers ALT and AST

were obtained to evaluate the liver function. In addition, the histopathological changes in the target organ were semi-quantitatively graded.

Liver function biomarkers. Blood was collected for AST and ALT determination after CCl₄ administration to mice, at the end of the eighth week. Both serum AST and ALT levels were markedly increased (Table I) after CCl₄ induction as compared to the normal group (double-distilled water treatment) ($p<0.05$). The mean serum AST level in mice of CCl₄ treatment groups was 1137±664 IU/l but it was near 2-fold less (591±234 IU/l) in mice treated with 2000 mg/kg ABM (high dose). AST levels in mice treated with low-dose ABM were not significantly affected by treatment ($p>0.05$). Similarly, the serum ALT concentrations were measured (Table I). In the normal control group, the ALT serum concentration was substantially lower than that in the CCl₄ treatment groups ($p<0.05$). Increasing dose of ABM caused a decline of serum ALT concentration (low dose: 764±548 IU/l and high dose: 454±137 IU/l). In comparison with the normal control, high or low dose treatment was not able to restore AST and ALT to normal levels.

Assessment of antioxidant enzyme activities. To investigate the role of antioxidant enzyme activities in the liver during CCl₄ injury, we analyzed catalase and GPx. CCl₄

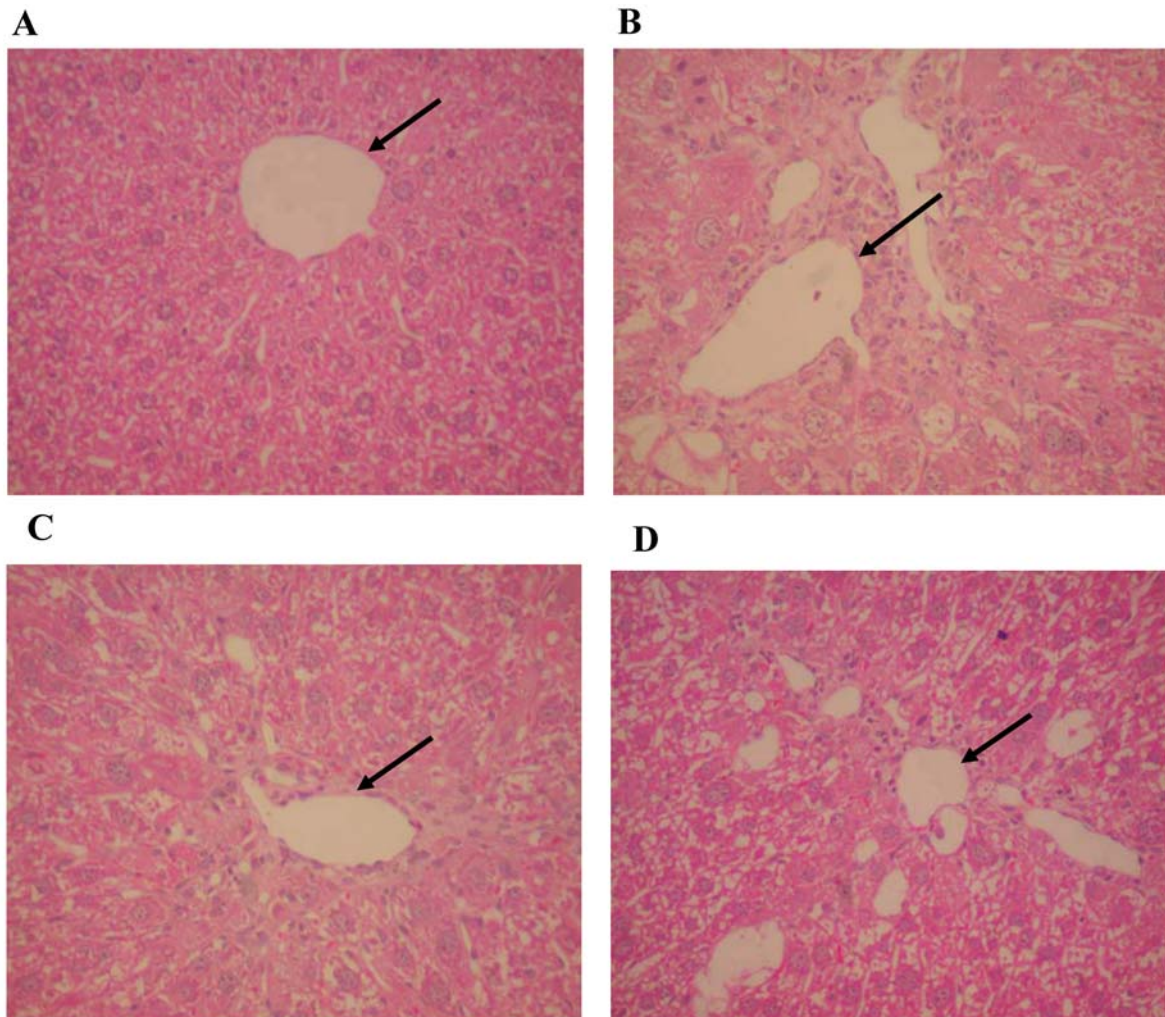


Figure 1. Histopathological analysis of mouse liver sections using H&E staining ($\times 200$). A: Section from a liver of negative control mouse. B: The liver section obtained from exhibited CCl_4 -treated mice show a variety of cavitations and necrosis in hepatocytes. C and D: Liver tissue sections prepared from mice of the 200 mg/kg and 2,000 mg/kg ABM-administration groups exhibited less cavitation and necrosis compared to these shown in B.

toxicity did not result in lower GPx and catalase activities. Contrary to expectation, neither low nor high doses of ABM significantly altered catalase and GPx activity (Table I).

Histopathological assessment. Liver tissue sections of mice were stained with H&E (Figure 1). The histopathological assessment in liver was performed for all groups. Mice in the negative control group exhibited normal, well-defined histological structures, without any signs of vascular or inflammatory changes; no cavitations, necrosis or fibrosis were found in normal control sections. The histopathological analysis of the liver revealed signs of toxicity after administration of CCl_4 . This toxicity was significant in comparison with the negative group and

included cavitations, fibrosis in broad areas, mild vascular congestion and moderate inflammatory changes with congested sinusoids, nuclear changes, and centrilobular necrosis (Figure 1B). The broad cavitations and fibrosis in livers were somewhat attenuated in mice treated with low or high doses of ABM during the experimental periods. ABM administration for mice did result in fewer cavitations and less fibrosis in the liver (Figure 1C to 1D). ABM treatment also elevated the survival rate of mice after liver injury induced by CCl_4 . We also examined the distribution of cavity and fibrosis in different liver regions (from central vein region to hepatic portal veins) for mice, as shown by Table II. ABM reduced apparent liver injury caused by CCl_4 for mice by histopathological assessment in a dose-dependent manner.

Discussion

The histopathological changes in the liver together with markers of hepatic function biochemical, were evaluated after of induction CCl₄ injury and ABM treatment. In the current study, a significant rise in serum AST and ALT levels was observed after administration of CCl₄ in comparison with the negative control group. This indicates that the experiment was successful at inducing liver injury. This is a consistent finding with previous studies where increases of serum AST and ALT concentrations after administration of CCl₄ in rats were demonstrated (18). In addition, the histopathological analysis also showed vascular and inflammatory changes, such as centrilobular necrosis, congested sinusoids and nuclear changes, which were similar to a previous study in rats (18). In contrast, after a high dose of ABM was administered, the serum AST and ALT levels were only slightly elevated and mild liver damage with slight vascular congestion and signs of hepatocyte regeneration were found. It should be noted that low-dose treatment with ABM cannot restore the serum AST and ALT levels to normal but can normalize the histopathological analysis. Comparison of the data of transaminases and histopathological assessment is very difficult and should be cautiously understated on account of the significant disagreement of administration results. If results are judged only by transaminases, it could be concluded that a low dose of ABM is not able to abrogate chemical liver injury in mice. However, this conclusion is not in agreement with the histopathological assessment. Analysis of antioxidant enzymes showed that ABM extracts had no significant effect on the activities of GSHPx and catalase under CCl₄ treatment. These results indicate that the recovery/reparative effects of ABM extracts shown by the histopathological results do not take place through an antioxidant mechanism. Removal of free radicals is not likely to contribute to the effects of ABM.

Of particular importance, we suggested that a rat model is superior to a mouse model because cavitations and fibrosis in broad areas are more severe in liver sections from the corresponding rat model of CCl₄-induced liver injury (18). Sections from CCl₄-only treated mice did not display such apparent cavitations and fibrosis in broad areas compared with those of the rat model. We can conclude that the rat model can substitute for a mouse model to evaluate treatment effect of ABM (18).

We have shown that ABM is able to abrogate chemical liver injury in mice and rats. There were no consistent treatment-related changes in clinical signs, body weight and food consumption at a dose of 2,654 mg/kg b.w./day ABM for male and 2,965 mg/kg b.w./day ABM for female rats in a study to evaluate 90-day subchronic toxicity of an aqueous extract of ABM in F344 rats (20). Although toxicity and carcinogenicity of ABM has not been established for humans, a main problem

for the administration of ABM remains the problem of the presence of aromatic hydrazines (*i.e.* agaritine and its derivatives) whose carcinogenicity and chronic systemic effects are well known in animals (21) and are probably due to metabolized toxic intermediates capable of damaging cellular macromolecules and stimulating proteolysis, giving rise to hydrazine-mediated DNA strand breaks (22). Both these studies demonstrated that the administration of hydrazine analogs *s.c.* to Swiss mice induced fibrosarcoma in 24% of males, and soft tissue tumors in both sexes (23); while in another article, agaritine administered in drinking water at 0.062% and 0.031% did not give rise to cancer, although a substantial number of animals (Swiss mice) developed convulsive seizures (24). Hydrazine analogs (from *A. bisporus* and *Gyromitra esculenta*) administered in drinking water to Swiss mice and Syrian hamsters, in contrast, did give rise to liver neoplasms (benign hepatomas, liver cell carcinomas, angiomas, angiosarcomas) and adenomas and adenocarcinomas of lungs (25).

Medicinal agents derived from plants have been used for health maintenance and disease management since the dawn of time. A main safety concern is represented by the toxicity and carcinogenicity of ABM and its derivatives that should be completely evaluated. In addition, it would probably be useful for these mushrooms, like other herbal remedies, to completely define the problem of heavy metal content. Due to the large consumption of ABM in popular remedies, more data are needed on the mechanisms of action of its components and safety before contemplating the use of ABM for prevention and treatment of cancer and immunodepressive disorders.

A high dose of ABM extract was found to reduce the activities of serum ALT and AST, which were elevated by CCl₄ in mice, as found previously for rats. This conclusion is in agreement with the histopathological assessment. This suggests that ABM extract plays a role in ALT/AST release and may improve the plasma transaminase activities and histopathology in liver injury of mice.

Acknowledgements

This study was supported by a research grant from China Medical University, Taichung, Taiwan and supported in part by Taiwan Department of Health Clinical Trial and Research Center of Excellence (DOH100-TD-B-111-004).

References

- 1 Mattila P, Salo-Vaananen P, Konko K, Aro H and Jalava T: Basic composition and amino acid contents of mushrooms cultivated in Finland. *J Agric Food Chem* 50(22): 6419-6422, 2002.
- 2 Tang NY, Yang JS, Lin JP, Hsia TC, Fan MJ, Lin JJ, Weng SW, Ma YS, Lu HF, Shen JJ, Lin JG and Chung JG: Effects of *Agaricus blazei* Murrill extract on immune responses in normal BALB/c mice. *In Vivo* 23(5): 761-766, 2009.

- 3 Endo M, Beppu H, Akiyama H, Wakamatsu K, Ito S, Kawamoto Y, Shimpo K, Sumiya T, Koike T and Matsui T: Agaritine purified from *Agaricus blazei* Murrill exerts anti-tumor activity against leukemic cells. *Biochim Biophys Acta* 1800(7): 669-673, 2010.
- 4 Wasser SP and Weis AL: Therapeutic effects of substances occurring in higher Basidiomycetes mushrooms: a modern perspective. *Crit Rev Immunol* 19(1): 65-96, 1999.
- 5 Akiyama H, Endo M, Matsui T, Katsuda I, Emi N, Kawamoto Y, Koike T and Beppu H: Agaritine from *Agaricus blazei* Murrill induces apoptosis in the leukemic cell line U937. *Biochim Biophys Acta* 1810(5): 519-525, 2011.
- 6 Ohno N, Furukawa M, Miura NN, Adachi Y, Motoi M and Yadomae T: Antitumor beta glucan from the cultured fruit body of *Agaricus blazei*. *Biol Pharm Bull* 24(7): 820-828, 2001.
- 7 Hetland G, Johnson E, Lyberg T, Bernardshaw S, Tryggestad AM and Grinde B: Effects of the medicinal mushroom *Agaricus blazei* Murrill on immunity, infection and cancer. *Scand J Immunol* 68(4): 363-370, 2008.
- 8 Itoh H, Ito H, Amano H and Noda H: Inhibitory action of a (1→6)-beta-D-glucan-protein complex (F III-2-b) isolated from *Agaricus blazei* Murrill ("himematsutake") on Meth A fibrosarcoma-bearing mice and its antitumor mechanism. *Jpn J Pharmacol* 66(2): 265-271, 1994.
- 9 Bernardshaw S, Johnson E and Hetland G: An extract of the mushroom *Agaricus blazei* Murrill administered orally protects against systemic *Streptococcus pneumoniae* infection in mice. *Scand J Immunol* 62(4): 393-398, 2005.
- 10 Bernardshaw S, Hetland G, Grinde B and Johnson E: An extract of the mushroom *Agaricus blazei* Murrill protects against lethal septicemia in a mouse model of fecal peritonitis. *Shock* 25(4): 420-425, 2006.
- 11 Mazumder S, Ghosal PK, Pujol CA, Carlucci MJ, Damonte EB and Ray B: Isolation, chemical investigation and antiviral activity of polysaccharides from *Gracilaria corticata* (*Gracilariaceae*, *Rhodophyta*). *Int J Biol Macromol* 31(1-3): 87-95, 2002.
- 12 Pinheiro F, Faria RR, de Camargo JL, Spinardi-Barbisan AL, da Eira AF and Barbisan LF: Chemoprevention of preneoplastic liver foci development by dietary mushroom *Agaricus blazei* Murrill in the rat. *Food Chem Toxicol* 41(11): 1543-1550, 2003.
- 13 Pena C, Suarez L, Bautista I, Montoya JA and Juste MC: Relationship between analytic values and canine obesity. *J Anim Physiol Anim Nutr (Berl)* 92(3): 324-325, 2008.
- 14 Park SK, Qi XF, Song SB, Kim DH, Teng YC, Yoon YS, Kim KY, Li JH, Jin D and Lee KJ: Electrolyzed-reduced water inhibits acute ethanol-induced hangovers in Sprague-Dawley rats. *Biomed Res* 30(5): 263-269, 2009.
- 15 Prohaska JR, Oh SH, Hoekstra WG and Ganther HE: Glutathione peroxidase: inhibition by cyanide and release of selenium. *Biochem Biophys Res Commun* 74(1): 64-71, 1977.
- 16 Guarino MP, Cong P, Cicala M, Alloni R, Carotti S and Behar J: Ursodeoxycholic acid improves muscle contractility and inflammation in symptomatic gallbladders with cholesterol gallstones. *Gut* 56(6): 815-820, 2007.
- 17 Ruwart MJ, Wilkinson KF, Rush BD, Vidmar TJ, Peters KM, Henley KS, Appelman HD, Kim KY, Schuppan D and Hahn EG: The integrated value of serum procollagen III peptide over time predicts hepatic hydroxyproline content and stainable collagen in a model of dietary cirrhosis in the rat. *Hepatology* 10(5): 801-806, 1989.
- 18 Wu MF, Hsu YM, Tang MC, Chen HC, Chung JG, Lu HF, Lin JP, Tang NY, Yeh C and Yeh MY: *Agaricus blazei* Murrill extract abrogates CCl₄-induced liver injury in rats. *In Vivo* 25(1): 35-40, 2011.
- 19 Standish RA, Cholongitas E, Dhillon A, Burroughs AK and Dhillon AP: An appraisal of the histopathological assessment of liver fibrosis. *Gut* 55(4): 569-578, 2006.
- 20 Kuroiwa Y, Nishikawa A, Imazawa T, Kanki K, Kitamura Y, Umemura T and Hirose M: Lack of subchronic toxicity of an aqueous extract of *Agaricus blazei* Murrill in F344 rats. *Food Chem Toxicol* 43(7): 1047-1053, 2005.
- 21 Back KC, Carter VL, Jr. and Thomas AA: Occupational hazards of missile operations with special regard to the hydrazine propellants. *Aviat Space Environ Med* 49(4): 591-598, 1978.
- 22 Runge-Morris M, Wu N and Novak RF: Hydrazine-mediated DNA damage: role of hemoprotein, electron transport, and organic free radicals. *Toxicol Appl Pharmacol* 125(1): 123-132, 1994.
- 23 Toth B and Nagel D: Studies of the tumorigenic potential of 4-substituted phenylhydrazines by the subcutaneous route. *J Toxicol Environ Health* 8(1-2): 1-9, 1981.
- 24 Toth B, Raha CR, Wallcave L and Nagel D: Attempted tumor induction with agaritine in mice. *Anticancer Res* 1(5): 255-258, 1981.
- 25 Toth B: Hepatocarcinogenesis by hydrazine mycotoxins of edible mushrooms. *J Toxicol Environ Health* 5(2-3): 193-202, 1979.

Received May 4, 2011
 Revised June 20, 2011
 Accepted June 27, 2011