

LETTER TO THE EDITOR

MOSAIC RING CHROMOSOME 4 IN A CHILD WITH MILD DYSMORPHISMS, CONGENITAL HEART DEFECTS AND DEVELOPMENTAL DELAY

BY C.-P. CHEN^{1,2,3,4,5,6}, S.-P. LIN^{2,7}, Y.-N. SU⁸, S.-R. CHERN², F.-J. TSAI^{4,9},
P.-C. WU¹, C.-C. LEE¹ AND W. WANG^{2,10}

A 2-year-old girl was the second child of non-consanguineous parents. The mother was 36 years old and the father 56 years old. She was referred for short stature and mild lymphedema of hands and feet with a clinical implication of Turner syndrome. The family history was unremarkable. She was delivered at 36 weeks of gestation with a body weight of 3,000 g in a normal pregnancy. Physical examination at two years of age revealed developmental delay, a head circumference of 42.7 cm (< 3rd centile), a body length of 81 cm (5th centile) and a body weight of 11.5 Kg (50th centile). She had short stature, psychomotor retardation, microcephaly, hypotonia, a round face, large low-set ears, a depressed nasal bridge, a short nose with anteverted nares, and mild lymphedema of hands and feet (Fig. 1). The external genitalia were normal. Echocardiography showed atrial septal defect and ventricular septal defect. Laryngoscopy revealed left vocal palsy. Brain and abdominal sonographic findings were unremarkable. Peripheral blood chromosomal analysis of the patient showed a karyotype of 46,XX,r(4)(p16.3q35.2)[82]/45,XX,-4[7]/47,XX,r(4)(p16.3q35.2),+r(4)(p16.3q35.2)[4]/46,XX,dic r(4)(p16.3q35.2)[3]/46,XX,broken r(4)(p16.3q35.2)[4]dn (Fig. 2). Both paternal and maternal chromosomal analyses were normal. Array comparative genomic hybridization (aCGH) was performed to delineate the size of deletion. Bacterial artificial chromosome (BAC)-based aCGH using CMDX BAC-aCGH CA3000 chips (CMDX, Irvine, CA, USA) showed a terminal deletion of 4q [4q35.2 (RP11-213A19→RP11-521G19)] but no genomic imbalance of the 4p16.3 probes of RP11-107698, RP11-69L7, RP11-386115, RP11-585J22, RP11-572O17, CTD-2269L21, RP11-709N10, RP11-478C1, RP11-478C5 and RP11-357G3 (Fig. 3). The probe CTD-2269L21 covers Wolf-Hirschhorn syndrome (WHS) candidate gene 1 (*WHSC1*), and the probe RP11-709N10 covers part of *WHSC1* and the entire *WHSC2*. Oligonucleotide-based aCGH using Oligo HD Scan (CMDX, Irvine,

(1) Department of Obstetrics and Gynecology, Mackay Memorial Hospital, Taipei, Taiwan.

(2) Department of Medical Research, Mackay Memorial Hospital, Taipei, Taiwan.

(3) Department of Biotechnology, Asia University, Taichung, Taiwan.

(4) School of Chinese Medicine, College of Chinese Medicine, China Medical University, Taichung, Taiwan.

(5) Institute of Clinical and Community Health Nursing, National Yang-Ming University, Taipei, Taiwan.

(6) Department of Obstetrics and Gynecology, School of Medicine, National Yang-Ming University, Taipei, Taiwan.

(7) Department of Pediatrics, Mackay Memorial Hospital, Taipei, Taiwan.

(8) Department of Medical Genetics, National Taiwan University Hospital, Taipei, Taiwan.

(9) Departments of Medical Genetics, and Medical Research, China Medical University Hospital, Taichung, Taiwan.

(10) Department of Bioengineering, Tatung University, Taipei, Taiwan.



Figure 1: Craniofacial appearance of the proband at the age of two years.

CA, USA) further showed a 5.1-Mb deletion of 4q [4q35.1q35.2 (186,182,721-191,273,063)×1] (Fig. 4). Polymorphic DNA marker analysis using DNA marker D4S2688 (4q35.2) revealed a paternal origin of the deletion.

The present case of mosaic ring chromosome 4 was associated with loss of the ring, double copies of the ring, dicentric double rings and broken rings due to instability of the ring chromosome. Loss of the ring and double copies of the ring can be caused by non-disjunction. Dicentric double rings and broken rings can be formed during the single-chromatid ring chromosome replication and separation of the centromeres at meiosis (7). If there is one sister chromatid exchange (SCE), a double ring is generated; and if there are two SCEs, the two rings become interlocked in the same direction of rotation, and the interlocked rings may break causing a broken ring and a ring when each centromere being tugged to the opposite poles at anaphase (7).

The present case manifested psychomotor retardation, microcephaly, developmental delay, congenital heart defects and mild facial dysmorphism, but did not have characteristic features of WHS such as “Greek warrior helmet” appearance on face and facial clefts. Some cases of ring chromosome 4 had clinical features of WHS due to terminal de-

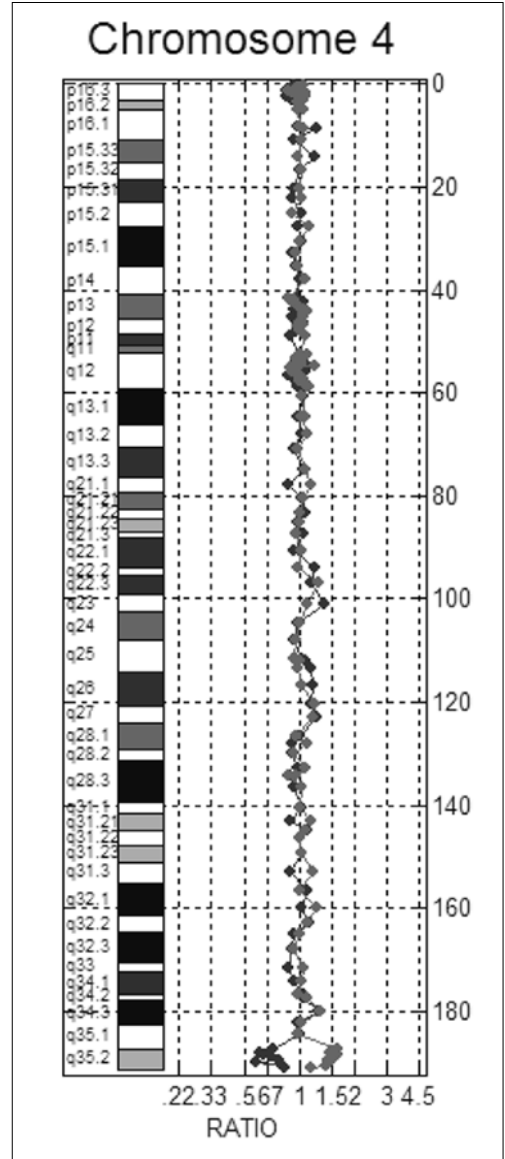
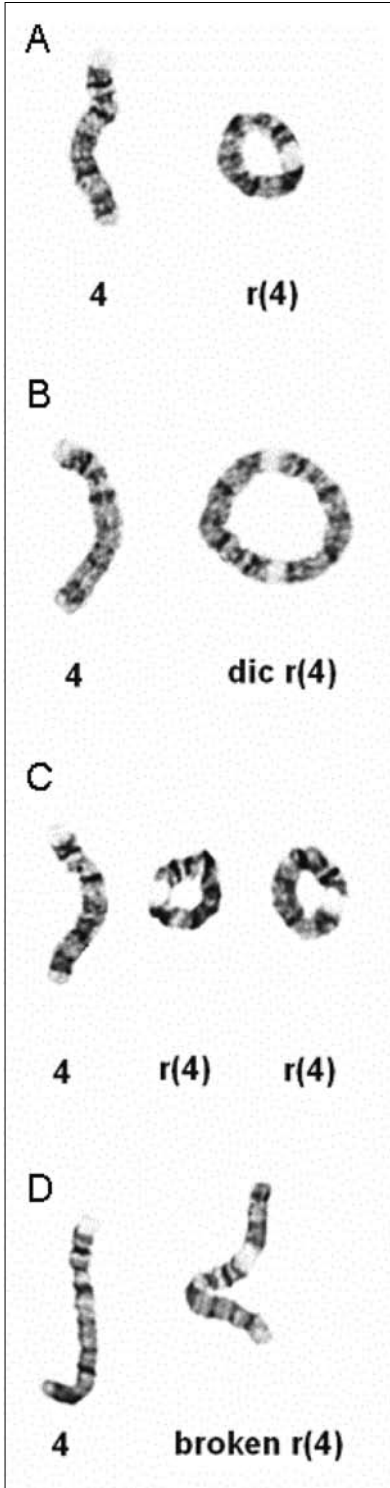
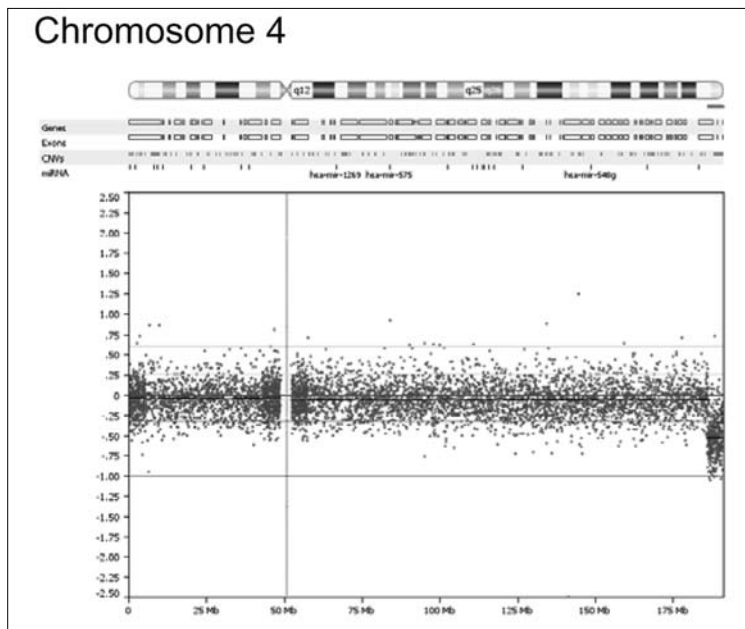


Figure 3: Bacterial artificial chromosome (BAC)-based array comparative genomic hybridization (aCGH) shows a terminal deletion of 4q35.2.

Figure 2: Partial G-banding karyotypes of peripheral blood lymphocytes show (A) ring chromosome 4, or r(4), (B) dicentric ring chromosome 4, or dic r(4), (C) double copies of r(4), and (D) broken r(4) in addition to normal chromosome 4.

Figure 4: Oligonucleotide-based aCGH shows a terminal deletion of 4q35.1-q35.2.



letion of 4p16.3 involving the WHS critical region (WHSCR) (2, 6, 10, 11, 16). The present case, however, had intact WHSCR on the ring chromosome 4 and presented a mild phenotype of terminal 4q deletion syndrome.

The terminal 4q deletion syndrome, a rare genetic event associated with a distinctive phenotype dependent on the size of the deletion, is characterized by multiple abnormalities including a dysmorphic skull, facial dysmorphisms such as hypertelorism, micrognathia, cleft palate, a short nose with anteverted nares, a smooth philtrum, full cheeks, epicanthic folds, up-slanting palpebral fissures, developmental delay, limb and digit deformities, congenital heart defects, a varying degree of psychomotor retardation, speech delay, learning difficulties, aggressive behavior and short attention span (3, 9, 13, 15, 17-19, 21-23). Lin *et al.* (12) suggested that deletion of 4q31-q33 is responsible for a more severe phenotype. Robertson *et al.* (13) suggested that the minimal critical region is within band 4q31. Tsai *et al.* (21) suggested that genes involved in heart and palate development lie distal to 4q34.2, and the critical region for more severe mental retardation lies proximal to 4q34.2. Keeling *et al.* (9) suggested that 4q33 is the critical region in 4q terminal deletion syndrome, and deletions distal to this region can be associated with less severe clinical findings. The present case had a 5.1-Mb deletion of the 4q35.1-q35.2 region encompassing the genes of *DUX4*, *FGR1*, *FGR2*, *TUBB4Q*, *CYP4V2*, *KLKB1*, *F11*, *MTNR1A*,

FAT, *ZFP42*, *TRIML1* and *HSP90AA4P*. Overexpression of the genes *FGR1* and *FGR2* is associated with facioscapulohumeral muscular dystrophy. *MTNR1A* (OMIM 600665) is a high-affinity melatonin receptor that mediates major biologic functions of melatonin. Genetic variations in the melatonin receptor genes have been shown to be associated with autism and bipolar affective disorder (1, 4, 8). *HSP90AA1* (OMIM 140571) is a heat-shock protein that plays a key role in signal transduction, protein folding, protein degradation and morphological evolution (5). *TRIML1* is a key regulator in early embryogenesis (20), and *ZFP42* has the function of embryonic stem cell differentiation (14). While the mosaicism of r(4) can affect the phenotype, the deleted 5.1 Mb at 4q35.1-q35.2 and clinical features of this patient may provide further insight into characteristic phenotype of the terminal 4q deletion syndrome.

ACKNOWLEDGEMENTS

This work was supported by research grants NSC-96-2314-B-195-008-MY3, NSC-97-2314-B-195-006-MY3 and NSC-99-2628-B-195-001-MY3 from the National Science Council, and MMH-E-100-04 from Mackay Memorial Hospital, Taipei, Taiwan.

REFERENCES

1. ABOU JAMRA R., BECKER T., GEORGI A., FEULNER T., SCHUMACHER J., STROMAIER J., SCHIRMBECK F., SCHULZE T.G., PROPPING P., RIETSCHEL M., NÖTHEN M.M., CICHON S.: Genetic variation of the *FAT* gene at 4q35 is associated with bipolar affective disorder. *Mol. Psychiatry*, 2008, 13, 277-284.
2. BALCI S., ENGIZ O., AKTAŞ D., VARGEL I., BEKSAÇ M.S., MRASEK K., VERMEESCH J., LIEHR T.: Ring chromosome 4 and Wolf-Hirschhorn syndrome (WHS) in a child with multiple anomalies. *Am. J. Med. Genet.*, 2006, 140A, 628-632.
3. CALIEBE A., WALTZ S., JENDERNY J.: Mild phenotypic manifestations of terminal deletion of the long arm of chromosome 4: clinical description of a new patient. *Clin. Genet.*, 1997, 52, 116-119.
4. CHASTE P., CLEMENT N., MERCATI O., GUILLAUME J.L., DELORME R., BOTROS H.G., PAGAN C., PÉRIVIER S., SCHEID I., NYGREN G., ANCKARSÄTER H., RASTAM M., STÅHLBERG O., GILLBERG C., SERRANO E., LEMÈRE N., LAUNAY J.M., MOUREN-SIMEONI M.C., LEBOYER M., GILLBERG C., JOCKERS R., BOURGERON T.: Identification of pathway-biased and deleterious melatonin receptor mutants in autism spectrum disorders and in the general population. *PLoS One*, 2010, 5, e11495.
5. CHEN B., PIEL W.H., GUI L., BRUFORD E., MONTEIRO A.: The *HSP90* family of genes in the human genome: insights into their divergence and evolution. *Genomics*, 2005, 86, 627-637.
6. CHEN C.-P., HSU C.-Y., TZEN C.-Y., LEE C.-C., CHEN W.-L., CHEN L.-F., WANG W.: Prenatal diagnosis of mosaic ring chromosome 4. *Prenat. Diagn.*, 2007, 27, 485-487.
7. GARDNER R.J.M., SUTHERLAND G.R.: Autosomal ring chromosomes. In: *Chromosome Abnormalities and Genetic Counseling*, 3rd edn. Gardner R.J.M., Sutherland G.R. (eds). New York, Oxford

- University Press, 2004, 178-185.
8. JONSSON L., LJUNGGREN E., BREMER A., PEDERSEN C., LANDÉN M., THURESSON K., GIACOBINI M., MELKE J.: Mutation screening of melatonin-related genes in patients with autism spectrum disorders. *BMC Med. Genomics*, 2010, 3, 10.
 9. KEELING S.L., LEE-JONES L., THOMPSON P.: Interstitial deletion 4q32-34 with ulnar deficiency: 4q33 may be the critical region in 4q terminal deletion syndrome. *Am. J. Med. Genet.*, 2001, 99, 94-98.
 10. KIM J.H., OH P.S., NA H.Y., KIM S.H., CHO H.C.: A case of mosaic ring chromosome 4 with subtelomeric 4p deletion [In Korean]. *Korean J. Lab. Med.*, 2009, 29, 77-81.
 11. LALEYE A., ALAO M.J., ADJAGBA M., HANS C., DELNESTE D., GNAMEY D.K., AYIVI B., DARBOUTX R.B.: Wolf Hirschhorn syndrome in a case of ring chromosome 4: phenotype and molecular cytogenetic findings. *Genet. Counsel.*, 2006, 17, 35-40.
 12. LIN A.E., GARVER K.L., DIGGANS G., CLEMENS M., WENGER S.L., STEELE M.W., JONES M.C., ISRAEL J.: Interstitial and terminal deletions of the long arm of chromosome 4: further delineation of phenotypes. *Am. J. Med. Genet.*, 1988, 31, 533-548.
 13. ROBERTSON S.P., O'DAY K., BANKIER A.: The 4q syndrome: delineation of the minimal critical region to within band 4q31. *Clin. Genet.*, 1998, 53, 70-73.
 14. SCOTLAND K.B., CHENS, SYLVESTER R., GUDAS L.J.: Analysis of Rex1 (zfp42) function in embryonic stem cell differentiation. *Dev. Dyn.*, 2009, 238, 1863-1877.
 15. SILLS E.S., BURNS M.J., PARKER L.D., CARROLL L.P., KEPHART L.L., DYER C.S., PAPPENHAUSEN P.R., DAVIS J.G.: Further phenotypic delineation of subtelomeric (terminal) 4q deletion with emphasis on intracranial and reproductive anatomy. *Orphanet J. Rare Dis.*, 2007, 2, 9.
 16. SOYSAL Y., BALCI S., HEKIMLER K., LIEHR T., EWERS E., SCHOUMANS J., BUI T.H., İÇDUYGU E.M., KOSYAKOVA N., İMIRZALIOĞLU N.: Characterization of double ring chromosome 4 mosaicism associated with bilateral hip dislocation, cortical dysgenesis, and epilepsy. *Am. J. Med. Genet.*, 2009, 149A, 2782-2787.
 17. STREHLE E.M., AHMED O.A., HAMEED M., RUSSELL A.: The 4q- syndrome. *Genet. Couns.*, 2001, 12, 327-339.
 18. STREHLE E.M., BANTOCK H.M.: The phenotype of patients with 4q- syndrome. *Genet. Couns.*, 2003, 14, 195-205.
 19. STREHLE E.M., MIDDLEMISS P.M.: Children with 4q- syndrome: the parents' perspective. *Genet. Couns.*, 2007, 18, 189-199.
 20. TIAN L., WU X., LIN Y., LIU Z., XIONG F., HAN Z., ZHOU Y., ZENG Q., WANG Y., DENG J., CHEN H.: Characterization and potential function of a novel pre-implantation embryo-specific RING finger protein: TRIML1. *Mol. Reprod. Dev.*, 2009, 76, 656-664.
 21. TSAI C.-H., VANDYKE D.L., FELDMAN G.L.: Child with velocardiofacial syndrome and del(4)(q34.2): another critical region associated with a velocardiofacial syndrome-like phenotype. *Am. J. Med. Genet.*, 1999, 82, 336-339.
 22. UTINE G.E., AKTAS D.: Mosaicism for terminal deletion of 4q. *Genet. Couns.*, 2006, 17, 205-209.
 23. VOGT J., RYAN E., TISCHOWITZ M.D., REARDON W., BRUETON L.A.: The tale of a nail sign in chromosome 4q34 deletion syndrome. *Clin. Dysmorphol.*, 2006, 15, 127-132.

ADDRESS FOR CORRESPONDENCE:

Chih-Ping Chen, MD
 Department of Obstetrics and Gynecology, Mackay
 Memorial Hospital
 92, Section 2, Chung-Shan North Road, Taipei, Taiwan
 Tel: + 886 (2) 2543 3535
 Fax: + 886 (2) 2543 3642; + 886 (2) 2523 2448
 E-mail: cpc_mmh@yahoo.com