

## ***Agaricus blazei* Murill Extract Abrogates CCl<sub>4</sub>-induced Liver Injury in Rats**

MING-FANG WU<sup>1</sup>, YU-MING HSU<sup>1</sup>, MING-CHU TANG<sup>1</sup>, HSUEH-CHIN CHEN<sup>1</sup>, JING-GUNG CHUNG<sup>2,3</sup>, HSU-FENG LU<sup>4</sup>, JING-PIN LIN<sup>5</sup>, NOU-YING TANG<sup>5</sup>, CHUN YEH<sup>6</sup> and MING-YANG YEH<sup>7</sup>

<sup>1</sup>Animal Medicine Center, College of Medicine, National Taiwan University, Taipei, Taiwan, R.O.C.;

<sup>2</sup>Department of Biological Science and Technology,

<sup>3</sup>School of Chinese Medicine, China Medical University, Taichung, Taiwan, R.O.C.;

<sup>4</sup>Department of Biotechnology, Asia University, Taichung, Taiwan, R.O.C.;

<sup>5</sup>Department of Clinical Pathology, <sup>6</sup>Division of Gastroenterology, Department of Internal Medicine,

<sup>7</sup>Office of Director, Cheng-Hsin General Hospital, Taipei, Taiwan, R.O.C.

**Abstract.** *Agaricus blazei* Murill (ABM) is enriched with polysaccharides, lipids, vitamins, fibers and minerals. Many studies have shown that ABM possesses immune-enhancing and anti-tumor effects. However, little is known about its protective effects on liver function. We employed carbon tetrachloride (CCl<sub>4</sub>) to induce hepatic fibrosis in a rat model to examine the protective effects of ABM on the liver in this study. The experiments included non-treatment control, CCl<sub>4</sub>-only control, and treatment with 200 mg and 2,000 mg of ABM extracts (per kilogram rat weight). All groups other than the non-treatment control were treated with intraperitoneal injections of CCl<sub>4</sub> twice a week. Experimental and control rats were tube-fed with experimental ABM extracts or double-distilled water, respectively, on the remaining four days each week. The whole experimental protocol lasted 8 weeks; blood and liver samples were collected for biochemical and tissue histochemical analysis. Plasma alanine aminotransferase and aspartate aminotransferase, and the activities of the anti-oxidative enzymes glutathione peroxidase, superoxide dismutase and catalase in the liver were measured. We found that high-dose ABM treatment reduced hepatic necrosis and fibrosis caused by CCl<sub>4</sub> in comparison with the CCl<sub>4</sub> control group. ALT and AST activities in the sera collected from

ABM-treated rats were lower than those in the CCl<sub>4</sub> control rats. These results suggested that ABM extract was capable of either enhancing liver recovering from CCl<sub>4</sub> damage or attenuating CCl<sub>4</sub> toxicity. Results of anti-oxidative enzyme activity analysis showed no apparent differences among ABM-treated groups and CCl<sub>4</sub> control groups, indicating that removal of free radicals does not explain the protective/recovery effects observed in this study.

Hepatic fibrosis results from chronic damage to the liver in conjunction with the progressive accumulation of fibrillar extracellular matrix protein (1-3). The main causes of hepatic fibrosis in humans include infection by hepatitis B and C, alcohol abuse and non-alcohol steatohepatitis; and experimentally, liver cirrhosis can be induced by carbon tetrachloride (CCl<sub>4</sub>) (4-5). Hepatic fibrosis is triggered by specific extracellular interactions among Kupper cells which are activated by membrane components from damaged hepatocytes and infiltrating inflammatory cells. The activated Kupper cells release pro-fibrotic factor such as transforming growth factor B, reactive oxygen species (ROS), and other effecting factors (5-6). These pro-fibrotic factors play key roles in hepatic fibrosis (2).

Many studies have shown that ROS, including oxygen free radicals, are causative factors in the etiology of degenerative diseases, including hepatopathies (7-8). For example, CCl<sub>4</sub>-mediated hepatic necrosis involves bioactivation by the microsomal P450-dependent monooxygenase system, resulting in the formation of trichloromethyl free radicals and ROS that initiate lipid peroxidation and protein oxidation (9). ROS can also modify and damage proteins, carbohydrates, and DNA both *in vitro* and *in vivo* (10).

The Basidiomycete fungus *Agaricus blazei* Murill (ABM) is traditionally used as a health food source in Brazil for the prevention of cancer, allergy, diabetes, hyperlipidemia,

*Correspondence to:* Jing-Gung Chung, Department of Biological Science and Technology, China Medical University, No. 91, Hsueh-Shih Road, Taichung 404, Taiwan, R.O.C. Tel: +886 422053366 ext. 2161, Fax: +886 422053764, e-mail: jgchung@mail.cmu.edu.tw; Ming-Yang Yeh, Office of Director, Cheng-Hsin General Hospital, Taipei, Taiwan, R.O.C. No.45, Cheng Hsin St., Taipei 112, Taiwan, R.O.C. Tel: +886 228264400 ext. 8009, Fax: +886 228214255, e-mail: ch1009@chgh.org.tw

*Key Words:* ALT, AST, GSH, catalase, hepatic fibrosis, CCl<sub>4</sub>, *Agaricus blazei*, liver function.

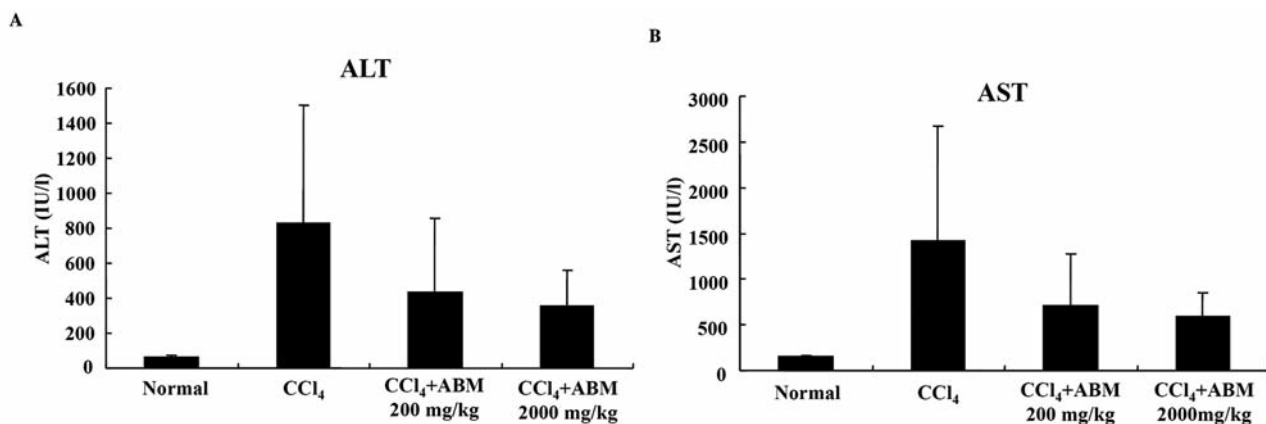


Figure 1. Effects of the ABM extract on plasma ALT and AST in CCl<sub>4</sub>-intoxicated rats. CCl<sub>4</sub>-intoxicated rats were treated with vehicle solution (double-distilled water) or two different doses of ABM extract (200 and 2,000 mg/kg) for 8 weeks. Animals were treated with double-distilled water without CCl<sub>4</sub> as the negative control group. Plasma ALT and AST levels were determined as described in the Materials and Methods. Results are presented the means±SEM (n=10).

arteriosclerosis, and chronic hepatitis, as well as an anti-inflammation, anti-bacterial and anti-viral (11-15). ABM contains a variety of polysaccharides and is considered a health food in many countries. ABM was reported to be a source of antitumor and immune-enhancing compounds (13). To our knowledge, there are no published data documenting the antioxidative and hepatoprotective effects of ABM.

The purpose of this research was to examine and compare biological activities of an ABM extract in rats with chronic CCl<sub>4</sub>-induced liver injury, to evaluate the therapeutic effects of ABM, to probe potential mechanisms and to determine whether therapeutic effect occurred in a dose-dependent manner or not.

### Materials and Methods

**Reagents.** Carbon tetrachloride (CCl<sub>4</sub>), olive oil and other reagents were obtained from Sigma-Aldrich Corp. (St. Louis, MO, USA). Diagnostic kits for assaying alanine aminotransferase (ALT) and aspartate aminotransferase (AST) were purchased from Arkray, Inc. (Kyoto, Japan). Other assay kits were obtained from Cayman Chemical (Ann Arbor, MI, USA).

**Animals.** Male Wistar rats, specific pathogen-free, 6 weeks old and weighing 250-300 g, obtained from the Animal Medicine Center, College of Medicine, National Taiwan University were used for the chronic CCl<sub>4</sub>-induced liver injury model in all experiments. The animals were maintained in a standard laboratory under a 12-h light/dark cycle in a temperature (20±2°C), humidity (75±15%), and filtered laminar air flow controlled room in the animal facility of the Animal Medicine Center, College of Medicine, National Taiwan University, Taipei, Taiwan. Rats were raised and cared for, given autoclaved water and fed *ad libitum* with laboratory pellet chow following the guidelines set up the National Science Council of the Republic of China. Experiments were performed according to

Table I. Comparison of CCl<sub>4</sub>-induced liver histopathological alterations. There were 1, 2 and 2 rats dead in the CCl<sub>4</sub> control, 200 mg/kg and 2000 mg/kg ABM groups, respectively.

Group	Level of cavitation					Level of fibrosis			
	Total	I	II	III	IV	I	II	III	IV
Negative control	10	0	0	0	0	0	0	0	0
CCl <sub>4</sub> control	9	1	3	5	0	0	2	7	0
200 mg/kg ABM	8	3	3	2	0	3	3	2	0
2000 mg/kg ABM	8	0	3	5	0	0	3	3	2

regulations and guidelines for animal experiments in Taiwan, which are in agreement with the Helsinki declaration.

**Preparation of ABM extracts.** ABM was obtained from S. Canaan Biotechnology Development Co. (Taipei, Taiwan, ROC). Air-dried ABM samples were ground and then mixed with double-distilled water at 100°C for 10 min, and then cooled to room temperature. ABM was stored at 4°C in dark bottles and kept sterile until instilled intragastrically in the rats.

**Experimental design.** Forty rats were divided into four groups (each group consisted of 10 rats): (I) As a normal control, rats were fed with regular diet and double-distilled water. (II) Rats were treated with 40% CCl<sub>4</sub>/olive oil (1 ml/kg body weight per day, *i.p.* twice per week) for 8 weeks to induce chronic chemical liver injury as a negative control. (III) Rats were treated with 40% CCl<sub>4</sub>/olive oil (1 ml/kg body weight per day, *i.p.* twice per week) and with a low dose (200 mg/kg, *p.o.*, 4 days per week) ABM extract treatment for 8 weeks. (IV) Rats were treated with 40% CCl<sub>4</sub>/olive oil (1 ml/kg body weight per day, *i.p.* twice per week) and with a high dose of (2000 mg/kg, *p.o.*, 4 days per week) ABM extract treatment for 8 weeks.

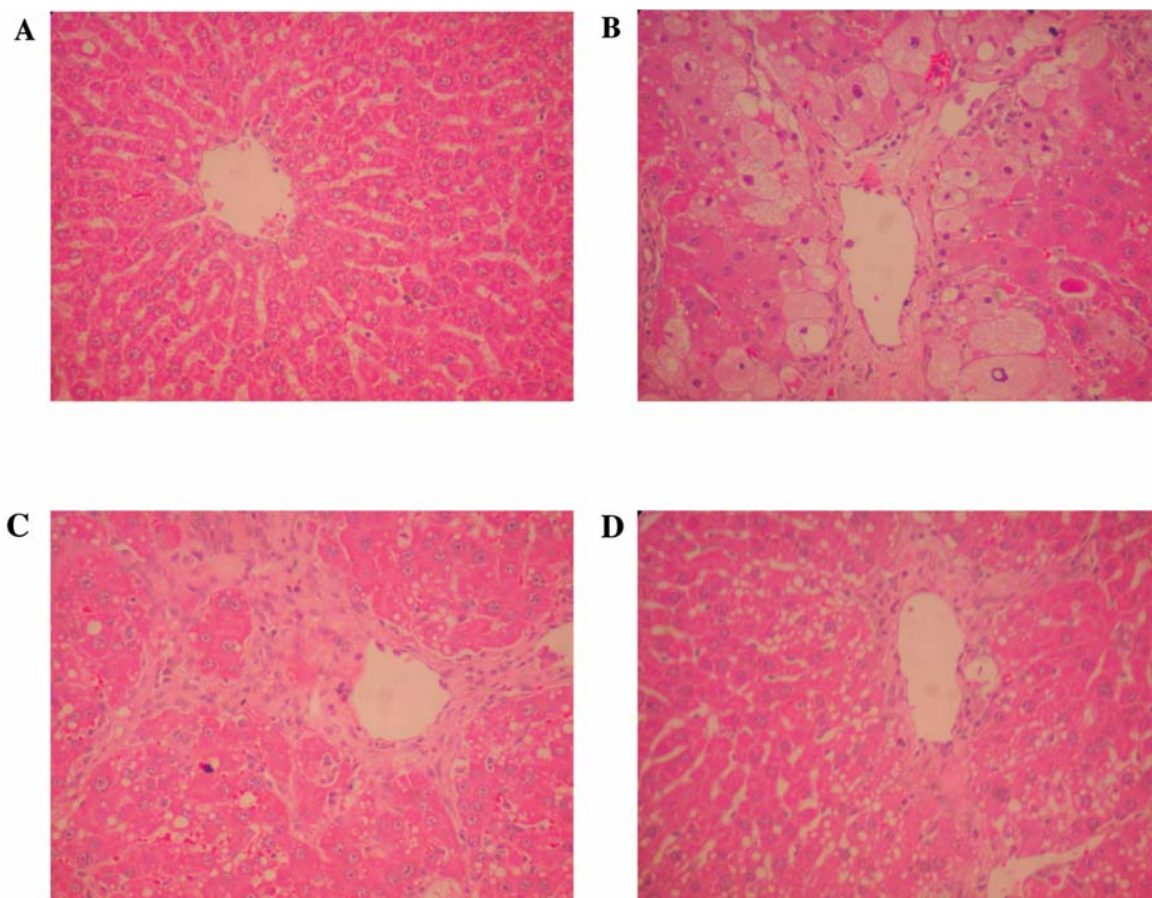


Figure 2. Histopathological analysis of rat liver sections using H&E staining. A: Section from a negative control rat liver. B: The liver section obtained from CCl<sub>4</sub>-intoxicated rats shows a variety of cavitations and necrosis in hepatocytes. C: Liver tissue section prepared from the 2,000 mg/kg ABM-treated group shows less cavitation and necrosis compared to B. D: Liver tissue section prepared from the 200 mg/kg ABM-treated group shows less cavitation and necrosis.

Blood samples (0.2 ml with 10 U/ml heparin) were collected in orbital bleeding at the end of the first, third, sixth, and eighth weeks. At the end of the experiments, blood and livers were collected immediately after the animals were sacrificed at week 8 under anesthesia by CO<sub>2</sub>. Livers were weighed and utilized for the following biochemical and histology analyses.

**Measurement of plasma transaminase activities.** Plasma samples were prepared at the end of the eighth weeks and analyzed using ALT and AST diagnostic kits, following the manufacturer's protocols. ALT and AST enzyme activities were measured by the Hitachi 717 (Tokyo, Japan) instrument and Boehringer Mannheim (Mannheim, Germany) reagent. Analytical procedures were performed according to the manufacturer's instructions (16).

**Glutathione peroxidase (GSHPx) assay.** Liver was homogenized with GSHPx cold buffer (50 mM Tris-HCl containing 5 mM EDTA and 1 mM dithiothreitol (DTT), pH 7.5). GSHPx activity was measured by a GSHPx assay kit (17). The reaction was initiated by the mixing glutathione, glutathione reductase, NADPH with cumene

(isopropylbenzene) hydroperoxide, and then detecting conversion of NADPH to NADP with a spectrophotometer at 340 nm for 5 min. The specific activity was measured as nanomoles of NADPH oxidized to NADP per minute per milligram protein.

**Catalase assays.** Liver tissues were homogenized in a cold buffer (50 mM potassium phosphate and 1 mM EDTA, pH 7.0). Supernatant was collected and hydrogen peroxide added as exogenous substrate. The activity of catalase was measured using a catalase assay kit (Cayman Chemical Company) as reported previously (18). Change in the absorbance was monitored at 540 nm according to the manufacturer's protocol.

**Histological assay.** Rats were sacrificed at the end of the eighth week, and the livers were immediately removed. Liver slices were made from a part of the left and central lobes, and immediately fixed in 10% buffered formalin phosphate solution, embedded in paraffin, and stained with hematoxylin and eosin (H&E) or Masson's trichrome (MT). Liver pathology was rated on four levels based on Ruwart *et al.* (19): None (I), no detectable pathological

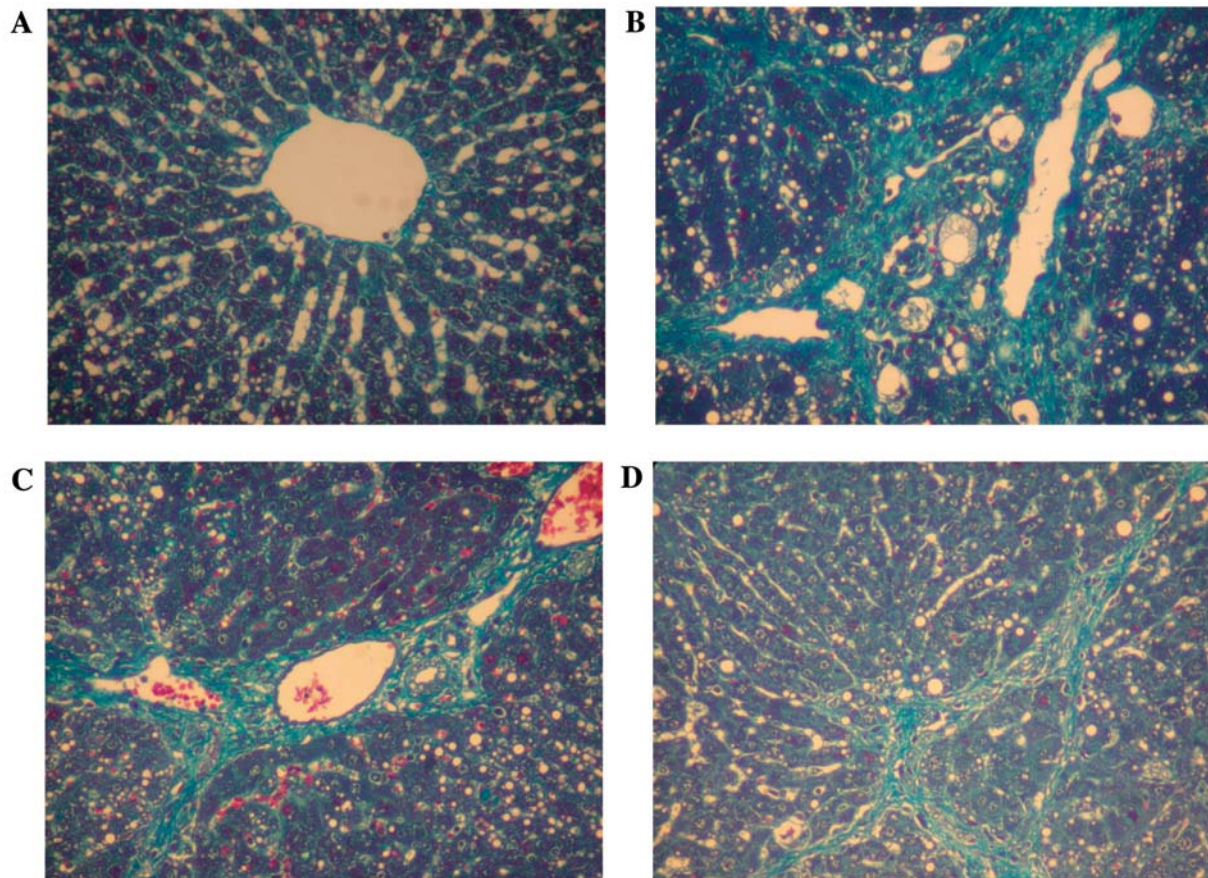


Figure 3. Histochemical analysis of hepatic fibrosis using MT staining. A: Section from a negative control rat liver section image. B: Section from liver of the CCl<sub>4</sub>-control group. C: Section from liver of rat treated with 2,000 mg/kg ABM showing reduced fibrosis, indicating a reparative process. D: Section from liver of rat treated with 200 mg/kg ABM shows obvious reduction in fibrosis, clearly indicating tissue repair.

alteration; focal (II), focal and local alteration; multifocal (III), multiple focal alterations; diffuse (IV) represents broad diffuse alteration. Stage assessment of hepatic fibrosis was rated: (I), fibrosis only occurring in the portal area; (II), portal area fibrosis extends to the hepatic lobule but focal fibrosis does not link these; (III), the portal fibrosis extends into the hepatic lobule, a clear pseudo-lobule is formed and bile duct hyperplasia occurs.

**Statistical analysis.** The experimental results are expressed as the means±SEM and are accompanied by the number of observations. Data were assessed by analysis of variance (ANOVA) and Student's *t*-test. If the analysis indicated significant differences among the group means, then each group was compared by the Newman-Keuls method.

## Results

**Plasma transaminases.** Blood was collected at the indicated times for ALT and AST determination after CCl<sub>4</sub> administration. Both plasma ALT and AST levels were markedly increased (Figure 1A and 1B) after CCl<sub>4</sub> treatment as

compared to the normal group (double-distilled water treatment). On the other hand, ABM extract (200 mg/kg and 2,000 mg/kg) significantly reduced ALT and AST levels at the eighth week as compared with those of the group treated with CCl<sub>4</sub> alone (Figure 1).

**Histopathological assessment.** Liver tissue sections were stained with either H&E (Figure 2) or MT (Figure 3). Negative control tissue sections exhibited no apparent pathological alterations (Figure 2A and Figure 3A). No cavitations, necrosis or fibrosis were found in control sections. In contrast, sections from CCl<sub>4</sub>-only treated rats displayed apparent cavitations in broad areas (Figure 2B). However, the broad cavitations in liver were attenuated in rats treated with ABM during the experimental periods. ABM administration resulted in less cavitation in the liver, shown in Figure 2C and Figure 2D. Interestingly, the cavitation level in the 200 mg/kg ABM group was lower than that in the 2,000 mg/kg ABM group. Liver sections prepared

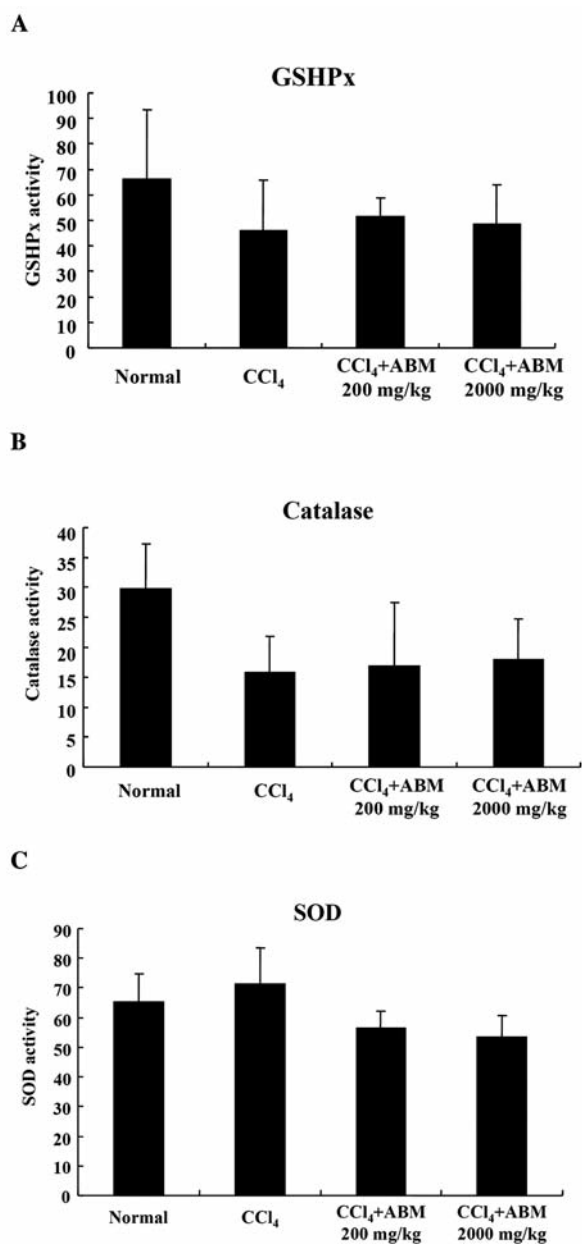


Figure 4. Activities of antioxidative enzymes (GSH peroxidase: GSHPx, catalase and SOD) in liver from CCl<sub>4</sub>-treated rats and normal control rats.

from ABM groups (Figure 3C and 3D) displayed less fibrosis as compared to the CCl<sub>4</sub> control group (Figure 3B). The reduction in the 200 mg/kg ABM group (Figure 3D) was more obvious in comparison to that of the 2,000 mg/kg ABM group (Figure 3C). We also examined the distribution of fibrosis in different liver regions (from central vein region to hepatic portal veins) (Table I). Both dosages of ABM reduced apparent liver injury caused by CCl<sub>4</sub>, compared to the CCl<sub>4</sub> control.

*Assessment of antioxidant enzyme activities.* To investigate the role of antioxidant enzyme activities in the liver during CCl<sub>4</sub> injury, we analyzed GSHPx, catalase and SOD. CCl<sub>4</sub> toxicity resulted in lower GSHPx and catalase activities (Figure 4A and 4B), but slightly increased SOD activity (Figure 4C). GSHPx activity in both ABM groups was not significantly different from that of the CCl<sub>4</sub> control (Figure 4A). ABM administrations did not significantly alter catalase activity caused by CCl<sub>4</sub> (Figure 4B). Furthermore, SOD activities were not significantly different in the CCl<sub>4</sub> control group and the two ABM groups (Figure 4C). These results show that the effects of ABM observed in Figures 2 and 3 cannot be explained by antioxidant pathways.

## Discussion

ABM has been employed as an alternative antitumor therapy for years. The biological activities and mechanisms of ABM have been reported by several groups (11-15). Mostly, previous research has focused on the immune and anti-inflammatory activities of ABM (12). Our study presents original research focusing on protection of the liver and counteraction against hepatic fibrosis.

Carbon tetrachloride has been widely used to induce liver injury in animal models (8). CCl<sub>4</sub> is metabolized to CCl<sub>3</sub> by CYP450 in hepatocytes. Subsequently, CCl<sub>3</sub> reacts with oxygen to form CCl<sub>3</sub>OO. Both CCl<sub>3</sub> and CCl<sub>3</sub>OO trigger super-oxidative chain reactions in lipid molecules (9). Further reactions with phospholipids and polyunsaturated fatty acids can affect the permeability of the cell membrane, the mitochondria, and the reticular membranes (2). Consequently, elevation of cytosol calcium leads to cell damage (7). In our CCl<sub>4</sub>-induced chronic liver injury model, we observed that the livers in ABM extract-treated rats displayed less injury in the histochemical analyses compared to those in the CCl<sub>4</sub>-only treated group. Hepatic fibrosis, necrosis, and cavitations caused by CCl<sub>4</sub> were attenuated by ABM extract administration. These results indicate that ABM extracts have recovery/reparative effects on CCl<sub>4</sub>-induced liver injury.

ABM extracts were found to reduce the activities of plasma ALT and AST which were elevated by CCl<sub>4</sub>. Both dosages of ABM abrogated the CCl<sub>4</sub> effects on plasma ALT and AST in an apparent dose-dependent manner. This suggests that ABM extract plays a role in ALT/AST release mechanism. Analysis of anti-oxidant enzymes showed that ABM extracts had no significant effect on the activities of GSHPx, catalase and SOD under CCl<sub>4</sub> treatment. These results indicate that the recovery/reparative effects of ABM extracts shown by the histopathological observations are not through antioxidant mechanism. Removal of free radicals is not likely to contribute to the effects of ABM.

Our results provide first evidence that ABM extract has recovery/reparative effect on CCl<sub>4</sub>-induced liver injury.

ALT/AST analyses suggest that active components in the ABM extract act directly or indirectly on the hepatic cell membrane. Two concentrations of ABM were examined in this report. However, the optimal concentration of ABM extract in the CCl<sub>4</sub> experimental model requires further study.

### Acknowledgements

This study was supported by grant CMU97-276 from China Medical University and Asia University, Taichung, Taiwan, R.O.C.

### Reference

- 1 Friedman SL: Seminars in medicine of the Beth Israel Hospital, Boston, the cellular basis of hepatic fibrosis, mechanisms and treatment strategies. *N Engl J Med* 328(25): 1828-1835, 1993.
- 2 Gressner AM: Cytokines and cellular crosstalk involved in the activation of fat-storing cells. *J Hepatol* 22(2 Suppl): 28-36, 1995.
- 3 Lieber CS: Prevention and treatment of liver fibrosis based on pathogenesis. *Alcohol Clin Exp Res* 23(5): 944-949, 1999.
- 4 Brattin WJ, Glende EA, Jr. and Recknagel RO: Pathological mechanisms in carbon tetrachloride hepatotoxicity. *J Free Radic Biol Med* 1(1): 27-38, 1985.
- 5 Boulton RA, Alison MR, Golding M, Selden C and Hodgson HJ: Augmentation of the early phase of liver regeneration after 70% partial hepatectomy in rats following selective Kupffer cell depletion. *J Hepatol* 29(2): 271-280, 1998.
- 6 Ames BN, Shigenaga MK and Hagen TM: Oxidants, antioxidants, and the degenerative diseases of aging. *Proc Natl Acad Sci USA* 90(17): 7915-7922, 1993.
- 7 Poli G: Liver damage due to free radicals. *Br Med Bull* 49(3): 604-620, 1993.
- 8 Lee KS, Buck M, Houglum K and Chojkier M: Activation of hepatic stellate cells by TGF alpha and collagen type I is mediated by oxidative stress through c-myc expression. *J Clin Invest* 96(5): 2461-2468, 1995.
- 9 McCay PB, Lai EK, Poyer JL, DuBose CM and Janzen EG: Oxygen- and carbon-centered free radical formation during carbon tetrachloride metabolism. Observation of lipid radicals *in vivo* and *in vitro*. *J Biol Chem* 259(4): 2135-2143, 1984.
- 10 Mason RP and Rao DN: Thiyl free radical metabolites of thiol drugs, glutathione, and proteins. *Methods Enzymol* 186: 318-329, 1990.
- 11 Oh TW, Kim YA, Jang WJ, Byeon JI, Ryu CH, Kim JO and Ha YL: Semipurified fractions from the submerged-culture broth of *Agaricus blazei* Murill reduce blood glucose levels in streptozotocin-induced diabetic rats. *J Agric Food Chem* 58(7): 4113-4119, 2010.
- 12 Padilha MM, Avila AA, Sousa PJ, Cardoso LG, Perazzo FF and Carvalho JC: Anti-inflammatory activity of aqueous and alkaline extracts from mushrooms (*Agaricus blazei* Murill). *J Med Food* 12(2): 359-364, 2009.
- 13 Ellertsen LK and Hetland G: An extract of the medicinal mushroom *Agaricus blazei* Murill can protect against allergy. *Clin Mol Allergy* 7(6), 2009.
- 14 Hetland G, Johnson E, Lyberg T, Bernardshaw S, Tryggestad AM and Grinde B: Effects of the medicinal mushroom *Agaricus blazei* Murill on immunity, infection and cancer. *Scand J Immunol* 68(4): 363-370, 2008.
- 15 Hsu CH, Hwang KC, Chiang YH and Chou P: The mushroom *Agaricus blazei* Murill extract normalizes liver function in patients with chronic hepatitis B. *J Altern Complement Med* 14(3): 299-301, 2008.
- 16 Pena C, Suarez L, Bautista I, Montoya JA and Juste MC: Relationship between analytic values and canine obesity. *J Anim Physiol Anim Nutr (Berl)* 92(3): 324-325, 2008.
- 17 Park SK, Qi XF, Song SB, Kim DH, Teng YC, Yoon YS, Kim KY, Li JH, Jin D and Lee KJ: Electrolyzed-reduced water inhibits acute ethanol-induced hangovers in Sprague-Dawley rats. *Biomed Res* 30(5): 263-269, 2009.
- 18 Guarino MP, Cong P, Cicala M, Alloni R, Carotti S and Behar J: Ursodeoxycholic acid improves muscle contractility and inflammation in symptomatic gallbladders with cholesterol gallstones. *Gut* 56(6): 815-820, 2007.
- 19 Ruwart MJ, Wilkinson KF, Rush BD, Vidmar TJ, Peters KM, Henley KS, Appelman HD, Kim KY, Schuppan D and Hahn EG: The integrated value of serum procollagen III peptide over time predicts hepatic hydroxyproline content and stainable collagen in a model of dietary cirrhosis in the rat. *Hepatology* 10(5): 801-806, 1989.

Received July 12, 2010  
 Revised September 2, 2010  
 Accepted September 2, 2010