

# PRENATAL DIAGNOSIS AND MOLECULAR CYTOGENETIC CHARACTERIZATION OF *DE NOVO* PARTIAL TRISOMY 7P (7P15.3 → PTER) AND PARTIAL MONOSOMY 13Q (13Q33.3 → QTER) ASSOCIATED WITH DANDY-WALKER MALFORMATION, ABNORMAL SKULL DEVELOPMENT AND MICROCEPHALY

Chih-Ping Chen<sup>1,2,3,4,5,6\*</sup>, Ming Chen<sup>7,8,9,10</sup>, Yi-Ning Su<sup>11</sup>, Fuu-Jen Tsai<sup>4,12,13</sup>, Schu-Rern Chern<sup>2</sup>,  
Chin-Yuan Hsu<sup>1</sup>, Pei-Chen Wu<sup>1</sup>, Dai-Dyi Town<sup>1</sup>, Dong-Jay Lee<sup>7,8</sup>,  
Gwo-Chin Ma<sup>7</sup>, Wayseen Wang<sup>2,14</sup>

Departments of <sup>1</sup>Obstetrics and Gynecology and <sup>2</sup>Medical Research, Mackay Memorial Hospital, <sup>5</sup>Institute of Clinical and Community Health Nursing, <sup>6</sup>Department of Obstetrics and Gynecology, School of Medicine, National Yang-Ming University, <sup>10</sup>Department of Obstetrics and Gynecology, College of Medicine, National Taiwan University, <sup>11</sup>Department of Medical Genetics, National Taiwan University Hospital, and <sup>14</sup>Department of Bioengineering, Tatung University, Taipei; <sup>3</sup>Department of Biotechnology, Asia University, <sup>4</sup>School of Chinese Medicine, College of Chinese Medicine, China Medical University, and Departments of <sup>12</sup>Medical Research and <sup>13</sup>Medical Genetics, China Medical University Hospital, Taichung; Departments of <sup>7</sup>Genomic Medicine, <sup>8</sup>Medical Research and <sup>9</sup>Obstetrics and Gynecology, Changhua Christian Hospital, Changhua, Taiwan.

## SUMMARY

**Objective:** To present the prenatal diagnosis and molecular cytogenetic characterization of *de novo* partial trisomy 7p (7p15.3→pter) and partial monosomy 13q (13q33.3→qter) associated with Dandy-Walker malformation (DWM), abnormal skull development, microcephaly and multiple congenital anomalies.

**Materials, Methods and Results:** A 42-year-old woman, gravida 6, para 1, was referred for amniocentesis at 18 weeks of gestation because of her advanced maternal age. Amniocentesis revealed an aberrant derivative chromosome 13, or der(13). The parental karyotypes were normal. Spectral karyotyping showed that the der(13) was derived from a translocation of chromosomes 7 and 13. Fluorescence *in situ* hybridization using subtelomeric probes revealed three signals of 7pTEL and only one signal of 13qTEL, indicating a translocation between 7p and 13q in the der(13). Array-based comparative genomic hybridization demonstrated partial trisomy 7p (7p15.3-p22.3) and partial monosomy 13q (13q33.3-q34). The karyotype was 46,XY,der(13)t(7;13)(p15.3;q33.3). Polymorphic DNA marker analysis revealed the paternal origin of the aberrant chromosome. Level II ultrasound at 24 weeks of gestation revealed microcephaly, an irregular-shaped skull, DWM, nuchal edema and transposition of the great arteries.

**Conclusion:** Spectral karyotyping, fluorescence *in situ* hybridization and array-based comparative genomic hybridization are useful for prenatal investigation of the nature of a *de novo* aberrant derivative chromosome. Partial trisomy 7p (7p15.3→pter) and partial monosomy 13q (13q33.3→qter) can be associated with DWM,



ELSEVIER

\*Correspondence to: Dr Chih-Ping Chen, Department of Obstetrics and Gynecology, Mackay Memorial Hospital, 92, Section 2, Chung-Shan North Road, Taipei, Taiwan.

E-mail: cpc\_mmh@yahoo.com

Accepted: April 15, 2010

microcephaly, abnormal skull development, nuchal edema and cardiovascular defects on prenatal ultrasound. [*Taiwan J Obstet Gynecol* 2010;49(3):320-326]

**Key Words:** chromosome 7, chromosome 13, Dandy-Walker malformation, monosomy 13q, microcephaly, trisomy 7p

## Introduction

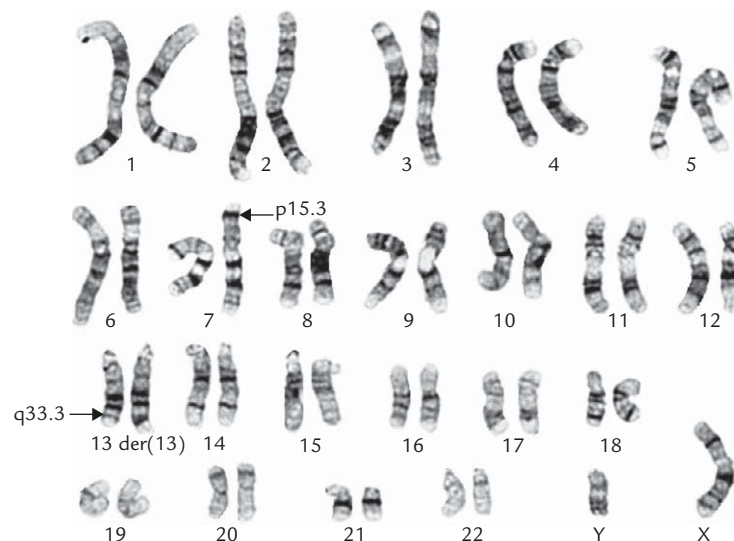
Prenatal diagnosis of a *de novo* unbalanced reciprocal translocation involving chromosomal segments with subtle difference in banding gives rise to difficulties in interpretation and genetic counseling. Diagnosis also requires molecular cytogenetic techniques such as spectral karyotyping (SKY), fluorescence *in situ* hybridization (FISH) and array-based comparative genomic hybridization (aCGH) to identify the nature of the aberrant chromosome. Here, we report prenatal diagnosis and molecular cytogenetic characterization of *de novo* partial trisomy 7p (7p15.3→pter) and partial monosomy 13q (13q33.3→qter) presenting with Dandy-Walker malformation (DWM), abnormal skull development, microcephaly, nuchal edema, and transposition of the great arteries as salient prenatal sonographic findings in the second trimester.

## Materials, Methods and Results

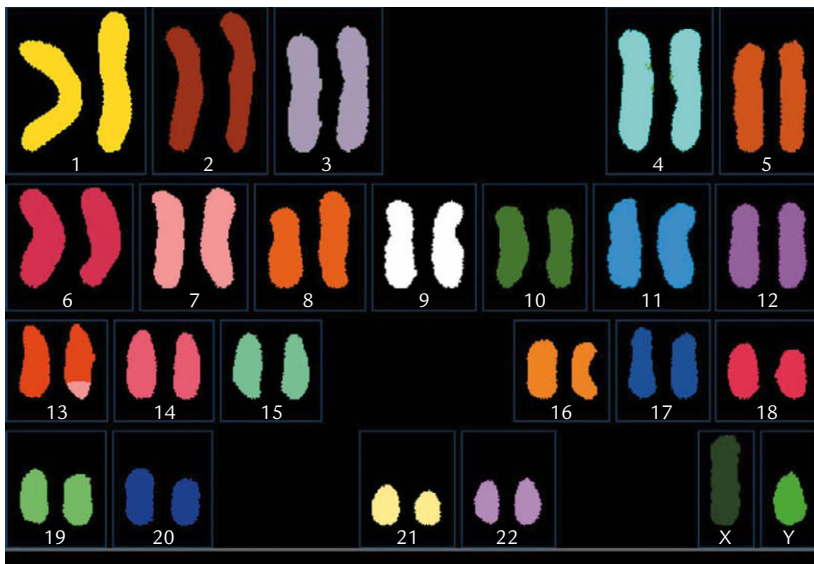
A 42-year-old woman, gravida 6, para 1, was referred to our hospital for amniocentesis at 18 weeks of gestation because of her advanced maternal age. The woman had experienced three spontaneous abortions and one artificial abortion. She had a 1½-year-old phenotypically normal son. Her husband was 43 years old.

Amniocentesis revealed an aberrant derivative chromosome 13, or der(13) (Figure 1). Chromosomal preparations of the blood lymphocytes from the parents revealed normal karyotypes. The derivative chromosome was characterized by SKY using 24-color SKY probes (Applied Spectral Imaging, Carlsbad, CA, USA) and by FISH using DNA probe mixtures containing the 6p, 6q, 7p, 7q, 13q, and 14q subtelomeric probes (TelVysion, Downers Grove, IL, USA) and whole-chromosome paint 7 (CytoCell, Adderbury, UK). SKY analysis revealed that the der(13) contained a segment of chromosome 7 in the distal end of the long arm of chromosome 13 (Figure 2). The FISH analyses showed that the chromosome 7 segment in the distal end of the long arm of chromosome 13 was of 7p in origin and the distal end of 13q was deleted (Figure 3).

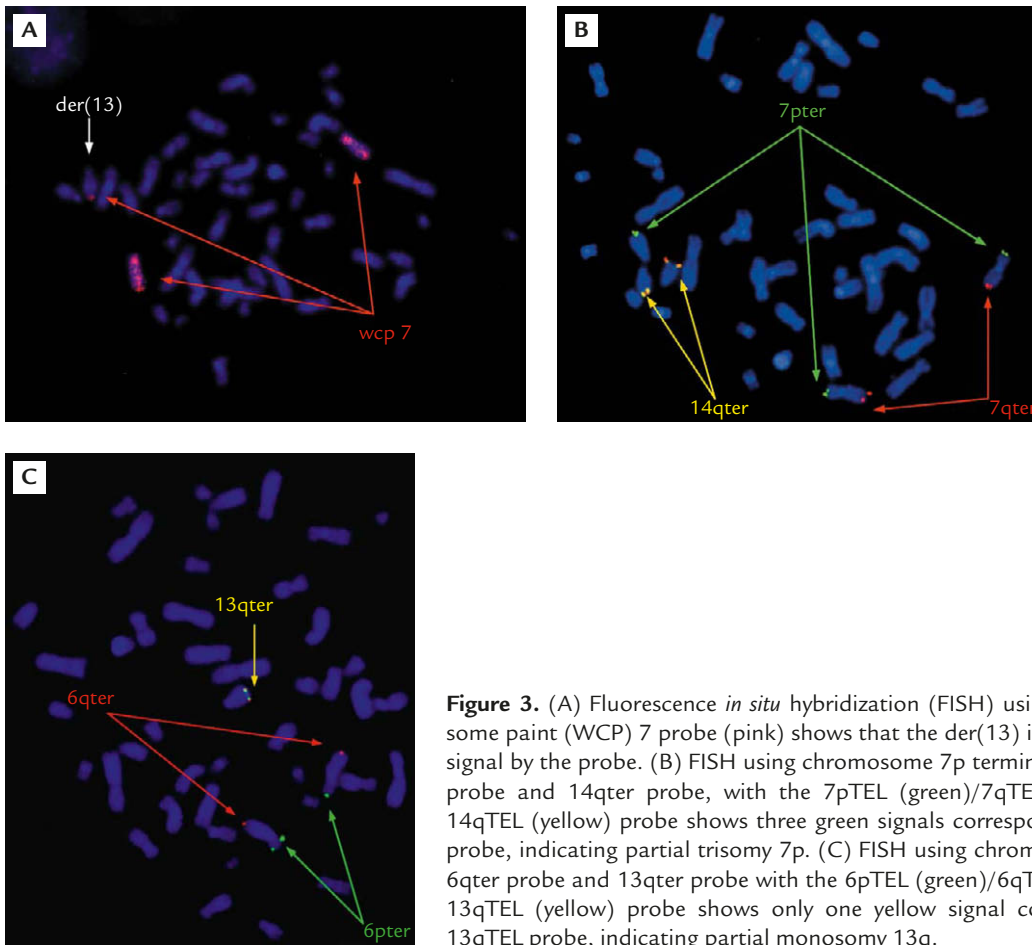
Level II ultrasound at 24 weeks of gestation showed microcephaly with a biparietal diameter and a head circumference less than the 5<sup>th</sup> centile, an irregular-shaped skull, DWM, nuchal edema, and transposition of the great arteries (Figure 4). The parents opted to terminate the pregnancy. A 568 g malformed male fetus was delivered with a sloping forehead, trigonocephaly, a large anterior fontanelle, prominent sutures, hypertelorism, short palpebral fissures, a short nose with a broad nasal bridge, a small mouth, micrognathia, a long philtrum, large low-set ears, clenched hands with flexion deformity of the fingers, overriding the fifth toe of the right



**Figure 1.** The G-banded karyotype shows a derivative chromosome 13, or der(13). Arrows indicate the breakpoints.



**Figure 2.** Spectral karyotyping using 24-color probes shows that the der(13) is due to a translocation between chromosomes 7 and 13.



**Figure 3.** (A) Fluorescence *in situ* hybridization (FISH) using a whole chromosome paint (WCP) 7 probe (pink) shows that the der(13) is stained with a pink signal by the probe. (B) FISH using chromosome 7p terminal (ter) probe, 7qter probe and 14qter probe, with the 7pTEL (green)/7qTEL (red) probes and 14qTEL (yellow) probe shows three green signals corresponding to the 7pTEL probe, indicating partial trisomy 7p. (C) FISH using chromosome 6pter probe, 6qter probe and 13qter probe with the 6pTEL (green)/6qTEL (red) probes and 13qTEL (yellow) probe shows only one yellow signal corresponding to the 13qTEL probe, indicating partial monosomy 13q.

foot, and overriding the third and the fifth toes of the left foot secondary to short metatarsal bones (Figure 5). The external genitalia were unremarkable.

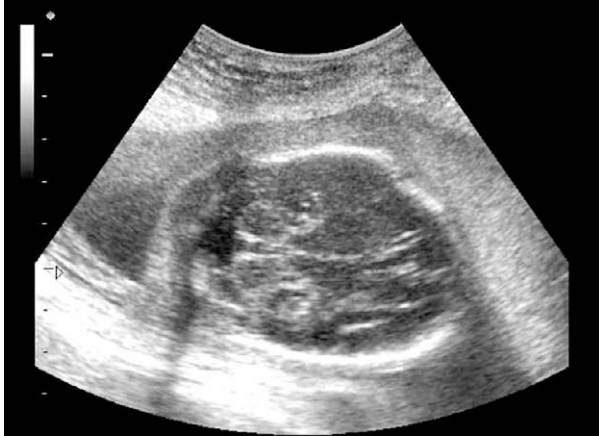Bacterial artificial chromosome (BAC)-based aCGH of fetal DNA using CMDX CA2500 chips (CMDX, Irvine, CA, USA) demonstrated partial trisomy 7p and partial monosomy 13q [arr cgh 7p22.3p15.3 (RP11-90P13→

RP11-34M9)×3, 13q33.3q34 (RP11-313L9→RP11-450H16)×1] (Figure 6). The karyotype was 46,XY,der(13)t(7;13)(p15.3;q33.3) (Figure 1). Oligonucleotide-based aCGH using HumanCytoSNP-12vl BeadChips (Illumina, San Diego, CA, USA) showed a 19.9-Mb duplication of distal 7p and a 7.38-Mb deletion of distal 13q (Figure 7). Quantitative fluorescent polymerase

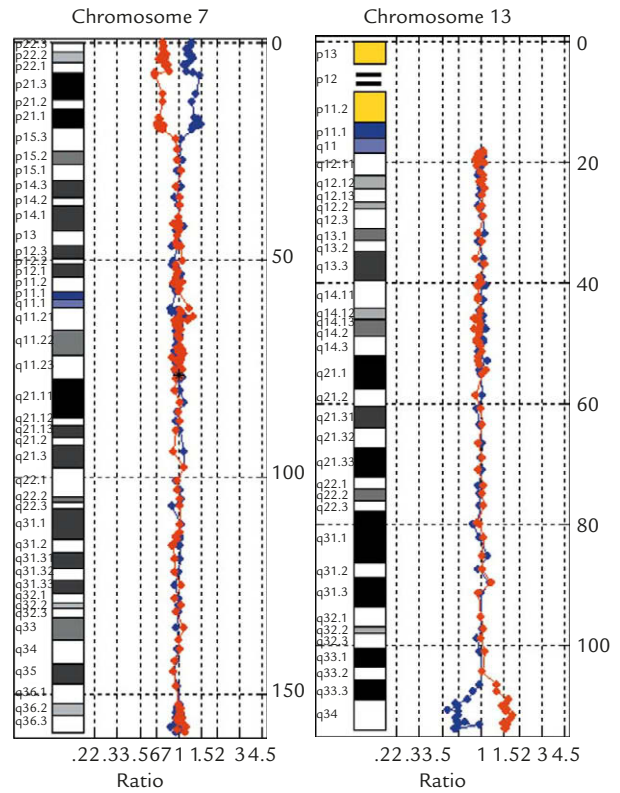
chain reaction using specific short tandem-repeat polymorphic DNA markers determined the paternal origin of the aberrant derivative chromosome.

### Discussion

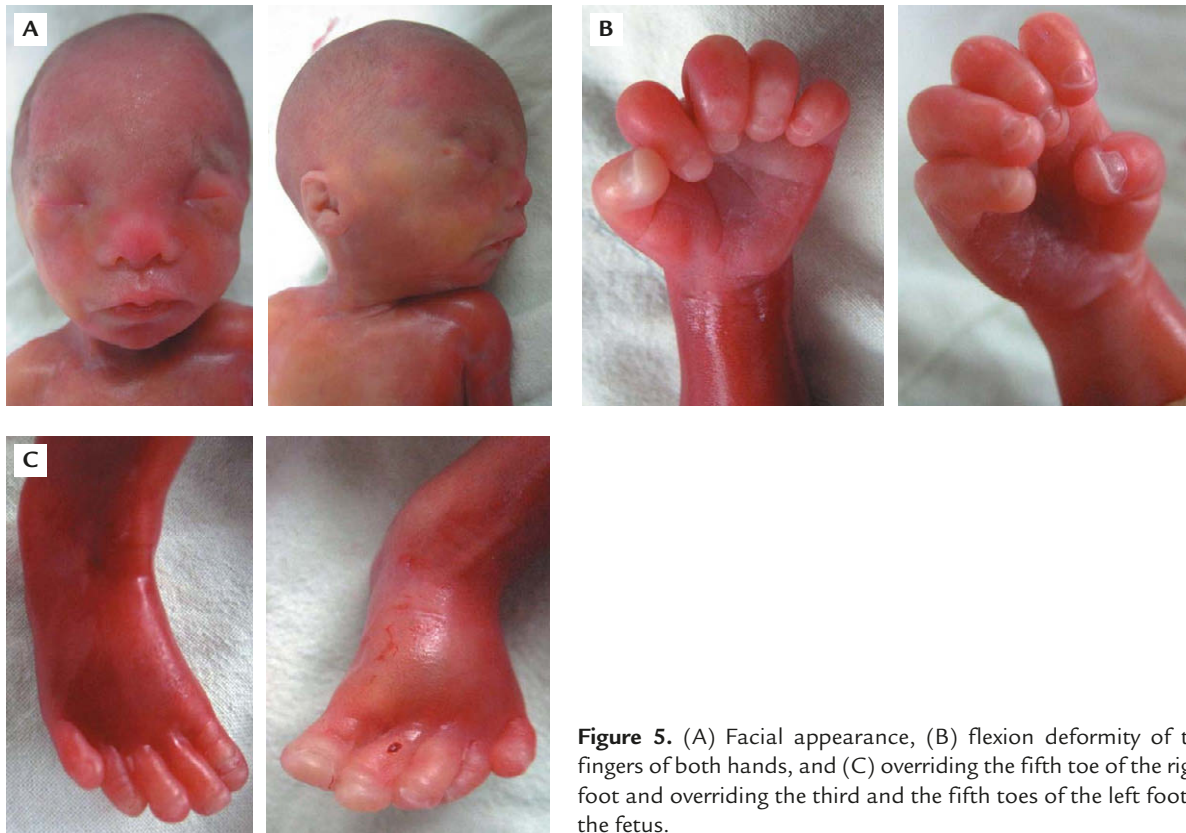
We previously reported the usefulness of SKY and FISH to identify a small supernumerary marker chromosome [1]. In the present case, we also demonstrate the utility of SKY and FISH to identify a *de novo* aberrant



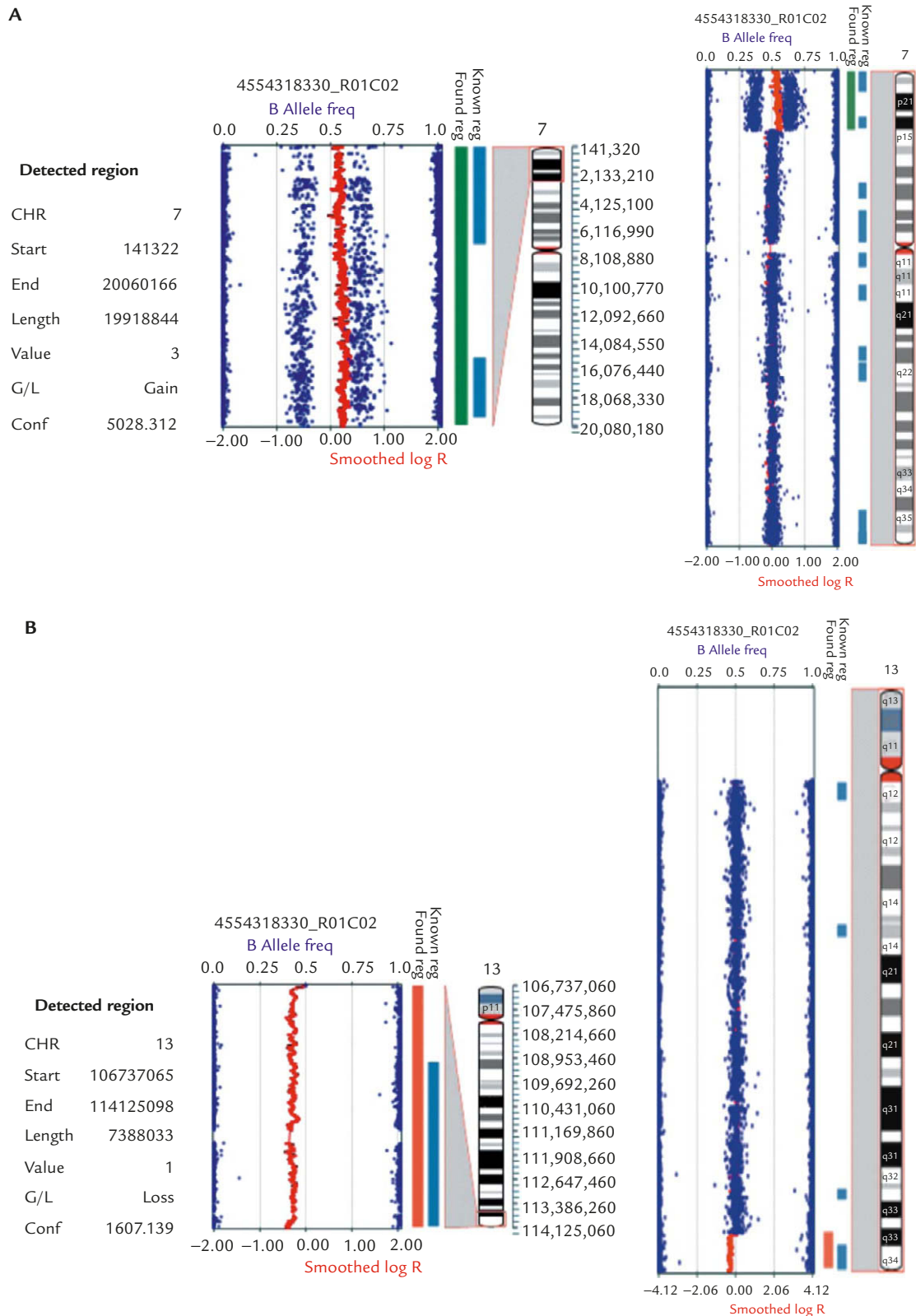
**Figure 4.** Prenatal ultrasound at 24 weeks of gestation shows an irregular shape of the skull, Dandy-Walker malformation, an enlarged cisterna magna, and hypoplasia of cerebellar vermis.



**Figure 6.** Bacterial artificial chromosome based-array comparative genomic hybridization shows a duplication of distal 7p [arr cgh 7p22.3p15.3 (RP11-90P13→RP11-34M9)×3] and a deletion of distal 13q [arr cgh 13q33.3q34 (RP11-313L9→RP11-450H16)×1].



**Figure 5.** (A) Facial appearance, (B) flexion deformity of the fingers of both hands, and (C) overriding the fifth toe of the right foot and overriding the third and the fifth toes of the left foot in the fetus.



**Figure 7.** Oligonucleotide-based array comparative genomic hybridization shows (A) a 19.9-Mb duplication in 7p22.3→7p15.3 [arr cgh 7p22.3p15.3 (141,322-20,060,166)×3] and (B) a 7.38-Mb deletion of 13q33.3→13q34 [arr cgh 13q33.3q34 (106,737,065-114,125,098)×1].

chromosome derived from an unbalanced reciprocal translocation.

The present case had an irregular-shaped skull and a large fontanelle. Delayed closure of the large fontanelle and prominent sutures are characteristic clinical features of partial trisomy 7p [2,3]. The present case had partial trisomy 7p (7p15.3→pter) with a triple dose of the *TWIST* gene. The *TWIST* gene is localized to chromosome 7p21.1 and encodes a transcription factor containing a basic helix-loop-helix domain. Mutations or haploinsufficiency of the *TWIST* gene will cause craniosynostosis [4–6]. By contrast, the increased gene dosage effect of the *TWIST* gene may cause delayed closure of the large fontanelle and abnormal skull development [7–9].

The present case had DWM, microcephaly, and nuchal edema. Chromosome 13q deletions have been associated with DWM, microcephaly, and nuchal edema. McCormack et al [10] reported two patients with del(13q21-q23) and del(13q22-q33), and multiple congenital anomalies including holoprosencephaly and DWM. Gul et al [11] reported prenatal diagnosis of del(13)(13q31.2/32.1→qter) in a fetus with intrauterine growth restriction, DWM, microcephaly, right microphthalmia, micrognathia, marked nuchal edema, oligodactyly, thumb aplasia, and ambiguous genitalia. Alanay et al [12] reported prenatal diagnosis of del(13)(q14→qter) in a fetus with intrauterine growth restriction, DWM, and bilaterally absent thumbs and first toes. Ballarati et al [13] reported three patients with DWM and 13q deletions, including del(13)(q22.3-q33.2), del(13)(q31.1-qter) and del(13)(q32.2-qter), and found that the minimal deletion interval associated with DWM was limited to the 13q32.2-q33.2 region in which the *ZIC2* and *ZIC5* genes are located. Hindryckx et al [14] reported a first-trimester diagnosis of del(13)(q31.1-q33.1) in a fetus with increased nuchal translucency, DWM, a small parietal encephalocele, agenesis of the corpus callosum, mild renal dysplasia, and the absence of lobulation of the lungs. In a study of 14 patients with partial deletion of 13q, Kirchhoff et al [15] refined the smallest deletion linked to short stature (13q31.3), microcephaly (13q33.3-q34), cortical development malformations (13q33.1-qter), DWM (13q32.2-q33.1), corpus callosum agenesis (13q32.2-q33.1), meningocele/enkephalocele (13q31.3-qter), DWM, corpus callosum and neural tube defects taken together (13q32.3-q33.1), anophthalmia/microphthalmia (13q31.3-qter), cleft lip/palate (13q31.3-q33.1), lung hypoplasia (13q31.3-q33.1), and thumb aplasia/hypoplasia (13q31.3-q33.1 and 13q33.3-q34). In the present case, the deletion of 13q33.3-qter was associated with the phenotypic features of microcephaly, but was outside the minimal

deleted segment of 13q32.3-q33.1 for DWM. Walczak-Sztulpa et al [16] suggested that haploinsufficiency of the *ARHGEF7* gene in patients with chromosome deletions in 13q33-q34 is responsible for mental retardation and microcephaly. *ARHGEF7* maps to 13q34 and encodes p guanine nucleotide exchange factor 7. Mutations in other p guanine nucleotide exchange factors such as *ARHGEF6* and *ARHGEF9* have been reported to be associated with X-linked mental retardation [17,18].

Partial trisomy 7p is associated with a characteristic craniofacial phenotype of dolichocephaly or brachycephaly, large fontanelles, large low-set malformed ears, hypertelorism, down-slanting palpebral fissures, a high or prominent forehead, a broad or prominent nasal bridge, micrognathia, and high arch palate [8,19–25]. Reish et al [23] restricted the critical region for this phenotype to 7p15→pter. In a review of 37 cases with partial trisomy 7p, Kozma et al [26] found hydrocephalus in seven cases (19%), other central nervous system anomalies in 13 cases (35%), cardiac anomalies in 16 cases (43%) and foot deformities in 18 cases (49%). Prenatal diagnosis of partial trisomy 7p is uncommon. Witters et al [27] reported prenatal diagnosis of partial trisomy 7p (7p22.1→pter) and partial monosomy 18p (18p11.22→pter) in a fetus with nuchal edema. Ozgun et al [28] reported prenatal diagnosis of partial trisomy 7p (7p15.3→pter) and partial monosomy 9p (9p24→pter) in a fetus with corpus callosum agenesis, an enlarged left kidney, single umbilical artery, hypertelorism, a depressed nasal bridge, frontal bossing, irregular maxillar alveolar composition, club feet, flexion deformity of the upper extremities, and Epstein anomaly. Chen et al [29] reported Dandy-Walker variant in a boy with partial trisomy 7p (7p21.2→pter) and partial monosomy 12q (12q24.33→qter). The present case also provides evidence that DWM is associated with partial trisomy 7p (7p15.3→pter).

## Acknowledgments

This work was supported by research grants NSC-96-2314-B-195-008-MY3 and NSC-97-2314-B-195-006-MY3 from the National Science Council, and MMH-E-99004 from Mackay Memorial Hospital, Taipei, Taiwan.

## References

1. Chen CP, Lin CC, Su YN, et al. Prenatal diagnosis and molecular cytogenetic characterization of a small supernumerary marker chromosome derived from chromosome 18 and

- associated with a reciprocal translocation involving chromosomes 17 and 18. *Taiwan J Obstet Gynecol* 2010;49:188–91.
2. Fryns JP. Chromosome 7, trisomy 7p2. In: Buyse ML, ed. *British Defects Encyclopedia*. Cambridge: Blackwell Scientific Publications, 1990;348–9.
  3. Schinzel A. *Catalogue of Unbalanced Chromosome Aberrations in Man*. Berlin: de Gruyter, 2001;321–327, 397–408.
  4. el Ghouzzi V, Le Merrer M, Perrin-Schmitt F, et al. Mutations of the *TWIST* gene in the Saethre-Chotzen syndrome. *Nat Genet* 1997;15:42–6.
  5. Howard TD, Paznekas WA, Green ED, et al. Mutations in *TWIST*, a basic helix-loop-helix transcription factor, in Saethre-Chotzen syndrome. *Nat Genet* 1997;15:36–41.
  6. Johnson D, Horsley SW, Moloney DM, et al. A comprehensive screen for *TWIST* mutations in patients with craniosynostosis identifies a new microdeletion syndrome of chromosome band 7p21.1. *Am J Hum Genet* 1998;63:1282–93.
  7. Mégarbané A, Le Lorc'H M, Elghezal H, et al. Pure partial 7p trisomy including the *TWIST*, *HOXA*, and *GLI3* genes. *J Med Genet* 2001;38:178–82.
  8. Stankiewicz P, Thiele H, Baldermann C, et al. Phenotypic findings due to trisomy 7p15.3-pter including the *TWIST* locus. *Am J Med Genet* 2001;103:56–62.
  9. Chen CP, Lin SP, Lin CC, et al. Spectral karyotyping, fluorescence *in situ* hybridization and molecular genetic analysis of *de novo* partial trisomy of 7p (7p15.1→pter) and partial monosomy 9p (9p22→pter). *Prenat Diagn* 2005;25:1170–2.
  10. McCormack WM Jr, Shen JJ, Curry SM, et al. Partial deletions of the long arm of chromosome 13 associated with holoprosencephaly and the Dandy-Walker malformation. *Am J Med Genet* 2002;112:384–9.
  11. Gul A, Cebeci A, Erol O, Ceylan Y, Basaran S, Yuksel A. Prenatal diagnosis of 13q-syndrome in a fetus with Dandy-Walker malformation. *Obstet Gynecol* 2005;105:1227–9.
  12. Alanay Y, Aktas D, Utine E, Talim B, Önderoglu L, Çağlar M, Tunçbilek E. Is Dandy-Walker malformation associated with “distal 13q deletion syndrome”? Findings in a fetus supporting previous observations. *Am J Med Genet* 2005;136A:265–8.
  13. Ballarati L, Rossi E, Bonati MT, et al. 13q Deletion and central nervous system anomalies: further insights from karyotype-phenotype analyses of 14 patients. *J Med Genet* 2007;44:e60.
  14. Hindryckx A, De Catte L, Van Esch H, et al. First trimester prenatal diagnosis of 13q-syndrome presenting with increased nuchal translucency, Dandy-Walker malformation and small parietal encephalocoele. *Prenat Diagn* 2008;28:445–6.
  15. Kirchhoff M, Bisgaard AM, Stoeva R, et al. Phenotype and 244k array-CGH characterization of chromosome 13q deletions: an update of the phenotypic map of 13q21.1-qter. *Am J Med Genet* 2009;149A:894–905.
  16. Walczak-Sztulpa J, Wisniewska M, Latos-Bielenska A, et al. Chromosome deletions in 13q33-34: report of four patients and review of the literature. *Am J Med Genet* 2008;146A:337–42.
  17. Kutsche K, Yntema H, Brandt A, et al. Mutations in *ARHGEF6*, encoding a guanine nucleotide exchange factor for Rho GTPases, in patients with X-linked mental retardation. *Nat Genet* 2000;26:247–50.
  18. Harvey K, Duguid IC, Alldred MJ, et al. The GDP-GTP exchange factor collybistin: An essential determinant of neuronal gephyrin clustering. *J Neurosci* 2004;24:5816–26.
  19. Milunsky JM, Wyandt HE, Milunsky A. Emerging phenotype of duplication (7p): a report of three cases and review of the literature. *Am J Med Genet* 1989;33:364–8.
  20. Kleczkowska A, Decock P, van den Berghe H, Fryns JP. Borderline intelligence and discrete craniofacial dysmorphism in an adolescent female with partial trisomy 7p due to a *de novo* tandem duplication 7 (p15.1→p21.3). *Genet Couns* 1994;5:393–7.
  21. Lurie IW, Schwartz MF, Schwartz S, Cohen MM. Trisomy 7p resulting from isochromosome formation and whole-arm translocation. *Am J Med Genet* 1995;55:62–6.
  22. Pallotta R, Dalprà L, Fusilli P, Zuffardi O. Further delineation of 7p trisomy. Case report and review of literature. *Ann Genet* 1996;39:152–8.
  23. Reish O, Berry SA, Dewald G, King RA. Duplication of 7p: further delineation of the phenotype and restriction of the critical region to the distal part of the short arm. *Am J Med Genet* 1996;61:21–5.
  24. Cai T, Yu P, Tagle DA, Xia J. Duplication of 7p21.2→pter due to maternal 7p;21q translocation: implications for critical segment assignment in the 7p duplication syndrome. *Am J Med Genet* 1999;86:305–11.
  25. Arens YH, Toutain A, Engelen JJ, et al. Trisomy 7p: report of 2 patients and literature review. *Genet Couns* 2000;11:347–54.
  26. Kozma C, Haddad BR, Meck JM. Trisomy 7p resulting from 7p15;9p24 translocation: report of a new case and review of associated medical complications. *Am J Med Genet* 2000;91:286–90.
  27. Witters I, Moerman P, Fryns JP. Maternal serum positive triple test screening in a fetus with partial distal trisomy 7p associated with maternal 7p;18p translocation. *Genet Couns* 2002;13:65–8.
  28. Ozgun MT, Batukan C, Basbug M, Akgun H, Caglayan O, Dundar M. Prenatal diagnosis of a fetus with partial trisomy 7p. *Fetal Diagn Ther* 2007;22:229–32.
  29. Chen CP, Lin SP, Lin CC, et al. Spectral karyotyping and fluorescence *in situ* hybridization of *de novo* partial trisomy of 7p (7p21.2→pter) and partial monosomy 12q (12q24.33→qter). *Genet Couns* 2006;17:57–63.