Ellis-van Creveld Syndrome: Prenatal Diagnosis, Molecular Analysis and Genetic Counseling

Chih-Ping Chen[1,2,3,4,5,6]*, Yi-Ning Su[7], Chin-Yuan Hsu[1], Schu-Rern Chern[2], Fuu-Jen Tsai[4,8], Pei-Chen Wu[1], Po-Tsang Chen[2], Wayseen Wang[2,9]

Departments of [1]Obstetrics and Gynecology and [2]Medical Research, Mackay Memorial Hospital, [5]Institute of Clinical and Community Health Nursing, [6]Department of Obstetrics and Gynecology, National Yang-Ming University, [7]Department of Medical Genetics, National Taiwan University Hospital, and [9]Department of Bioengineering, Tatung University, Taipei; [3]Department of Biotechnology, Asia University, [4]School of Chinese Medicine, College of Chinese Medicine, China Medical University, and [8]Departments of Medical Genetics and Medical Research, China Medical University Hospital, Taichung, Taiwan.

SUMMARY

Objective: To present the perinatal findings and molecular genetic analysis of two siblings with Ellis-van Creveld (EvC) syndrome.

Materials, Methods and Results: A 33-year-old woman, gravida 3, para 1, was referred for genetic counseling at 18 gestational weeks because of recurrent fetal skeletal dysplasia. Two years previously, she had delivered a 1,316-g dead male baby at 28 gestational weeks with a karyotype of 46,XY, postaxial polydactyly of the hands, thoracic narrowness, endocardial cushion defects, transposition of the great arteries, shortening of the long bones, malposition of the toes, and hypoplastic nails. During this pregnancy, prenatal ultrasound at 18 gestational weeks revealed shortening of the long bones (equivalent to 15 weeks), postaxial polydactyly of both hands, thoracic narrowness, and endocardial cushion defects. The pregnancy was subsequently terminated, and a 236-g female fetus was delivered with a karyotype of 46,XX, postaxial polydactyly of the hands, thoracic dysplasia, endocardial cushion defects, shortening of the long bones, and malposition of the toes and hypoplastic nails. The phenotype of each of the two siblings was consistent with EVC syndrome. Molecular analysis of the *EVC* and *EVC2* genes revealed heterozygous mutations in the *EVC2* gene. A heterozygous deletion mutation of a 26-bp deletion of c.871-2_894del26 encompassing the junction between intron 7 and exon 8 of the *EVC2* gene was found in the mother and two siblings, and a heterozygous nonsense mutation of c.1195C>T, p.R399X in exon 10 of the *EVC2* gene was found in the father and two siblings.

Conclusion: Prenatal sonographic identification of endocardial cushion defects in association with shortening of the long bones should alert clinicians to the possibility of EvC syndrome and prompt a careful search of hexadactyly of the hands. Molecular analysis of the *EVC* and *EVC2* genes is helpful in genetic counseling in cases with prenatally detected postaxial polydactyly, thoracic narrowness, short limbs and endocardial cushion defects. [*Taiwan J Obstet Gynecol* 2010;49(4):481–486]

Key Words: Ellis-van Creveld syndrome, *EVC*, *EVC2*, prenatal diagnosis, ultrasound

Introduction

Ellis-van Creveld (EvC) syndrome (OMIM 225500), or chondroectodermal dysplasia, is an autosomal recessive ciliary disorder associated with a wide spectrum of developing abnormalities involving the ectoderm, skeleton and heart. EvC syndrome is a relatively rare

*Correspondence to: Dr Chih-Ping Chen, Department of Obstetrics and Gynecology, Mackay Memorial Hospital, 92, Section 2, Chung-Shan North Road, Taipei, Taiwan.
E-mail: cpc_mmh@yahoo.com
Accepted: September 29, 2010

disorder, but is most prevalent in the Amish population [1,2] and in some Arab populations [3] because of consanguinity. The birth prevalence is estimated to be 0.7 per 100,000 of live births in the non-Amish population [4], 5.2 per 100,000 of live births in the United Arab Emirates [3], and 5 per 1,000 of live births in the Amish of Lancaster County, Pennsylvania, USA [5]. EvC syndrome is characterized by short ribs, short limbs, postaxial polydactyly of the hands, polydactyly of the feet (in 10% of cases), ectodermal dysplasia such as dysplastic nails and teeth, sparse hair and an absent gingival sulcus, and congenital heart defects (in 60% of cases) such as a common atrium, atrioventricular septal defects (AVSDs) and patent ductus arteriosus [6,7]. EvC syndrome is caused by mutations in the *EVC* gene (OMIM 604831) [8] or *EVC2* gene (OMIM 607261) [9] that encodes cilia-related proteins Evc or Evc2, respectively. Mutations in the *EVC* gene or *EVC2* gene may also cause Weyers acrodental dysostosis (OMIM 193530), an autosomal dominant disorder characterized by postaxial polydactyly and abnormalities of the lower jaw, dentition and oral vestibule. The Evc and Evc2 proteins are localized in the basal bodies of primary cilia. Evc is a basal body component of hedgehog signaling indispensable for normal endochondral growth and normal transcriptional activation of Indian hedgehog-regulated genes [10]. Both EvC syndrome and Weyers acrodental dysostosis are caused by hedgehog signaling defects in the primary cilia due to mutations in the cilia-related proteins resulting in an aberrant response to the hedgehog ligands [7]. We previously reported perinatal findings of hexadactyly-associated ciliary disorders of Meckel syndrome [11], Joubert syndrome [12], and short rib-polydactyly syndrome (SRPS) [13–16]. We present the perinatal findings and molecular genetic analysis of two siblings affected by hexadactyly and EvC syndrome.

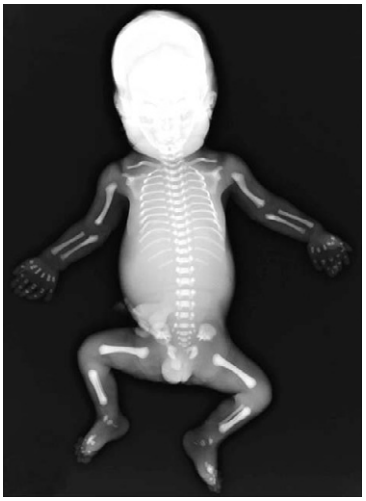

Figure 1. Whole body X-ray of proband 1 at 28 gestational weeks.

Materials, Methods and Results

A 33-year-old woman, gravida 3, para 1, was referred for genetic counseling at 18 gestational weeks because of recurrent fetal skeletal dysplasia. She and her husband were non-consanguineous. She had experienced one spontaneous abortion and delivered a baby with skeletal dysplasia. Two years previously, she had delivered a 1,316-g dead male baby (proband 1) at 28 gestational weeks with a karyotype of 46,XY, postaxial polydactyly of the hands, thoracic narrowness, endocardial cushion defects, transposition of the great arteries (TGA), shortening of the long bones, malposition of the toes and hypoplastic nails (Figures 1–3). During this pregnancy, prenatal ultrasound at 18 gestational weeks revealed shortening of the long bones (equivalent to 15 weeks), postaxial polydactyly of both hands, thoracic narrowness, and endocardial cushion defects (Figures 4–6). The pregnancy was subsequently terminated, and a 236-g female fetus (proband 2) was delivered with a karyotype of 46,XX, postaxial polydactyly of the hands, thoracic dysplasia, endocardial

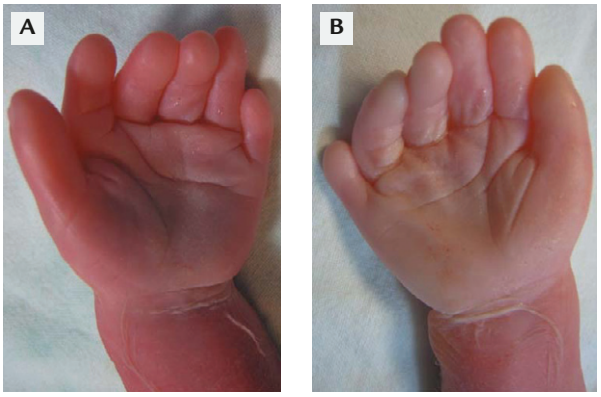

Figure 2. Postaxial polydactyly of the hands in proband 1.

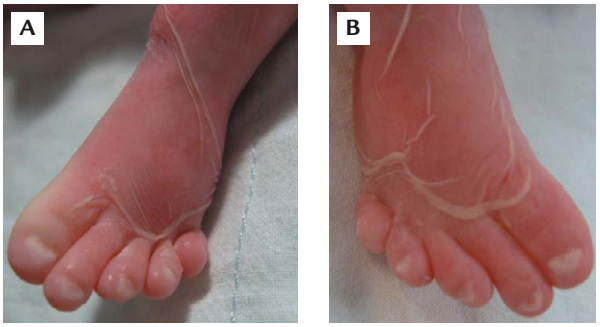

Figure 3. Malposition of the toes with hypoplastic nails in proband 1.

cushion defects, shortening of the long bones, malposition of the toes and hypoplastic nails (Figures 7–10). The phenotype of each of the two siblings is consistent with EvC syndrome. Molecular analysis of the *EVC* and *EVC2* genes showed heterozygous mutations in the *EVC2* gene. A heterozygous deletion mutation of a 26-bp deletion of c.871-2_894del26 encompassing the junction between intron 7 and exon 8 of the *EVC2* gene was found in the mother and two siblings, and a heterozygous nonsense mutation of c.1195C>T, p.R399X

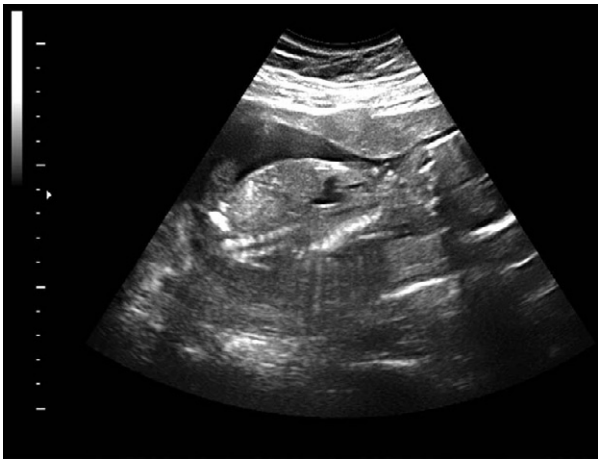

Figure 4. Prenatal ultrasound shows thoracic narrowness in proband 2.

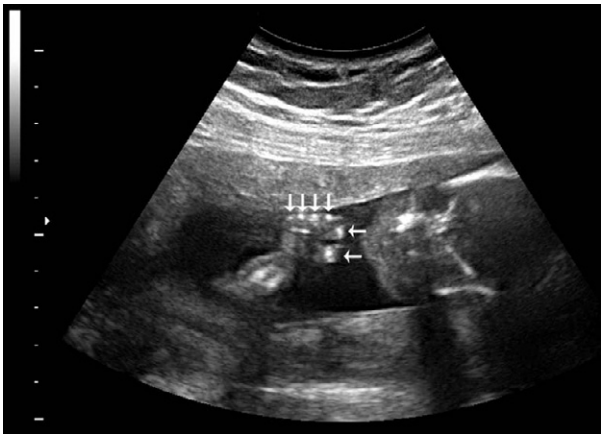

Figure 5. Prenatal ultrasound shows hexadactyly of the hands in proband 2.

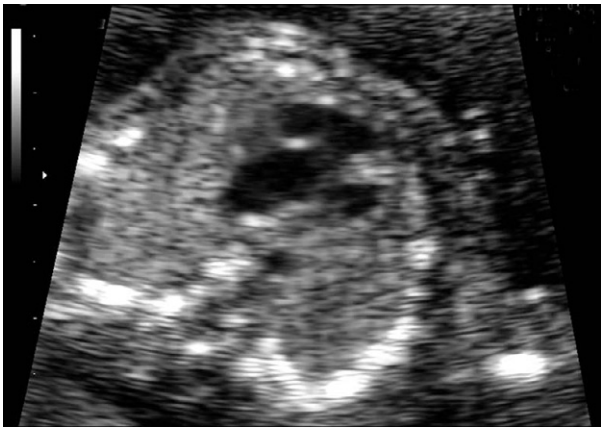

Figure 6. Prenatal ultrasound shows endocardial cushion defects in proband 2.

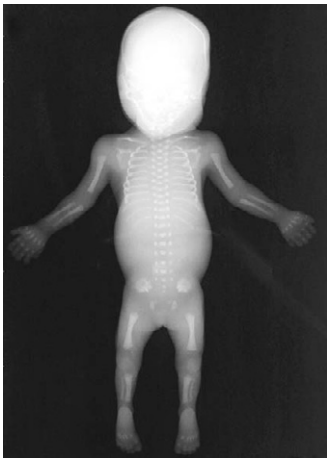

Figure 7. Whole body X-ray of proband 2 at 18 gestational weeks.

Figure 8. Proband 2 at birth.

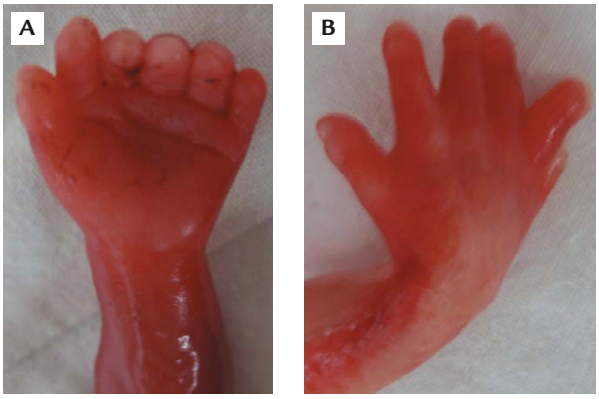

Figure 9. Postaxial polydactyly of the hands in proband 2.

Figure 10. Malposition of the toes with hypoplastic nails in proband 2.

in exon 10 of the *EVC2* gene was found in the father and two siblings (Figure 11).

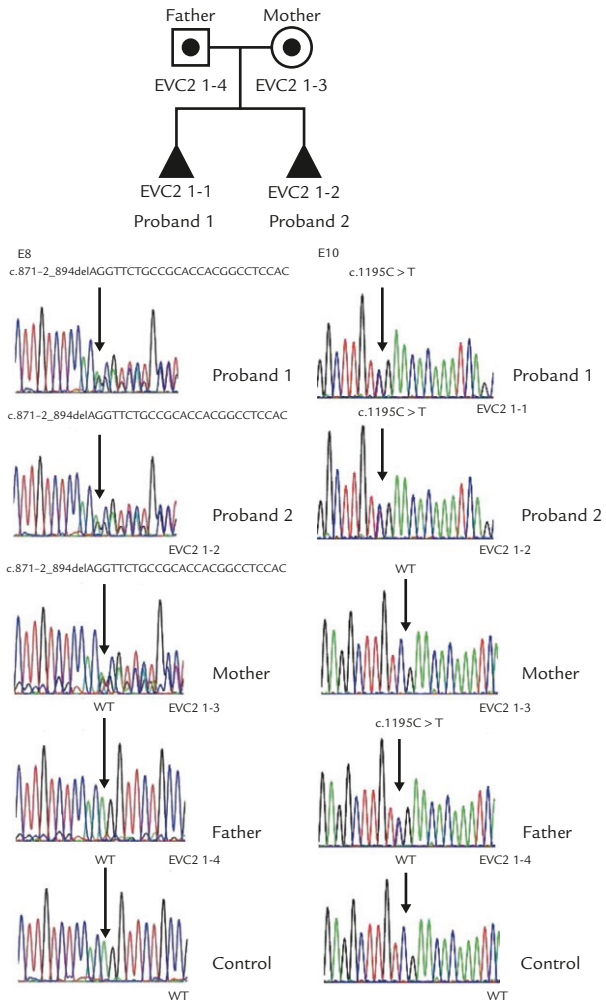

Figure 11. A heterozygous deletion mutation of the 26-bp deletion encompassing the junction between intron 7 and exon 8 of the *EVC2* gene (c.871-2_894del26) in proband 1, proband 2 and the mother, but not in the father, and a heterozygous nonsense mutation in exon 10 of the *EVC2* gene (c.1195C > T, CGA > TGA, Arg399Stop, R399X) in proband 1, proband 2 and the father, but not in the mother. WT = wild type.

Discussion

The present case prenatally manifested shortening of the long bones, thoracic dysplasia, hexadactyly of the hands, and AVSD on the second-trimester ultrasound. Prenatal diagnosis of EvC syndrome by direct visualization of the fetus using fetoscopy has previously been reported [17,18]. First-trimester transabdominal embryofetoscopy for the detection of limb or facial abnormalities has recently been applied to detect skeletal dysplasia such as SRPS [19]. Recurrent EvC syndrome can be diagnosed in the first trimester by the ultrasound findings of AVSD, polydactyly and short limbs [20] as well as increased fetal nuchal translucency thickness [21]. In the second trimester, the diagnosis of EvC syndrome can be made based on a positive family history and the ultrasound findings of shortness of the long bones, hexadactyly of the hands, a narrow thorax and congenital heart defects, especially abnormalities of atrial septation and AVSD [22–28].

Our first proband manifested AVSD and TGA, and our second proband manifested AVSD on prenatal ultrasound. Congenital heart defects occur in approximately 60% of patients with EvC syndrome with most patients being variants of AVSD [1]. Atrioventricular septation of the mammalian heart into four chambers requires sonic hedgehog signaling-dependent cellular contributions from the extracardiac tissues of the dorsal mesocardium as well as contributions from the muscular and mesenchymal atrial septum and the endocardial cushions [29]. Sund et al [30] found that the expression of *EVC* and *EVC2* mRNA and proteins was high in the outflow tract and dorsal mesenchymal protrusion and was also present in the mesenchymal structures of the atrial septum and the endocardial cushions. This finding suggested that Evc and Evc2 proteins function coordinately in cardiac development and that loss of this coordinate function results in characteristic EvC syndrome.

In the present case, we identified heterozygous *EVC2* mutations in the affected fetuses. The nonsense mutation of C1195T, R399X, has been described previously [31]. However, the deletion mutation of c.871-2_894del26 is novel. Sequencing the *EVC* and *EVC2* genes has been reported to identify mutations in only two-thirds of EvC patients, indicating the possibility of genetic heterogeneity in EvC syndrome [32]. In a study of 65 individuals with EvC syndrome, Tompson et al

[32] identified *EVC* mutations in 20 cases (31%), all of whom had mutations on each allele, found *EVC2* mutations in 25 cases (38%), 22 of whom had mutations on each allele, and three had only one mutation, and there was no mutation in either gene in 20 cases (31%). The three patients in their study with an *EVC2* mutation on only one allele had a frameshift or a nonsense codon and a more severe phenotype than Weyers acrodental dysostosis.

There is a risk of 25% recurrence in subsequent pregnancies in fetal EvC syndrome. Genetic counseling of fetal EvC syndrome should include differential diagnoses of SRPS, Jeune asphyxiating thoracic dystrophy (JATD), and McKusick-Kaufman syndrome (MKKS). SRPSs are a heterogeneous group of lethal autosomal recessive skeletal dysplasias. Four types of SRPS have been recognized [33]. Type I SRPS (Saldino-Noonan) (OMIM 263530) is characterized by flipper-like extremities, polydactyly, polycystic kidneys and pointed metaphyses. Type II SRPS (Majewski) (OMIM 263520) is characterized by polydactyly, micromelia, cleft lip/palate, polycystic kidneys, a disproportionately short ovoid tibia and occasionally hypoplastic epiglottis and larynx. Type III SRPS (Verma-Naumoff) (OMIM 263510) is characterized by polydactyly, micromelia, metaphyseal spurs and occasionally situs inversus totalis. Type IV SRPS (Beemer-Langer) (OMIM 269860) clinically resembles type II SRPS other than polydactyly. Overlapping clinical and radiological manifestations have led to the hypothesis that the different subtypes may be a single genetic disorder with variable expressivity [34–37]. Type III SRPS is caused by mutations of the *DYNC2H1* gene (OMIM 603297) [38,39]. JATD (OMIM 208500) is an autosomal recessive disorder characterized by thoracic dystrophy, chondrodysplasia, short ribs, short long bones, inconstant polydactyly and a trident acetabular roof with occasional involvement of the liver, retinal degeneration, and cystic renal disease. JATD is caused by mutations of the *IFT80* gene (OMIM 611177) and *DYNC2H1* gene [38–40]. JATD and type III SRPS have been suggested to be variants of a single ciliary disorder [38]. MKKS (OMIM 236700) is an autosomal recessive disorder characterized by polydactyly, congenital heart defects, hydrometrocolpos, and it clinically overlaps with Bardet-Biedl syndrome (OMIM 209900) comprising obesity, retinitis pigmentosa, polydactyly, mental retardation, renal malformation and genital hypoplasia. MKKS and Bardet-Biedl syndrome can be caused by mutations of the *MKKS* gene (OMIM 604896) [41,42].

In summary, we have presented prenatal diagnosis, molecular analysis and genetic counseling of recurrent EvC syndrome. Prenatal sonographic identification of endocardial cushion defects in association with shortening of the long bones should alert clinicians to the possibility of EvC syndrome and prompt a careful search of hexadactyly of the hands. Molecular analysis of the *EVC* and *EVC2* genes is helpful in genetic counseling in cases with prenatally detected postaxial polydactyly, thoracic narrowness, short limbs, and endocardial cushion defects.

Acknowledgments

This work was supported by research grants NSC-96-2314-B-195-008-MY3 and NSC-97-2314-B-195-006-MY3 from the National Science Council, and MMH-E-99004 from Mackay Memorial Hospital, Taipei, Taiwan.

References

1. McKusick VA, Egeland JA, Eldridge R, Krusen DE. Dwarfism in the Amish. I. The Ellis-van Creveld syndrome. *Bull Johns Hopkins Hosp* 1964;115:306–36.
2. McKusick VA. Ellis-van Creveld syndrome and the Amish. *Nat Genet* 2000;24:203–4.
3. Al-Gazali LI, Bakir M, Hamid Z, et al. Birth prevalence and pattern of osteochondrodysplasias in an inbred high risk population. *Birth Defects Res A Clin Mol Teratol* 2003;67A:125–32.
4. Stoll C, Dott B, Roth MP, Alembik Y. Birth prevalence rates of skeletal dysplasias. *Clin Genet* 1989;35:88–92.
5. Zangwill KM, Boal DK, Ladda RL. Dandy-Walker malformation in Ellis-van Creveld syndrome. *Am J Med Genet* 1988;31:123–9.
6. Baujat G, Le Merrer M. Ellis-van Creveld syndrome. *Orphanet J Rare Dis* 2007;2:27.
7. Ruiz-Perez VL, Goodship JA. Ellis-van Creveld syndrome and Weyers acrodental dysostosis are caused by cilia-mediated diminished response to hedgehog ligands. *Am J Med Genet C Semin Med Genet* 2009;151C:341–51.
8. Ruiz-Perez VL, Ide SE, Strom TM, et al. Mutations in a new gene in Ellis-van Creveld syndrome and Weyers acrodental dysostosis. *Nat Genet* 2000;24:283–6.
9. Galdzicka M, Patnala S, Hirshman MG, Cai JF, Nitowsky H, Egeland JA, Ginns EI. A new gene, *EVC2*, is mutated in Ellis-van Creveld syndrome. *Mol Genet Metab* 2002;77:291–5.
10. Ruiz-Perez VL, Blair HJ, Rodriguez-Andres ME, et al. Evc is a positive mediator of Ihh-regulated bone growth that localises at the base of chondrocyte cilia. *Development* 2007;134: 2903–12.
11. Chen CP. Meckel syndrome: genetics, perinatal findings and differential diagnosis. *Taiwan J Obstet Gynecol* 2007;46:9–14.
12. Chen CP, Su YN, Huang JK, et al. Fetal magnetic resonance imaging demonstration of central nervous system abnormalities and polydactyly associated with Joubert syndrome. *Taiwan J Obstet Gynecol* 2010;49:243–5.
13. Chen CP, Tzen CY. Short rib-polydactyly syndrome type III (Verma-Naumoff) in a third-trimester fetus with unusual associations of epiglottic hypoplasia, renal cystic dysplasia, pyelectasia and oligohydramnios. *Prenat Diagn* 2001;21:1101–2.

14. Chen CP, Chang TY, Tzen CY, Lin CJ, Wang W. Sonographic detection of situs inversus totalis, ventricular septal defect, and short rib-polydactyly syndrome type III (Verma-Naumoff) in a second-trimester fetus not known to be at risk. *Ultrasound Obstet Gynecol* 2002;19:629–31.
15. Chen CP, Chang TY, Tzen CY, Wang W. Second-trimester sonographic detection of short rib-polydactyly syndrome type II (Majewski) following an abnormal maternal serum biochemical screening result. *Prenat Diagn* 2003;23:353–5.
16. Chen CP, Shih JC, Tzen CY, Lin YH, Wang W. Recurrent short-rib polydactyly syndrome: prenatal three-dimensional ultrasound findings and associations with congenital high airway obstruction and pyelectasia. *Prenat Diagn* 2005;25:417–8.
17. Mahoney MJ, Hobbins JC. Prenatal diagnosis of chondroectodermal dysplasia (Ellis-van Creveld syndrome) with fetoscopy and ultrasound. *N Engl J Med* 1977;297:258–60.
18. Bui TH, Marsk L, Eklöf O, Theorell K. Prenatal diagnosis of chondroectodermal dysplasia with fetoscopy. *Prenat Diagn* 1984;4:155–9.
19. Lee K, Lee JW, Chay DB, et al. Transabdominal embryofetoscopy for the detection of short rib-polydactyly syndrome, type II (Majewski), in the first trimester. *J Korean Med Sci* 2006; 21:165–8.
20. Dugoff L, Thieme G, Hobbins JC. First trimester prenatal diagnosis of chondroectodermal dysplasia (Ellis-van Creveld syndrome) with ultrasound. *Ultrasound Obstet Gynecol* 2001; 17:86–8.
21. Venkat-Raman N, Sebire NJ, Murphy KW, Carvalho JS, Hall CM. Increased first-trimester fetal nuchal translucency thickness in association with chondroectodermal dysplasia (Ellis-van Creveld syndrome). *Ultrasound Obstet Gynecol* 2005; 25:412–4.
22. Horigome H, Hamada H, Sohda S, Oyake Y, Kurosaki Y. Prenatal ultrasonic diagnosis of a case of Ellis-van Creveld syndrome with a single atrium. *Pediatr Radiol* 1997;27:942–4.
23. Guschmann M, Horn D, Gasiorek-Wiens A, Urban M, Kunze J, Vogel M. Ellis-van Creveld syndrome: estimation at 15 weeks' gestation. *Prenat Diagn* 1999;19:879–83.
24. Tongsong T, Chanprapaph P. Prenatal sonographic diagnosis of Ellis-van Creveld syndrome. *J Clin Ultrasound* 2000;28:38–41.
25. George E, DeSilva S, Lieber E, Raziuddin K, Gudavalli M. Ellis van Creveld syndrome (chondroectodermal dysplasia, MIM 22550) in three siblings from a non-consanguineous mating. *J Perinat Med* 2000;28:425–7.
26. Sergi C, Voigtlander T, Zoubaa S, et al. Ellis-van Creveld syndrome: a generalized dysplasia of enchondral ossification. *Pediatr Radiol* 2001;31:289–93.
27. Parilla BV, Leeth EA, Kambich MP, Chilis P, MacGregor SN. Antenatal detection of skeletal dysplasias. *J Ultrasound Med* 2003;22:255–8.
28. Witters I, Moerman P, Fryns JP. Skeletal dysplasias: 38 prenatal cases. *Genet Couns* 2008;19:267–75.
29. Goddeeris MM, Rho S, Petiet A, Davenport CL, Johnson GA, Meyers EN, Klingensmith J. Intracardiac septation requires hedgehog-dependent cellular contributions from outside the heart. *Development* 2008;135:1887–95.
30. Sund KL, Roelker S, Ramachandran V, Durbin L, Benson DW. Analysis of Ellis van Creveld syndrome gene products: implications for cardiovascular development and disease. *Hum Mol Genet* 2009;18:1813–24.
31. Ruiz-Perez VL, Tompson SWJ, Blair HJ, et al. Mutation in two nonhomologous genes in a head-to-head configuration cause Ellis-van Creveld syndrome. *Am J Hum Genet* 2003;72:728–32.
32. Tompson SWJ, Ruiz-Perez VL, Blair HJ, et al. Sequencing *EVC* and *EVC2* identifies mutations in two-thirds of Ellis-van Creveld syndrome patients. *Hum Genet* 2007;120:663–70.
33. Lachman RS. Skeletal dysplasia. In: Taybi H, Lachman RS, eds. *Radiology of Syndromes, Metabolic Disorders, and Skeletal Dysplasias*, 4th edition. St. Louis: Mosby, 1996:745–951.
34. Martínez-Frías M-L, Bermejo E, Urioste M, Huertas H, Arroyo I. Lethal short rib polydactyly syndromes: further evidence for their overlapping in a continuous spectrum. *J Med Genet* 1993;30:937–41.
35. Sarafoglou K, Funai EF, Fefferman N, et al. Short rib-polydactyly syndrome: more evidence of a continuous spectrum. *Clin Genet* 1999;56:145–8.
36. Ho NC, Francomano CA, van Allen M. Jeune asphyxiating thoracic dystrophy and short-rib polydactyly type III (Verma-Naumoff) are variants of the same disorder. *Am J Med Genet* 2000;90:310–4.
37. Elçioglu NH, Hall CM. Diagnostic dilemmas in the short rib-polydactyly syndrome group. *Am J Med Genet* 2002;111: 392–400.
38. Dagoneau N, Goulet M, Geneviève D, et al. DYNC2H1 mutations cause asphyxiating thoracic dystrophy and short rib-polydactyly syndrome, type III. *Am J Hum Genet* 2009;84: 706–11.
39. Merrill AE, Merriman B, Farrington-Rock C, et al. Ciliary abnormalities due to defects in the retrograde transport protein DYNC2H1 in short-rib polydactyly syndrome. *Am J Hum Genet* 2009;84:542–9.
40. Beales PL, Bland E, Tobin JL, et al. *IFT80*, which encodes a conserved intraflagellar transport protein, is mutated in Jeune asphyxiating thoracic dystrophy. *Nat Genet* 2007;39:727–9.
41. Slavotinek AM, Stone EM, Mykytyn K, et al. Mutations in MKKS cause Bardet-Biedl syndrome. *Nat Genet* 2000;26:15–6.
42. Stone DL, Slavotinek A, Bouffard GG, Banerjee-Basu S, Baxevanis AD, Barr M, Biesecker LG. Mutation of a gene encoding a putative chaperonin causes McKusick-Kaufman syndrome. *Nat Genet* 2000;26:79–82.