

# DETECTION AND COMPARISON OF CYTOMEGALOVIRUS DNA LEVELS IN AMNIOTIC FLUID AND FETAL ASCITES IN A SECOND-TRIMESTER FETUS WITH MASSIVE ASCITES, HYPERECHOGENIC BOWEL, VENTRICULOMEGALY AND INTRAUTERINE GROWTH RESTRICTION

Chih-Ping Chen<sup>1,2,3,4,5,6\*</sup>, Yi-Ning Su<sup>7</sup>, Schu-Rern Chern<sup>2</sup>, Tao-Yeuan Wang<sup>8</sup>,  
Fuu-Jen Tsai<sup>4,9,10</sup>, Hung-Hung Lin<sup>1</sup>, Pei-Chen Wu<sup>1</sup>, Wayseen Wang<sup>2,11</sup>

*Departments of*<sup>1</sup>*Obstetrics and Gynecology and*<sup>2</sup>*Medical Research, Mackay Memorial Hospital, Taipei,*<sup>3</sup>*Department of Biotechnology, Asia University,*<sup>4</sup>*School of Chinese Medicine, College of Chinese Medicine, China Medical University, Taichung,*<sup>5</sup>*Institute of Clinical and Community Health Nursing, National Yang-Ming University,*<sup>6</sup>*Department of Obstetrics and Gynecology, School of Medicine, National Yang-Ming University,*<sup>7</sup>*Department of Medical Genetics, National Taiwan University Hospital, Taipei,*<sup>8</sup>*Department of Pathology, Mackay Memorial Hospital, Taipei, Departments of*<sup>9</sup>*Medical Genetics and*<sup>10</sup>*Medical Research, China Medical University Hospital, Taichung, and*<sup>11</sup>*Department of Bioengineering, Tatung University, Taipei, Taiwan.*

## SUMMARY

**Objective:** To present a prenatal diagnosis of congenital cytomegalovirus (CMV) infection in a pregnancy with fetal ascites.

**Case Report:** A 33-year-old, gravida 6, para 2, woman was referred to a hospital at 20 weeks of gestation for management of fetal ascites. The woman had not experienced recent rubella or herpes simplex infections. The maternal blood group was O and Rh(D)-positive. The maternal serum thalassemia and syphilis screen results were negative. Fetal ascites was first noted at 17 weeks of gestation. At 18 weeks, she underwent amniocentesis revealing a 46,XX karyotype. At 20 weeks of gestation, maternal serum CMV IgG and CMV IgM were positive. At 21 gestational weeks, prenatal ultrasound showed fetal ascites, hyperechoic bowel, ventriculomegaly, and intrauterine growth restriction. Repeated amniocentesis showed CMV DNA levels of  $9.72 \times 10^5$  copies/mL and  $6.03 \times 10^5$  copies/mL in amniocytes and amniotic fluid supernatant, respectively. Paracentesis showed CMV DNA levels of  $1.64 \times 10^3$  copies/mL and 114 copies/mL in ascitic cells and ascitic supernatant, respectively. The pregnancy was terminated. Postnatally, CMV DNA was detected in the umbilical cord, amnion, placenta, cord blood, lungs, liver and brain by quantitative real-time polymerase chain reaction.

**Conclusion:** A prenatal diagnosis of fetal ascites in association with ventriculomegaly, hyperechoic bowel and intrauterine growth restriction should alert physicians to congenital CMV infection in addition to aneuploidy. The present case provides evidence that CMV DNA levels are higher in amniotic fluid (amniocytes and amniotic fluid supernatant) than in ascites (ascitic cells and ascitic supernatant) in cases of congenital CMV infection. [*Taiwan J Obstet Gynecol* 2010;49(2):206–210]

**Key Words:** congenital infection, cytomegalovirus, DNA, fetal ascites, prenatal diagnosis



ELSEVIER

\*Correspondence to: Dr Chih-Ping Chen, Department of Obstetrics and Gynecology, Mackay Memorial Hospital, 92, Section 2, Chung-Shan North Road, Taipei, Taiwan.

E-mail: cpc\_mmh@yahoo.com

Accepted: March 18, 2010

## Introduction

Cytomegalovirus (CMV) is the most common cause of intrauterine infection in developed countries, occurring in 0.2–2% of live births [1]. CMV is transmitted by person-to-person contact via oropharyngeal secretions, urine, semen, milk, tears, blood, as well as cervical and vaginal secretions. Maternal CMV infection may hematogenously spread the virus to the fetus through the placenta courtesy of infected leukocytes [2]. Primary maternal infection of CMV has a much greater clinical impact than non-primary infection. CMV infection in adults is usually subclinical, although clinical symptoms are more often present in primary than non-primary infections. In a study to compare the clinical manifestations between primary infections and recurrent or non-active infection of CMV in adults, Nigro et al [3] observed fever in 42.1% versus 17.1%, asthenia in 31.4% versus 11.4%, myalgia in 21.5% versus 6.7%, rhinopharyngo-tracheo-bronchitis in 42.1% versus 29.5%, flu-like syndrome in 24.5% versus 9.5%, lymphocytosis in 39.2% versus 5.7% and increased aminotransferases in 35.3% versus 3.9%. In primary maternal infections, transmission to the fetus occurs in 30–40% of cases, whereas with recurrent infection or re-infection, the risk is 0.15–1% [1,4–6].

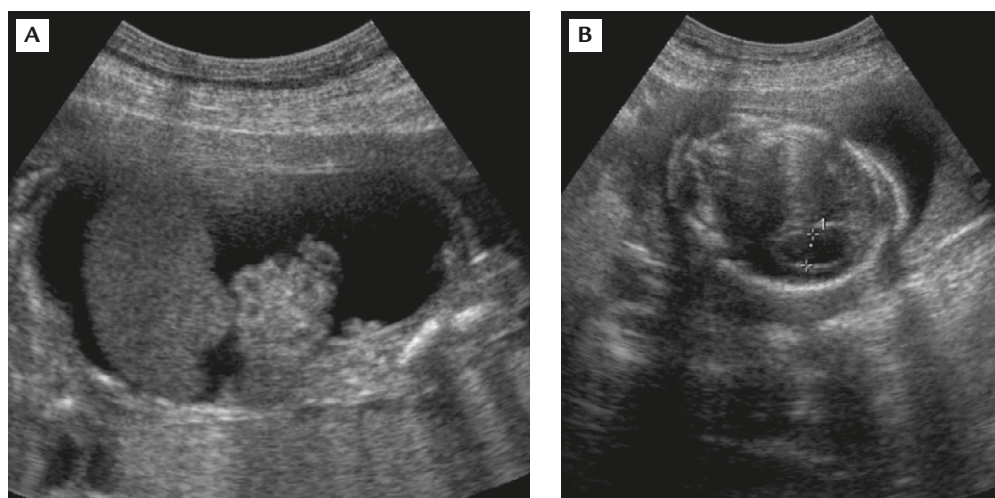
About 90% of infected fetuses are asymptomatic at birth, and 10% of the infected fetuses are symptomatic with characteristic clinical manifestations and complications such as low birth weight, jaundice, hepatosplenomegaly, microcephaly, intracranial calcification, thrombocytopenic purpura, chorioretinitis, mental and motor retardation, sensorineural deficits and hemolytic anemia, sometimes resulting in death [4,7,8]. About 10–15% of the asymptomatic infected fetuses may develop long-term sequelae such as sensorineural hearing loss, mental retardation, chorioretinitis, intellectual deficits, and microcephaly. IgG avidity assays are useful for distinguishing primary CMV from non-primary CMV infections. After primary infection, the antibody response matures from low to high avidity antibody production, and high CMV IgG avidity is a reliable indicator of past infection in pregnant women with a positive IgM response [9–15]. Recently, Lagrou et al [15] reported that the new Architect CMV IgG avidity test (Abbott Laboratories, Abbott Park, IL, USA) had excellent specificity (98%) in excluding patients with recent infections. Prenatal diagnosis of fetal ascites in association with hyperechogenic bowel, ventriculomegaly and intrauterine growth restriction (IUGR) should alert physicians to congenital CMV infection in addition to aneuploidy. Here, we present such a case.

## Case Report

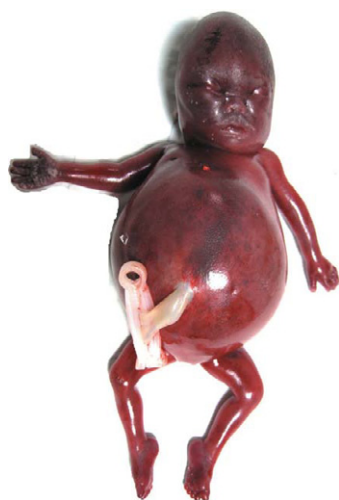A 33-year-old, gravida 6, para 2, woman was referred to a hospital at 20 gestational weeks for management of fetal ascites. The parents were non-consanguineous and healthy. The mother denied any recent rubella or herpes simplex infections but had experienced three abortions. There was no family history of congenital malformations. The maternal blood group was O and Rh(D)-positive. The maternal serum thalassemia and syphilis screen results were negative. The pregnancy was uneventful until 17 gestational weeks when fetal ascites was noted by routine ultrasonographic examination. She underwent amniocentesis at 18 gestational weeks because of fetal ascites. The karyotype was 46,XX. Maternal serum toxoplasmosis IgG and IgM were negative, and maternal serum CMV IgG and CMV IgM were positive at 20 gestational weeks. The CMV IgG level was 904.8 AU/mL (normal, <15 AU/mL) and CMV IgM level was 0.56 (normal, <0.4). The IgG avidity assay revealed low CMV IgG avidity, indicative of primary CMV infection. Level II ultrasound examination at 21 gestational weeks revealed fetal ascites, hyperechogenic bowel, ventriculomegaly and IUGR (Figure 1). The amniotic fluid index was normal. Repeat amniocentesis and paracentesis were performed at 21 gestational weeks. CMV DNA was detected in the samples of ascites and amniotic fluid by quantitative real-time polymerase chain reaction (qRT-PCR) [16]. A comparison of the CMV DNA levels among amniocytes, amniotic fluid supernatant, ascitic cells and ascitic supernatant by qRT-PCR showed that amniocytes contained the highest levels of CMV DNA ( $9.72 \times 10^5$  copies/mL) followed by the levels in the amniotic fluid supernatant ( $6.03 \times 10^5$  copies/mL), ascitic cells ( $1.64 \times 10^3$  copies/mL) and ascitic supernatant (114 copies/mL). There was a negative molecular diagnosis for parvovirus B19, rubella, herpes simplex, and toxoplasmosis. The parents opted to terminate the pregnancy. At 22 weeks of gestation, a 526-g female fetus was delivered with a distended abdomen and massive ascites (Figure 2). CMV DNA was detected in the umbilical cord, amnion, placenta, cord blood, lungs, liver and brain by qRT-PCR (Figure 3).

## Discussion

The present case was associated with fetal ascites, ventriculomegaly, hyperechogenic bowel and IUGR by prenatal ultrasound. In a meta-analysis of ultrasound abnormalities in 277 pregnancies with congenital CMV infection, Benoist and Ville [17] found that the common



**Figure 1.** Prenatal ultrasound at 21 weeks of gestation showing (A) fetal ascites with hyperechogenic bowel and (B) ventriculomegaly.

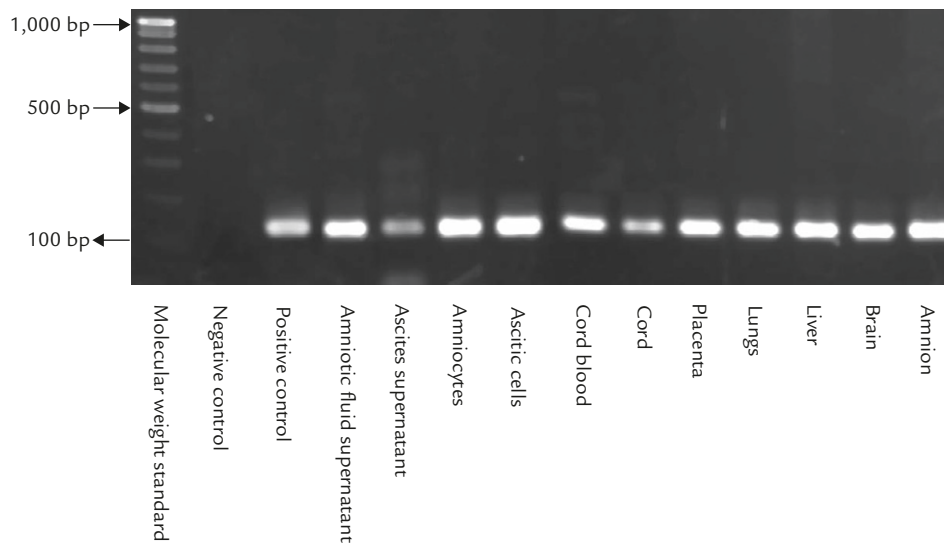


**Figure 2.** The fetus at birth.

ultrasound abnormalities were IUGR (16.2%), brain structural abnormalities (13%), hyperechogenic bowel (13%), ventriculomegaly (12.6%), microcephaly (9%), ascites (7.2%), oligohydramnios/anhydramnios (5.4%), hydrocephalus (4.7%), hydrops fetalis (2.9%), placentomegaly (1.8%), polyhydramnios (1.4%), pericardial effusion (1.4%), and pleural effusion, skin edema and liver calcifications (< 1%). The overall detection rate of ultrasound abnormalities in pregnancies with congenital CMV infection was 41.9% (116 of 277) as compiled from previously published data [5,18–23].

Chen et al [24] previously reported detection of CMV DNA in fetal ascites in a fetus at 21 weeks of gestation. Fetal ascites can be an alternative source for prenatal diagnosis of CMV infection, especially when severe oligohydramnios or anhydramnios is present. This report shows that CMV DNA levels are higher in

amniotic fluid (amniocytes and amniotic fluid supernatant) compared with ascites (ascitic cells and ascitic supernatant), suggesting that amniotic fluid is more useful than ascites in the prenatal diagnosis of fetal CMV infection. Liesnard et al [5] reported a global sensitivity for prenatal diagnosis of 80% and a specificity of 100% in CMV DNA testing on amniotic fluid after 21 gestational weeks, and a 7-week interval between diagnosis of maternal infection and amniocentesis. However, Donner et al [25] reported 45.4% sensitivity for CMV DNA testing on amniotic fluid before 21 gestational weeks. Amniocentesis performed too soon after the diagnosis of maternal CMV infection and a low copy number of virus in the amniotic fluid are responsible for the lack of sensitivity of CMV DNA testing in amniotic fluid before 21 weeks of gestation [25]. The renal tubular epithelium is a major site of CMV replication. The infected fetus excretes CMV in the urine, and CMV DNA is accumulated in the amniotic fluid. It takes around 6–8 weeks from maternal seroconversion or reactivation to excrete CMV in fetal urine [25,26]. Therefore, the CMV DNA level in amniotic fluid samples correlates with the gestational age at the time of amniocentesis [21]. The present case provides evidence that CMV DNA levels are higher in amniocytes than in amniotic fluid supernatant and higher in ascitic cells than in ascitic supernatant, suggesting that amniocytes and ascitic cells may be useful for CMV DNA testing in addition to cytogenetic analysis in the case of fetal ascites. Prenatal diagnosis of ventriculomegaly, hyperechogenic bowel, fetal ascites and IUGR may lead obstetricians to suspect fetal chromosomal abnormalities. A normal karyotype, such as that seen in this case, should alert physicians to congenital CMV infection.



**Figure 3.** Polymerase chain reaction products of cytomegalovirus in fetal and extraembryonic tissues subjected to electrophoresis on a 2% agarose gel. Lane 1: molecular weight standard; lane 2: negative control; lane 3: positive control; lanes 4–14: amplicons using DNA extracted from amniotic fluid supernatant, ascitic supernatant, amniocytes, ascitic cells, cord blood, cord, placenta, lungs, liver, brain and amnion, respectively.

## Acknowledgments

This work was supported by research grants NSC-96-2314-B-195-008-MY3 and NSC-97-2314-B-195-006-MY3 from the National Science Council, and MMH-E-99004 from Mackay Memorial Hospital, Taipei, Taiwan.

## References

1. Stagno S, Pass RF, Cloud G, Britt WJ, Henderson RE, Walton PD. Primary cytomegalovirus infection in pregnancy: incidence, transmission to fetus, and clinical outcome. *JAMA* 1986;256:1904–84.
2. Grose C, Weiner CP. Prenatal diagnosis of congenital cytomegalovirus infection: two decades later. *Am J Obstet Gynecol* 1990;163:447–50.
3. Nigro G, Anceschi MM, Cosmi EV. Clinical manifestations and abnormal laboratory findings in pregnant women with primary cytomegalovirus infection. *Br J Obstet Gynecol* 2003; 110:572–7.
4. Fowler KB, Stagno S, Pass RF, Britt WJ, Boll TJ, Alford CA. The outcome of congenital cytomegalovirus in relation to maternal antibody status. *N Engl J Med* 1992;326:663–7.
5. Liesnard C, Donner C, Brancart F, Gosselin F, Delforge ML, Rodesch F. Prenatal diagnosis of congenital cytomegalovirus infection: prospective study of 237 pregnancies at risk. *Obstet Gynecol* 2000;95:881–8.
6. Ross SA, Boppana SB. Congenital cytomegalovirus infection: outcome and diagnosis. *Semin Pediatr Infect Dis* 2004;16:44–9.
7. Boppana SB, Pass RF, Britt WS, Stagno S, Alford CA. Symptomatic congenital cytomegalovirus infection: neonatal morbidity and mortality. *Pediatr Infect Dis J* 1992;11:93–9.
8. Cheeran MC, Lokensgard JR, Schleiss MR. Neuropathogenesis of congenital cytomegalovirus infection: disease mechanisms and prospects for intervention. *Clin Microbiol Rev* 2009;22:99–126.
9. Grangeot-Keros L, Mayaux MJ, Lebon P, Freymuth F, Eugene G, Stricker R, Dussaix E. Value of cytomegalovirus (CMV) IgG avidity index for the diagnosis of primary CMV infection in pregnant women. *J Infect Dis* 1997;175:944–6.
10. Lazzarotto T, Spezzacatena P, Pradelli P, Abate DA, Varani S, Landini MP. Avidity of immunoglobulin G directed against human cytomegalovirus during primary and secondary infections in immunocompetent and immunocompromised subjects. *Clin Diagn Lab Immunol* 1997;4:469–73.
11. Bodeus M, Feyder S, Goubau P. Avidity of IgG antibodies distinguishes primary from non-primary cytomegalovirus infection in pregnant women. *Clin Diagn Virol* 1998;9:9–16.
12. Macé M, Sissoeff L, Rudent A, Grangeot-Keros L. A serological testing algorithm for the diagnosis of primary CMV infection in pregnant women. *Prenat Diagn* 2004;24:861–3.
13. Munro SC, Hall B, Whybin LR, Leader L, Robertson P, Maine GT, Rawlinson WD. Diagnosis of and screening for cytomegalovirus infection in pregnant women. *J Clin Microbiol* 2005; 43:4713–8.
14. Kanengisser-Pines B, Hazan Y, Pines G, Appelman Z. High cytomegalovirus IgG avidity is a reliable indicator of past infection in patients with positive IgM detected during the first trimester of pregnancy. *J Perinat Med* 2009;37:15–8.
15. Lagrou K, Bodeus M, Van Ranst M, Goubau P. Evaluation of the new architect cytomegalovirus immunoglobulin M (IgM), IgG, and IgG avidity assays. *J Clin Microbiol* 2009;47: 1695–9.
16. Onishi Y, Mori S, Higuchi A, et al. Early detection of plasma cytomegalovirus DNA by real-time PCR after allogeneic hematopoietic stem cell transplantation. *Tohoku J Exp Med* 2006;210:125–35.
17. Benoist G, Ville Y. Fetal infection. In: Rodeck CH, Whittle MJ, eds. *Fetal Medicine: Basic Science and Clinical Practice*, 2<sup>nd</sup> Edition. New York: Churchill Livingstone, Elsevier, 2009: 620–41.

18. Azam AZ, Vial Y, Fawer CL, Zufferey J, Hohlfeld P. Prenatal diagnosis of congenital cytomegalovirus infection. *Obstet Gynecol* 2001;97:443-8.
19. Lipitz S, Achiron R, Zalel Y, Mendelson E, Tepperberg M, Gamzu R. Outcome of pregnancies with vertical transmission of primary cytomegalovirus infection. *Obstet Gynecol* 2002;100:428-33.
20. Guerra B, Lazzarotto T, Quarta S, Lanari M, Bovicelli L, Nicolosi A, Landini MP. Prenatal diagnosis of symptomatic congenital cytomegalovirus infection. *Am J Obstet Gynecol* 2000;183:476-82.
21. Gouarin S, Gault E, Vabret A, et al. Real-time PCR quantification of human cytomegalovirus DNA in amniotic fluid samples from mothers with primary infection. *J Clin Microbiol* 2002;40:1767-72.
22. Picone O, Costa JM, Leruez-Ville M, Ernault P, Olivi M, Ville Y. Cytomegalovirus (CMV) glycoprotein B genotype and CMV DNA load in the amniotic fluid of infected fetuses. *Prenat Diagn* 2004;24:1001-6.
23. Enders G, Bäder U, Lindemann L, Schalasta G, Daiminger A. Prenatal diagnosis of congenital cytomegalovirus infection in 189 pregnancies with known outcome. *Prenat Diagn* 2001;21:362-77.
24. Chen CP, Chern SR, Chuang CY, Chen BF. Prenatal detection of human cytomegalovirus DNA in fetal ascites by the polymerase chain reaction. *Acta Obstet Gynecol Scand* 1998;77:466-7.
25. Donner C, Liesnard C, Brancart F, Rodesch F. Accuracy of amniotic fluid testing before 21 weeks' gestation in prenatal diagnosis of congenital cytomegalovirus infection. *Prenat Diagn* 1994;14:1055-9.
26. Revello MG, Gerna G. Diagnosis and management of human cytomegalovirus infection in the mother, fetus, and newborn infant. *Clin Microbiol Rev* 2002;15:680-715.