

Protein Kinase C Alpha Location and the Expression of Phospho-MEK and MDR1 in Hepatitis Virus-Related Hepatocellular Carcinoma Biopsies

Chien-Chung Lin^{1,2}, Jin-Ming Hwang³, Min-Ting Tsai⁴, Wei-Wen Su⁴,
Li-Mien Chen⁵, Tung-Yuan Lai⁶, Hsi-Hsien Hsu⁷, Shio-Kang Yen^{1,*},
Chih-Yang Huang^{8,9,10,*}, and Jer-Yuh Liu^{11,12,*}

¹*Department of Materials and Science and Engineering, National Chung Hsing University, Taichung*

²*Orthopaedic Department, Armed Forces General Hospital, Taichung*

³*School of Applied Chemistry, Chung-Shan Medical University, Taichung*

⁴*Division of Hepatogastroenterology, Department of Internal Medicine
Changhua Christian Hospital, Changhua*

⁵*Departments of Internal Medicine, Armed Force Taichung General Hospital, Taichung*

⁶*School of Post-Baccalaureate Chinese Medicine, China Medical University, Taichung*

⁷*Division of Colorectal Surgery, Mackay Memorial Hospital, Taipei*

⁸*Graduate Institute of Chinese Medical Science, China Medical University, Taichung*

⁹*Graduate Institute of Basic Medical Science, China Medical University, Taichung*

¹⁰*Department of Health and Nutrition Biotechnology, Asia University, Taichung*

¹¹*Center for Molecular Medicine, China Medical University Hospital, Taichung
and*

¹²*Graduate Institute of Cancer Biology, China Medical University, Taichung
Taiwan, Republic of China*

Abstract

The purpose of this study was to elucidate the function of protein kinase C (PKC) α in human hepatocellular carcinoma (HCC). Histoimmunopathologic techniques were used to determine the localization and/or expression of PKC α , phospho-mitogen-activated protein kinase (MEK) and multidrug resistance 1 (MDR1) in HCC biopsies. Expression of PKC α , phospho-MEK and MDR1 was significantly increased in the region of HCC location compared with the non-tumor location. The HCC tissues were classified as cytosolic type, where PKC α was deposited in the cytoplasm in > 50% of cells, or membranous type for others. The results showed that the higher expression levels of phospho-MEK and MDR1 in HCC location were significantly associated with those patients whose cells were of the membranous type. Moreover, the expression of MDR1 in HCC location was also significantly associated with the phospho-MEK, and was significantly higher in the patients with anti-HCV negative readings. The results indicate that elevated expression of MDR1 in HCC patients with non-HCV infection may be mediated through PKC signaling pathway.

Key Words: hepatitis C virus, hepatocellular carcinoma, MDR1, phospho-MEK, protein kinase C alpha

Corresponding author: Jer-Yuh Liu, Ph.D., Graduate Institute of Cancer Biology, College of Medical, China Medical University, No. 6, Hsueh-Shih Road, Taichung 404, Taiwan, R.O.C. Tel: +886-4-22052121 ext. 7801, Fax: +886-4-22347028, E-mail: jyl@mail.cmu.edu.tw.

*These authors contributed equally to this paper.

Received: April 15, 2009; Revised (Final Version): July 17, 2009; Accepted: August 5, 2009.

©2010 by The Chinese Physiological Society. ISSN : 0304-4920. <http://www.cps.org.tw>

Introducion

Chronic hepatitis due to hepatitis B virus (HBV) and/or hepatitis C virus (HCV) is a well-documented major risk factor of hepatocellular carcinoma (HCC) (16). HBV is a partially double-stranded DNA virus with a circular genome of 3.2 kb encoding two structural proteins (core protein and surface protein) and two nonstructural proteins (hepatitis B virus X protein, HBx, and polymerase) involved in viral replication (18). HBx may activate pathways associated with activator protein-1 (AP-1), activator protein-2 (AP-2), nuclear factor-kappa B (NF- κ B) and serum response element (SRE) (2). HCV is an RNA virus with a genome size of about 10 kb encoding a number of structural (core, E1, E2, and p7) and nonstructural (NS2, NS3, NS4A, NS4B, and NS5B) proteins (9, 14). The HCV core protein has the strongest influence on NF- κ B-, AP-1- and SRE-associated pathways (24). Activation of these signaling pathways by HBx or HCV core proteins has been reported to play an important role in the progression of liver injury, cirrhosis and HCC (3, 13, 14, 28, 39).

HBx uses a complex signal transduction pathway for transactivation in carcinogenesis. An increase in the endogenous protein kinase C (PKC) activator sn-1,2-diacylglycerol and the subsequent activation of PKC gives rise to the activation of the transcription factor AP-1 (Jun-Fos) (25). HBx activates PKC differently from the ras oncogene product or phorbol ester in that it does not lead to rapid down-regulation of the enzyme subsequent to the activation (30). Since HBx is more active than the hepatitis B virus surface antigen (HBsAg) in HCC (12, 38), it may be an important factor for PKC activation in the progressive malignancy of HCC. Moreover, nonstructural protein 3 (NS3) of HCV may inhibit the TPA-induced redistribution of PKC α or PKC β (4). These findings suggest that PKC plays an important role in hepatocarcinogenesis.

PKC is a lipid-regulated and calcium-dependent protein kinase that plays an important role in the control of cell growth and differentiation (33). PKC has 10 isoforms with different distribution patterns, structures and functions in various tissues (31, 32). Although elevation in PKC activity has been demonstrated in breast tumors (34), pituitary tumors (1) and malignant gliomas (11), reduction of PKC activity has also been determined in colonic carcinoma (26, 27) and HCC (6). We have found that alterations in individual PKC isoforms may play significant roles in the pathogenesis of HCC (40).

Multidrug resistance 1 (MDR1) is at the downstream of PKC. Overexpression of the MDR1 gene has been demonstrated in primary liver tumors and in some preneoplastic lesions (8, 40). In HepG2 clones

with HBx gene transfection, HBx may transactivate the expression of the endogenous MDR1 gene (15). Although MDR1 transcription is regulated by PKC α and PKC θ in human breast carcinoma cells (19), PKC α , but not PKC β I, PKC β II or PKC γ , may play a role in multidrug resistance of gastric cancer cells SGC7901/VCR (20).

A previous study has found a significant association between the membranous-located PKC α and non-HCV infection in patients with HCC (43). To determine the role of PKC α in HCC, we further employed histoimmunopathologic techniques to investigate alteration of PKC α location and expression levels of phospho-MEK (mitogen-activated protein kinase) and MDR1 in hepatitis virus-related hepatocellular carcinoma biopsies. The expression levels of phospho-MEK and MDR1 became significantly higher in the specimens with membranous-located PKC α than in those with PKC α dispersed in the cytoplasm. These findings demonstrate the role of PKC α activation in hepatocarcinogenesis.

Materials and Methods

Materials

Antibodies against MDR1 were purchased from Zymed Laboratories Inc. (San Francisco, CA, USA) and those against phospho-MEK from Transduction Laboratories (Lexington, KY, USA). The polyclonal PKC α antibody was obtained from rabbits since day 42 after immunization as described in a previous study (41).

Specimen Collection

Liver biopsies were obtained from 19 patients in the Division of Hepatogastroenterology, Department of Internal Medicine, Changhua Christian Hospital. These patients were suspected to have a tumor in the liver based on clinical history, physical examination, the presence of α -fetoprotein and ultrasonography. An informed consent was obtained from each patient before the liver puncture. After collection, the specimens were immediately fixed in 4% formalin. Histopathological grading was then determined according to cell differentiation as well, moderately or poorly differentiated. The remaining portion of each specimen was employed for analysis of tumor markers by immunohistochemistry. In addition, HBs-Ag and anti-HCV were also detected. The tumor size was measured by ultrasonography, and TNM staging was determined by histopathology, ultrasonography, computerized axial tomography and angiography.

Immunohistochemistry

Formalin-fixed specimens were dehydrated through graded alcohol and were embedded in paraffin. Sections (3 μ m) were prepared from the paraffin-embedded specimens and then deparaffinized in xylene and rehydrated through an alcohol series. The sections were then incubated with 3% H₂O₂ for 5 min. After washing with phosphate buffer saline (PBS), the sections were heat to boiling in EDTA solution (1 mM EDTA, 0.1% NP-40; pH 8.0) for 5 min for PKC α and MDR1 detection, or in citric acid solution (10 mM citric acid monohydrate; pH 6.0) for 15 min for phospho-MEK detection, in a microwave oven. This non-competitive inhibition procedure was repeated once after an interruption of 10 min.

After cooling for 20 min, the sections were washed three times in PBS for 5 min and then incubated in PBS with 3% normal bovine serum for 25 min. The sections were washed with PBS and incubated with purified polyclonal antibodies to PKC α (10 ng/ml PBS plus 0.2% BSA), phospho-MEK (1:50) and MDR1 (1:100) at room temperature for 1 h. After washing three times in PBS for 5 min, the sections were incubated with biotinylate-labeled goat anti-rabbit IgG (Sigma) at room temperature for 30 min. The sections were then washed with PBS and incubated with ABC reagent (Avidin/Biotin kit, Vector Laboratories, Inc., Burlingame, CA, USA) conjugated with peroxidase at room temperature for 30 min. PKC α antigen staining was visualized by adding 3,3'-diaminobenzidine substrate (Sigma). The reaction was terminated by rinsing the sections in distilled water.

The sections were counterstained with Gill's hematoxylin V (Mute pure Chemicals Ltd., Tokyo, Japan), dehydrated through graded alcohol, and cleared with xylene before mounting with Malinol (Mute Pure Chemicals Ltd., Tokyo, Japan). Immunoreactivity of phospho-MEK and MDR1 in the sections was examined by the BX40 system microscope (Olympus, Tokyo, Japan) with a CCD DPIX Camera (Olympus, Tokyo, Japan). Images were analyzed by the Image-Pro[®] Plus software (Media Cybernetics, Silver Spring, MD, USA). The tissues were classified as cytosolic type for those with PKC α deposited in the cytoplasm in more than 50% of the cells and the remaining ones were defined as membranous type.

Statistical Analysis

Levels of PKC α , phospho-MEK, and MDR1 were represented by the percentages of the measurements to the average of the adjacent non-cancerous (control) in the biopsies and expressed as means \pm

standard error. Categorical variables were analyzed by the Fisher exact test and continuous variables by the Mann-Whitney U test. $P < 0.05$ was considered to be statistically significant.

Results

Clinical Characteristics

The 19 patients, as described in the previous study (43), included 18 males and 1 female and aged from 33 to 81 years (61.7 ± 3.0 years). 7 patients had HBsAg alone, 8 had anti-HCV alone, and 1 had both HBsAg and Anti-HCV. Only 2 patient was negative for HBsAg and anti-HCV. TNM staging identified 1 T1, 4 T2, 9 T3, and 5 T4 lesions. The tumor size was 6.7 ± 1.3 cm. Histopathologic analysis of the tumors revealed 7 with well differentiated cells, 10 with moderately differentiated cells, and 2 with poorly differentiated cells.

Immunohistological Findings

Fig. 1 shows the membranous (Fig. 1A) and cytosolic (Fig. 1B) locations of PKC α in HCC and the expression of phospho-MEK (Fig. 1, C and D) and MDR1 (Fig. 1, E and F) in the corresponding locations. In the specimens with PKC α on the membrane, the staining intensities of phospho-MEK (Fig. 1C) and MDR1 (Fig. 1E) were strong and homogeneous. However, the intensities were relatively low in specimens with cytosolic located PKC α (Fig. 1, D and E).

PKC α Location and Expression of Phospho-MEK and MDR1

Significantly higher levels of phospho-MEK and MDR1 expression were found in membranous type than those in cytosolic type ($P < 0.05$) (Table 1).

Clinical Characteristics and Expression of Phospho-MEK and MDR1

The expression of MDR1 was significantly higher in the patients with anti-HCV negative or T3 and T4 staging ($P < 0.05$). However, no significant associations was found between phospho-MEK and the clinical characteristics ($P > 0.05$) (Table 2).

Discussion

From our previous studies, we have found that the activity of the membrane-bound PKC is significantly decreased in cancerous human liver tissues compared with that of the adjacent normal tissues whereas no significant difference in the activity was

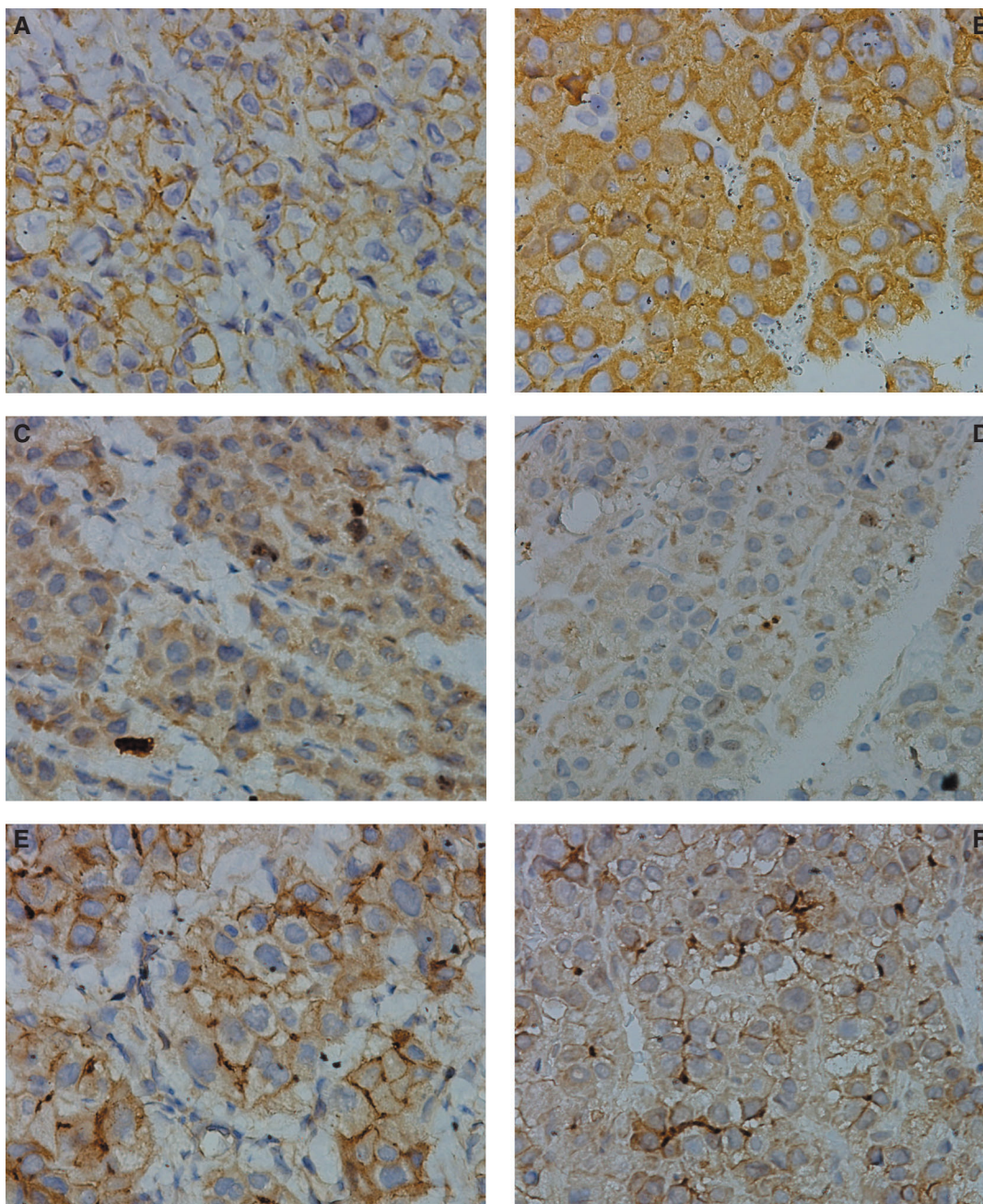


Fig. 1. Immunohistochemical analyses of protein kinase C alpha (PKC α) (A and B), phospho-MEK (C and D), and MDR1 (E and F) in the cancerous hepatic tissue of two patients with hepatocellular carcinoma (magnification, $\times 400$). Specimens of membranous type are shown in A, C and E (patient no. 15) and those of cytosolic type in B, D, and F (patient no. 2).

observed in the cytosolic fractions (6). Using Western blotting, we also determined that the level of membrane-bound PKC α in HCC tissues was significantly lower than that in the adjacent normal tissues (40). In Hep3B cells, we observed that PKC activity increases as an expression of increased proliferation of the cells in response to PMA at a low concentration (10 nM). Using immunocytochemistry, it has been observed that the activation of PKC by PMA takes the form of the translocation of PKC

isoforms from cytosol to membrane or the nucleus (23). It has been reported that PKC is a target for general anesthetic action (37). Moreover, halothane may also induce down-regulation in membrane-associated PKC activity (21). In our recent study, we used immunohistochemistry to compare PKC α expression in liver biopsies and surgical specimens from patients with HCC and demonstrated the effects of general anesthetics on the expression of PKC α (41). The inconsistent findings in our previous studies

Table 1. Expression (% of control) of phospho-MEK and MDR1 in hepatocellular carcinoma with different PKC α locations

Location of PKC α	No. of biopsies	Phospho-MEK	MDR1
Membranous	11	176.0 \pm 14.2 ^{†, ‡}	142.0 \pm 8.9 [†]
Cytosolic	8	122.7 \pm 13.2	110.5 \pm 9.6

[†]Statistical analyses were performed by the Mann-Whitney U test. $P < 0.05$ was considered significant.

[‡]Means \pm SE.

Table 2. Association between the expression levels of phospho-MEK and MDR1 and the clinical characteristics of patients with hepatocellular carcinoma

Clinical characteristic	Level [†] of phospho-MEK		P^{\ddagger}	Level [†] of MDR1		P^{\ddagger}
	high	low		high	low	
Age						
≤ 60 years	4	4	NS	4	4	NS
> 60 years	7	4		7	4	
HBs-Ag						
Positive	6	2	NS	6	2	NS
Negative	5	6		5	6	
Anti-HCV						
Positive	3	7	< 0.05	3	7	< 0.05
Negative	8	1		8	1	
TNM-staging						
T1 and T2	2	3	NS	2	3	NS
T3 and T4	9	5		9	5	
Histopathological grading						
Well differentiated	5	2	NS	5	2	NS
Moderately or poor differentiated	6	6		6	6	

[†]The expression of phospho-MEK, which was higher than the average of all patients, was designed as "high"; and which was lower than the average of all patients, was designed as "low". The designation of MDR1 was the same as the phospho-MEK.

[‡]Statistical analyses were performed by the Fisher exact test. $P < 0.05$ was considered significant. NS, not significant.

on liver cancer may be due to the effects of anesthesia on the surgical specimens. Therefore, we used liver biopsies as the materials in this study and the results agree with our findings obtained from studying Hep3B cells.

In the previous study, we have found a significant association of the membranous type with non-HCV infection and the cytosolic type with HCV infection (43). It has been reported that nuclear translocation and enzymatic activity of the catalytic subunit of PKA may be inhibited by NS3, one of the proteins produced by HCV. This viral nonstructural protein may also inhibit TPA-induced redistribution of PKC α or PKC β (4). These changes may lead to impairment in the functions of these kinases and, hence, the cytosolic type of PKC α in the specimens with positive anti-HCV.

Among the PKC isoenzymes, PKC α has been particularly identified as a determinant of expression

of the MDR phenotype. MCF-7/ADR breast carcinoma cells, with acquired resistance against adriamycin, possess elevated levels of PKC α and display the MDR phenotype (5). However, MDR1 induction in leukemia cells by TPA is completely unaffected by a MEK inhibitor. Moreover, an effective inhibitor of TPA-mediated p38 activation also fails to inhibit TPA-induced MDR1 mRNA expression. Although MDR1 induction by TPA may occur *via* a PKC-dependent mechanism, this change is independent of ERK, p38 or JNK pathways (36). In this study, we found that the expression of phospho-MEK and MDR1 was elevated in HCC biopsies with membranous-located PKC α , but there is no significant correlation between the expression of phospho-MEK and MDR1 (data not shown). These results are consistent with the findings of the research done on leukemia cells. Thus, although PKC α is considered to be involved in human hepatoma cell proliferation, migration and

invasion through the suppression of p38 MAPK signaling pathway (22, 42), the mechanism of the elevated MDR1 expression in HCC is still being discussed.

It has been reported that tamoxifen, an oral triphenylethylene anti-estrogen agent, inhibits the interaction of PKC with phospholipids leading to interference with the membrane binding of substrates to PKC (35). Moreover, this drug may act on the cytoplasmic membrane and, hence, inhibits PKC α translocation to the membrane (7). The effectiveness of this drug in the treatment of HCC has been questioned because of the inconsistent results of clinical trials in different parts of the world (29). Comparing clinical trials with different incidences of HBV and HCV infections, this drug was found to be effective in studies of specimens with a higher percentage of HBV infection (10, 17). Based on the results of this study, many of the patients with HCC of PKC α membranous type were positive for HBsAg. Moreover, in these patients, the expression of MDR1 was also found to be elevated as was the level of activation of PKC α . Whether administering tamoxifen interferes with the activation of PKC α and the expression of MDR1 in HCC is still under discussion.

Acknowledgments

This work was supported by the grants from the National Science Council, Republic of China (NSC 92-2745-B-040-001 and NSC 92-2314-13-075A-001).

References

- Alvaro, V., Touraine, P., Raisman, Vozari R., Bai-Grenier, F., Birman, P. and Joubert, D. Protein kinase C activity and expression in normal and adenomatous human pituitaries. *Int. J. Cancer* 50: 724-730, 1992.
- Andrisani, O.M. and Barnabas, S. The transcriptional function of the hepatitis B virus X protein and its role in hepatocarcinogenesis (Review). *Int. J. Oncol.* 15: 373-379, 1999.
- Baeuerle, P.A. Pro-inflammatory signaling: last pieces in the NF- κ B puzzle? *Curr. Biol.* 8: R19-R22, 1998.
- Borowski, P., Schulze zur Wiesch, J., Resch, K., Feucht, H., Laufs, R. and Schmitz, H. Protein kinase C recognizes the protein kinase A-binding motif of nonstructural protein 3 of hepatitis C virus. *J. Biol. Chem.* 274: 30722-30728, 1999.
- Budworth, J., Gant, T.W. and Gescher, A. Co-ordinate loss of protein kinase C and multidrug resistance gene expression in revertant MCF-7/Adr breast carcinoma cells. *Br. J. Cancer* 75: 1330-1335, 1997.
- Chang, K.J., Lin, J.K., Lee, P.H., Hsieh, Y.S., Cheng, C.K. and Liu, J.Y. The altered activity of membrane-bound protein kinase C in human liver cancer. *Cancer Lett.* 105: 211-215, 1996.
- Cheng, A.L., Chuang, S.E., Fine, R.L., Yeh, K.H., Liao, C.M., Lay, J.D. and Chen, D.S. Inhibition of the membrane translocation and activation of protein kinase C, and potentiation of doxorubicin-induced apoptosis of hepatocellular carcinoma cells by tamoxifen. *Biochem. Pharmacol.* 55: 523-531, 1998.
- Chenivesse, X., Franco, D. and Brechot, C. MDR1 (multidrug resistance) gene expression in human primary liver cancer and cirrhosis. *J. Hepatol.* 18: 168-172, 1993.
- Choo, Q.L., Richman, K.H., Han, J.H., Berger, K., Lee, C., Dong, C., Gallegos, C., Coit, D., Medina-Selby, A., Barr, P.J., Weiner, A.J., Bradley, D.W., Kuo, G. and Houghton, M. Genetic organization and diversity of the hepatitis C virus. *Proc. Natl. Acad. Sci. U.S.A.* 88: 2451-2455, 1991.
- CLIP Group (Cancer of the Liver Italian Programme). Tamoxifen in treatment of hepatocellular carcinoma: a randomised controlled trial. *Lancet* 352: 17-20, 1998.
- Couldwell, W.T., Antel, J.P. and Yong, V.W. Protein kinase C activity correlates with the growth rate of malignant gliomas: Part II. Effects of glioma mitogens and modulators of protein kinase C. *Neurosurgery* 31: 717-724, 1992.
- Craxi, A., Pasqua, P., Giannuoli, G., Di Stefano, R., Simonetti, R.G. and Pagliaro, L. Tissue markers of hepatitis B virus infection in hepatocellular carcinoma and cirrhosis. *Hepato-gastroenterology* 31: 55-59, 1984.
- Cressman, D.E., Greenbaum, L.E., Haber, B.A. and Taub, R. Rapid activation of post-hepatectomy factor/nuclear factor kappa B in hepatocytes, a primary response in the regenerating liver. *J. Biol. Chem.* 269: 30429-30435, 1994.
- Di Bisceglie, A.M. Hepatitis C. *Lancet* 351: 351-355, 1998.
- Doong, S.L., Lin, M.H., Tsai, M.M., Li, T.R., Chuang, S.E. and Cheng, A.L. Transactivation of the human MDR1 gene by hepatitis B virus X gene product. *J. Hepatol.* 29: 872-878, 1998.
- El-Serag, H.B. Hepatocellular carcinoma: an epidemiologic view. *J. Clin. Gastroenterol.* 35: S72-S78, 2002.
- Farinati, F., De Maria, N., Marafin, C., Herszenyi, L., Del Prato, S., Rinaldi, M., Perini, L., Cardin, R. and Naccarato, R. Unresectable hepatocellular carcinoma in cirrhosis: survival, prognostic factors, and unexpected side effects after transcatheter arterial chemoembolization. *Dig. Dis. Sci.* 41: 2332-2339, 1996.
- Ganem, D. and Varmus, H.E. The molecular biology of the hepatitis B viruses. *Annu. Rev. Biochem.* 56: 651-693, 1987.
- Gill, P.K., Gescher, A. and Gant, T.W. Regulation of MDR1 promoter activity in human breast carcinoma cells by protein kinase C isozymes alpha and theta. *Eur. J. Biochem.* 268: 4151-4157, 2001.
- Han, Y., Han, Z.Y., Zhou, X.M., Shi, R., Zheng, Y., Shi, Y.Q., Miao, J.Y., Pan, B.R. and Fan, D.M. Expression and function of classical protein kinase C isoenzymes in gastric cancer cell line and its drug-resistant sublines. *World J. Gastroenterol.* 8: 441-445, 2002.
- Hemmings, H.C., Jr. and Adamo, A.I. Effect of halothane on conventional protein kinase C translocation and down-regulation in rat cerebrocortical synaptosomes. *Br. J. Anaesth.* 78: 189-196, 1997.
- Hsieh, Y.H., Wu, T.T., Huang, C.Y., Hsieh, Y.S., Hwang, J.M. and Liu, J.Y. p38 mitogen-activated protein kinase pathway is involved in protein kinase C α -regulated invasion in human hepatocellular carcinoma cells. *Cancer Res.* 67: 4320-4327, 2007.
- Hsu, S.L., Chou, Y.H., Yin, S.C. and Liu, J.Y. Differential effects of phorbol ester on growth and protein kinase C isoenzyme regulation in human hepatoma Hep3B cells. *Biochem. J.* 333: 57-64, 1998.
- Kato, N., Yoshida, H., Ono-Nita, S.K., Kato, J., Goto, T., Otsuka, M., Lan, K., Matsushima, K., Shiratori, Y. and Omata, M. Activation of intracellular signaling by hepatitis B and C viruses: C-viral core is the most potent signal inducer. *Hepatology* 32: 405-412, 2000.
- Kekule, A.S., Lauer, U., Weiss, L., Luber, B. and Hofschneider, P.H. Hepatitis B virus transactivator HBx uses a tumour promoter signalling pathway. *Nature* 361: 742-745, 1993.
- Kopp, R., Noelke, B., Sauter, G., Schildberg, F.W., Paumgartner, G. and Pfeiffer, A. Altered protein kinase C activity in biopsies of human colonic adenomas and carcinomas. *Cancer Res.* 51:

- 205-210, 1991.
27. Kusunoki, M., Sakanoue, Y., Hatada, T., Yanagi, H., Yamamura, T. and Utsunomiya, J. Protein kinase C activity in human colonic adenoma and colorectal carcinoma. *Cancer* 69: 24-30, 1992.
 28. Lauer, U., Weiss, L., Lipp, M., Hofschneider, P.H. and Kekule, A.S. The hepatitis B virus preS2/St transactivator utilizes AP-1 and other transcription factors for transactivation. *Hepatology* 19: 23-31, 1994.
 29. Llovet, J.M. and Bruix, J. Systematic review of randomized trials for unresectable hepatocellular carcinoma: Chemoembolization improves survival. *Hepatology* 37: 429-442, 2003.
 30. Lubet, B., Lauer, U., Weiss, L., Hohne, M., Hofschneider, P.H. and Kekule, A.S. The hepatitis B virus transactivator HBx causes elevation of diacylglycerol and activation of protein kinase C. *Res. Virol.* 144: 311-321, 1993.
 31. Musashi, M., Ota, S. and Shiroshita, N. The role of protein kinase C isoforms in cell proliferation and apoptosis. *Int. J. Hematol.* 72: 12-19, 2000.
 32. Nishizuka, Y. The molecular heterogeneity of protein kinase C and its implications for cellular regulation. *Nature* 334: 661-665, 1988.
 33. Nishizuka, Y. The role of protein kinase C in cell surface signal transduction and tumour promotion. *Nature* 308: 693-698, 1984.
 34. O'Brian, C., Vogel, V.G., Singletary, S.E. and Ward, N.E. Elevated protein kinase C expression in human breast tumor biopsies relative to normal breast tissue. *Cancer Res.* 49: 3215-3217, 1989.
 35. O'Brian, C.A., Liskamp, R.M., Solomon, D.H. and Weinstein, I.B. Inhibition of protein kinase C by tamoxifen. *Cancer Res.* 45: 2462-2465, 1985.
 36. Osborn, M.T., Berry, A., Ruberu, M.S., Ning, B., Bell, L.M. and Chambers, T.C. Phorbol ester induced MDR1 expression in K562 cells occurs independently of mitogen-activated protein kinase signaling pathways. *Oncogene* 18: 5756-5764, 1999.
 37. Slater, S.J., Cox, K.J., Lombardi, J.V., Ho, C., Kelly, M.B., Rubin, E. and Stubbs, C.D. Inhibition of protein kinase C by alcohols and anaesthetics. *Nature* 364: 82-84, 1993.
 38. Su, Q., Schroder, C.H., Hofmann, W.J., Otto, G., Pichlmayr, R. and Bannasch, P. Expression of hepatitis B virus X protein in HBV-infected human livers and hepatocellular carcinomas. *Hepatology* 27: 1109-1120, 1998.
 39. Tai, D.I., Tsai, S.L., Chen, Y.M., Chuang, Y.L., Peng, C.Y., Sheen, I.S., Yeh, C.T., Chang, K.S., Huang, S.N., Kuo, G.C. and Liaw, Y.F. Activation of nuclear factor κ B in hepatitis C virus infection: implications for pathogenesis and hepatocarcinogenesis. *Hepatology* 31: 656-664, 2000.
 40. Tsai, J.H., Hsieh, Y.S., Kuo, S.J., Chen, S.T., Yu, S.Y., Huang, C.Y., Chang, A.C., Wang, Y.W., Tsai, M.T. and Liu, J.Y. Alteration in the expression of protein kinase C isoforms in human hepatocellular carcinoma. *Cancer Lett.* 161: 171-175, 2000.
 41. Tsai, J.H., Tsai, M.T., Su, W.W., Chen, Y.L., Wu, T.T., Hsieh, Y.S., Huang, C.Y., Yeh, K.T. and Liu, J.Y. Expression of protein kinase C alpha in biopsies and surgical specimens of human hepatocellular carcinoma. *Chinese J. Physiol.* 48: 139-143, 2005.
 42. Wu, T.T., Hsieh, Y.H., Hsieh, Y.S. and Liu, J.Y. Reduction of PKC α decreases cell proliferation, migration, and invasion of human malignant hepatocellular carcinoma. *J. Cell. Biochem.* 103: 9-20, 2008.
 43. Ying, T.H., Tsai, J.H., Wu, T.T., Tsai, M.T., Su, W.W., Hsieh, Y.S., and Liu, J.Y. Immunochemical localization of protein kinase C α in the biopsies of human hepatocellular carcinoma. *Chinese J. Physiol.* 51: 269-274, 2008.